

PATIENT PRESENTING CLINICAL SIGNS

Greta Marisco

History: Diabetic as of 9/27/22 - difficult to control. PU/PD and excessive appetite. 10/21/22= PZI (u40) x 4 units BID. Last BG curve: 8am 588, 10am 488, 12pm 411, 2pm 310, 4pm 354, 6pm 349. Increased to 5 units PZI, current dose.

SPECIES

Abnormal PE/Chem/CBC/UA Results: Recent fPLI (IDEXX)= 6.7 (0 - 3.5). 10/1/22 - U/A: 1.050, ph 6.5, glucose 3 +, negative ketones, urine C & S (neg).

Feline

ULTRASONOGRAPHIC EXAMINATION OF THE ABDOMEN

BREED

Urinary System

DSH

The urinary bladder, trigone, and pelvic urethra are normal in thickness and the mucosal surface is smooth. The bladder lumen is moderately distended with anechoic urine. No masses, inflammatory changes or calculi are observed. Ureteral papillae and visualized portion of the proximal urethra, visible to a depth of 2 cm, are normal.

SEX

Spayed Female

The left kidney is normal size (4.47 cm in length) with a normal shape, smooth peripheral margins, and normal internal architecture. There is mild to moderate loss of corticomedullary distinction. Several hyperechoic shadowing diverticular foci are observed. There is no evidence of pyelectasia, infarcts or hydronephrosis. Renal vasculature is normal.

AGE

10 years, 9 mos

The right kidney is normal size (4.19 cm in length); normal shape and architecture with smooth peripheral margins. There is a normal 1:3 cortex to medulla ratio with minimal loss of corticomedullary distinction. Trace pyelectasia is present. There is no evidence of nephroliths, infarcts or hydroureter. Renal vasculature is normal.

WEIGHT

13.6 lbs

Adrenal Glands

The left adrenal gland is normal size (0.38 cm width). Normal shape and glandular echogenicity. The phrenicoabdominal vein and surrounding vasculature are normal

INTERPRETED BY

The right adrenal gland is normal in size (0.40 cm width) with a normal shape and smooth peripheral contours. A few, ill-defined hyperechoic to mineralized foci are visualized. The remaining parenchyma is homogenous with normal glandular detail. Surrounding vasculature are normal.

Andrea Nicastro, DVM,
Diplomate ACVIM
(Small Animal Internal
Medicine)

Spleen

IMAGING PERFORMED BY

The spleen is normal in size (0.83 cm in width at the level of the hilus) with a normal capsular contour. There is appropriate echogenicity and echotexture. No focal lesions are observed. Splenic vasculature is normal.

Kelly Vazquez

HOSPITAL NAME

Liver

The liver is subjectively enlarged with slightly swollen peripheral contours. The parenchyma is hyperechoic relative to the spleen and diffusely homogeneous in appearance. No distinct focal lesions are observed. Vascular and biliary tracts are of normal volume with no evidence of congestion.

Westwood Reg VH

REFERRING VET

The gall bladder is of normal contours and contains some dependent echogenic debris. The wall is normal in thickness. No choleliths are observed. The cystic and common bile ducts are normal.

Dr. Hartwick

Gastrointestinal

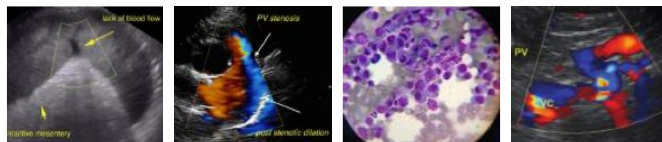
INVOICE

The stomach and intestine are free of stasis and exhibit normal peristaltic activity. The gastric lumen is not distended. The gastric wall and pylorus are normal in thickness with a normal layering pattern. The pyloric outflow tract is patent. The small intestinal lumen is not dilated. The small intestinal wall is normal to borderline thickened (up to 0.38 cm) with a normal layering pattern and appropriate mural detail. There is disruption in the normal 1:3 muscularis: mucosal ratio in some segments. Discreet masses are not identified. The colonic wall is normal. No obstructive disease is noted.

11954

DATE

11.2.22



PATIENT

Greta Marisco

SPECIES

Feline

BREED

DSH

SEX

Spayed Female

AGE

10 years, 9 mos

WEIGHT

13.6 lbs

INTERPRETED BY

Andrea Nicastro, DVM,
Diplomate ACVIM
(Small Animal Internal
Medicine)

IMAGING PERFORMED BY

Kelly Vazquez

HOSPITAL NAME

Westwood Reg VH

REFERRING VET

Dr. Hartwick

INVOICE

11954

DATE

11.2.22

Pancreas

The left limb of the pancreas is visible with normal curvilinear peripheral contours. The parenchyma is largely isoechoic relative to surrounding omental fat and slightly mottled in appearance. The pancreatic duct is visible but not overtly dilated. There is no evidence of peripancreatic inflammation or effusion.

Free Abdomen

There is no evidence of free fluid. One to two prominent mesentery lymph nodes are visualized (the largest measuring 0.98 cm in length).

ULTRASONOGRAPHIC FINDINGS

Primary Findings

- The small intestinal wall changes are suggestive of inflammatory bowel disease. There is some potential for emerging lymphoma. However, there is no obvious evidence of neoplasia at this time.
- The prominent abdominal lymph nodes are most consistent with reactive lymphadenitis or lymphoid hyperplasia. Neoplastic infiltration is considered less likely.
- The hepatic parenchymal changes could be consistent with vacuolar hepatopathy (i.e., due to diabetes mellitus), inflammatory disease (i.e., bacterial cholangiohepatitis, lymphoplasmacytic hepatitis), infiltrative neoplasia (i.e., lymphoma), other hepatopathy.

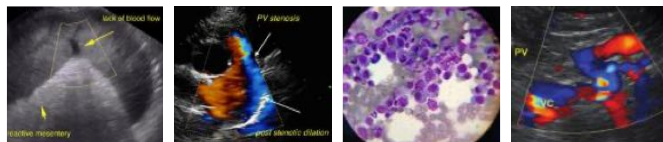
Secondary Findings

- Minor bilateral age-related renal changes with trace right pyelectasia.
- The pancreatic changes are most consistent with age-related parenchymal remodeling, potentially secondary to a prior inflammatory episode, early fibrosis or chronic pancreatitis.

INTERPRETATION OF THE FINDINGS & FURTHER RECOMMENDATIONS

Given the presence of unregulated diabetes, consider the following:

1. Three-view thoracic radiographs are recommended to assess for occult neoplasia.
2. A full GI panel including serum cobalamin and folate, TLI and PLI, is also recommended.
3. Consider a fecal evaluation for ova and Giardia.
4. Also consider a hydrolyzed protein or limited antigen diet trial (if the patient has gastrointestinal signs).
5. An IGF-1 level can also be considered if the clinical suspicion for acromegaly is high.
6. A 24-hour glucose curve, with glucoses every 2 hours, may be useful in assessing for possible Somogyi phenomenon.
7. If the above diagnostics are inconclusive, consider changing insulin types (i.e., to glargine) in case the patient has developed antibodies to the PZI insulin.



PATIENT

Greta Marisco

SPECIES

Feline

BREED

DSH

SEX

Spayed Female

AGE

10 years, 9 mos

WEIGHT

13.6 lbs

INTERPRETED BY

Andrea Nicastro, DVM,
Diplomate ACVIM
(Small Animal Internal
Medicine)

**IMAGING
PERFORMED BY**

Kelly Vazquez

HOSPITAL NAME

Westwood Reg VH

REFERRING VET

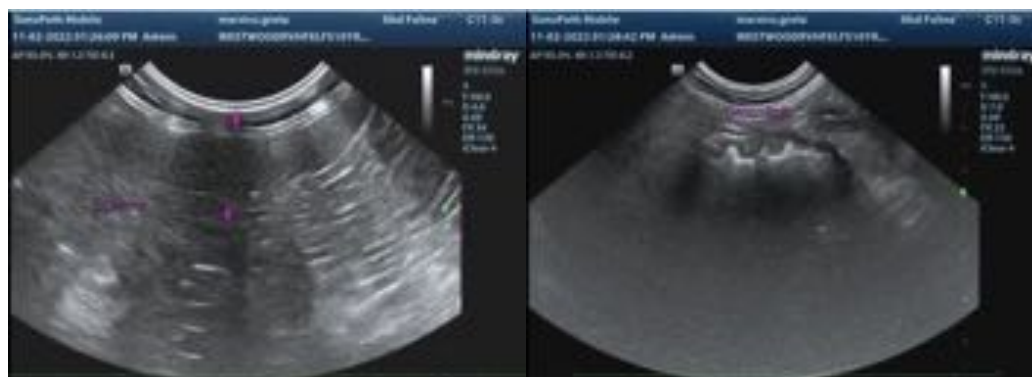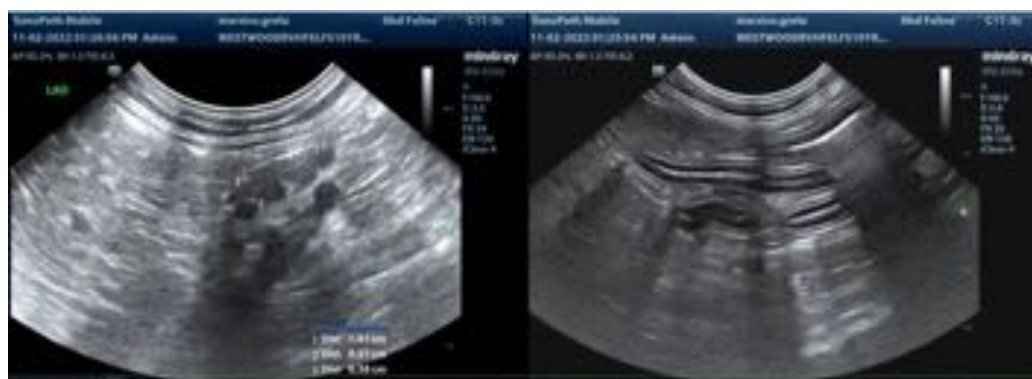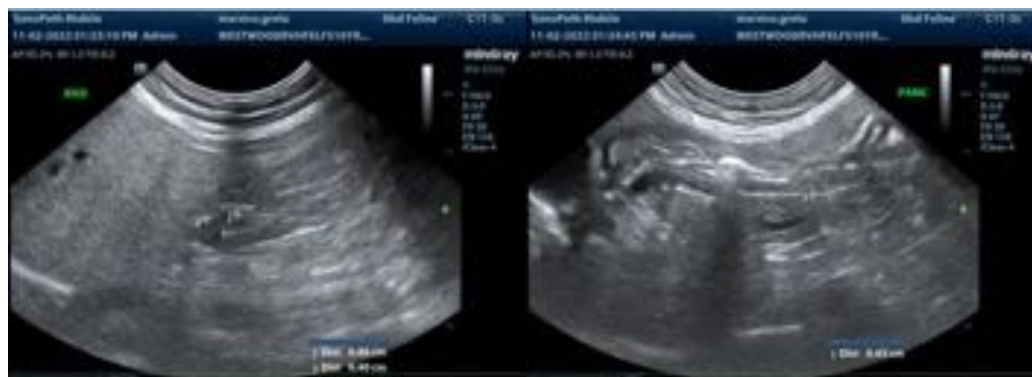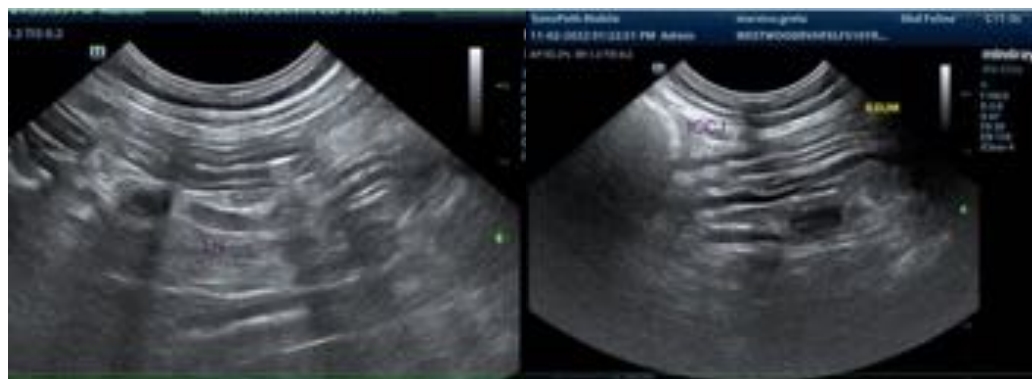Dr. Hartwick

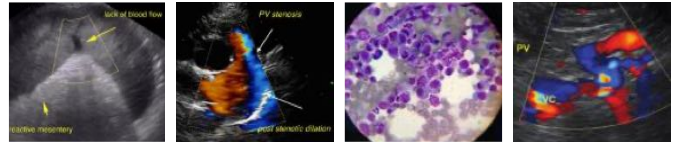
INVOICE

11954

DATE

11.2.22





PATIENT

Greta Marisco

SPECIES

Feline

BREED

DSH

SEX

Spayed Female

AGE

10 years, 9 mos

WEIGHT

13.6 lbs

INTERPRETED BY

Andrea Nicastro, DVM,
Diplomate ACVIM
(*Small Animal Internal
Medicine*)

**IMAGING
PERFORMED BY**

Kelly Vazquez

HOSPITAL NAME

Westwood Reg VH

REFERRING VET

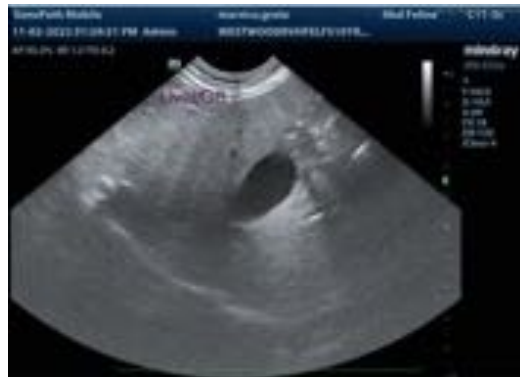Dr. Hartwick

INVOICE

11954

DATE

11.2.22



The information and recommendations provided are based on the images presented by the referring veterinarian/sonographer. No evaluation can be communicated regarding pathology that was not visible in the image/video clips provided.

Thank you for this referral. If the clinical or image interpretation does not parallel your findings or if I can be of any further assistance, please contact me.

Andrea Nicastro, DVM, Diplomate DACVIM (Small Animal Internal Medicine)
info@SonoPath.com