


PATIENT PRESENTING CLINICAL SIGNS

Cricket Cockroft
 History: Decreased appetite.
 Abnormal PE/Chem/CBC/UA Results: PSL 3,548, amylase 2,075, Mg 2.7, chol. 334, AST 77, T4 0.5. FT4 pending.

SPECIES

Canine

BREED

Corgi

SEX

Neutered Male

AGE

11 years

WEIGHT

38.6 lbs

INTERPRETED BY

Andrea Nicastro,
 DVM, Diplomate
 ACVIM (*Small Animal
 Internal Medicine*)

IMAGING PERFORMED BY

Kelly Vazquez

HOSPITAL NAME

Animal General on
 Hudson

REFERRING VET

Dr. Vivian Ng

INVOICE

11953

DATE

11.2.22

ULTRASONOGRAPHIC EXAMINATION OF THE ABDOMEN
Urinary System

The urinary bladder and visible portion of the pelvic urethra are normal for the degree of luminal distension. The urine is anechoic with no evidence of debris. Cystic calculi and discrete masses are not observed. The region of the trigone and the visible portion of the proximal urethra are normal.

The prostate is normal in size (0.63 cm in width) and shape. Parenchyma is homogenous. The prostatic urethra appears normal without evidence of dilation or obstruction.

The left kidney is normal size (5.91 cm in length); normal shape and architecture with smooth peripheral margins. There is a normal 1:3 cortex to medulla ratio with minimal to mild loss of corticomedullary distinction. A hyperechoic medullary band is observed adjacent to the corticomedullary junction. There is no evidence of pyelectasia, nephroliths, infarcts or hydroureter. Renal vasculature is normal.

The right kidney is normal size (6.23 cm in length); normal shape and architecture with smooth peripheral margins. There is a normal 1:3 cortex to medulla ratio with minimal to mild loss of corticomedullary distinction. A hyperechoic medullary band is observed adjacent to the corticomedullary junction. There is no evidence of pyelectasia, nephroliths, infarcts or hydroureter. Renal vasculature is normal.

Adrenal Glands

The right adrenal gland is mildly enlarged (0.89 cm at cranial pole) (0.81 cm at caudal pole); normal shape; homogenous parenchyma. The glandular echogenicity and detail are unremarkable. Capsule, cortex, and medullary definition are normal. The phrenicoabdominal vein and surrounding vasculature are normal.

The left adrenal gland is mildly enlarged (0.73 cm at cranial pole) (0.89 cm at caudal pole) (1.91 cm in length); normal shape; homogenous parenchyma. The glandular echogenicity and detail are unremarkable. Capsule, cortex, and medullary definition are normal. The phrenicoabdominal vein and surrounding vasculature are normal.

Spleen

The spleen is normal in size (1.49 cm in width at the level of the hilus) with a normal capsular contour. There is appropriate echogenicity and echotexture. A few, ill-defined myelolipomas are observed in the region of the hilus. Splenic vasculature is normal.

Liver

The liver is subjectively normal to slightly prominent in size with normal curvilinear peripheral contours. The parenchyma is hypoechoic relative to the spleen with minor changes consistent with age-related remodeling. A 1.81 cm irregular hyperechoic nodule is observed in the caudate process. Hepatic vasculature and intrahepatic biliary tracts are of normal volume with no evidence of congestion.

The gall bladder is moderately distended. The wall is normal in thickness. A few, polypoid-like lesions are arising from the luminal surface. Luminal contents are mostly anechoic. The cystic and common bile ducts are normal/not seen.

Gastrointestinal

The stomach and intestine are free of stasis and exhibit normal peristaltic activity. The gastric lumen is not distended. The gastric wall and pylorus are normal in thickness with a normal layering pattern. The pyloric outflow tract is patent. The small intestinal lumen is not dilated. The small intestinal wall thickness is normal with a normal layering pattern and appropriate mural detail. Discreet masses are not identified. The colonic wall is normal. No obstructive disease is noted.

Pancreas

The region of the pancreas is isoechoic relative to surrounding omental fat. No obvious parenchymal abnormalities are observed. There is no evidence of regional inflammation or effusion.

Free Abdomen

The peritoneal cavity is normal. There is no evidence of inflammation or effusion.

A 1.37 cm medial iliac lymph node is visualized. The node is normal in shape and echogenicity.

ULTRASONOGRAPHIC FINDINGS

Findings

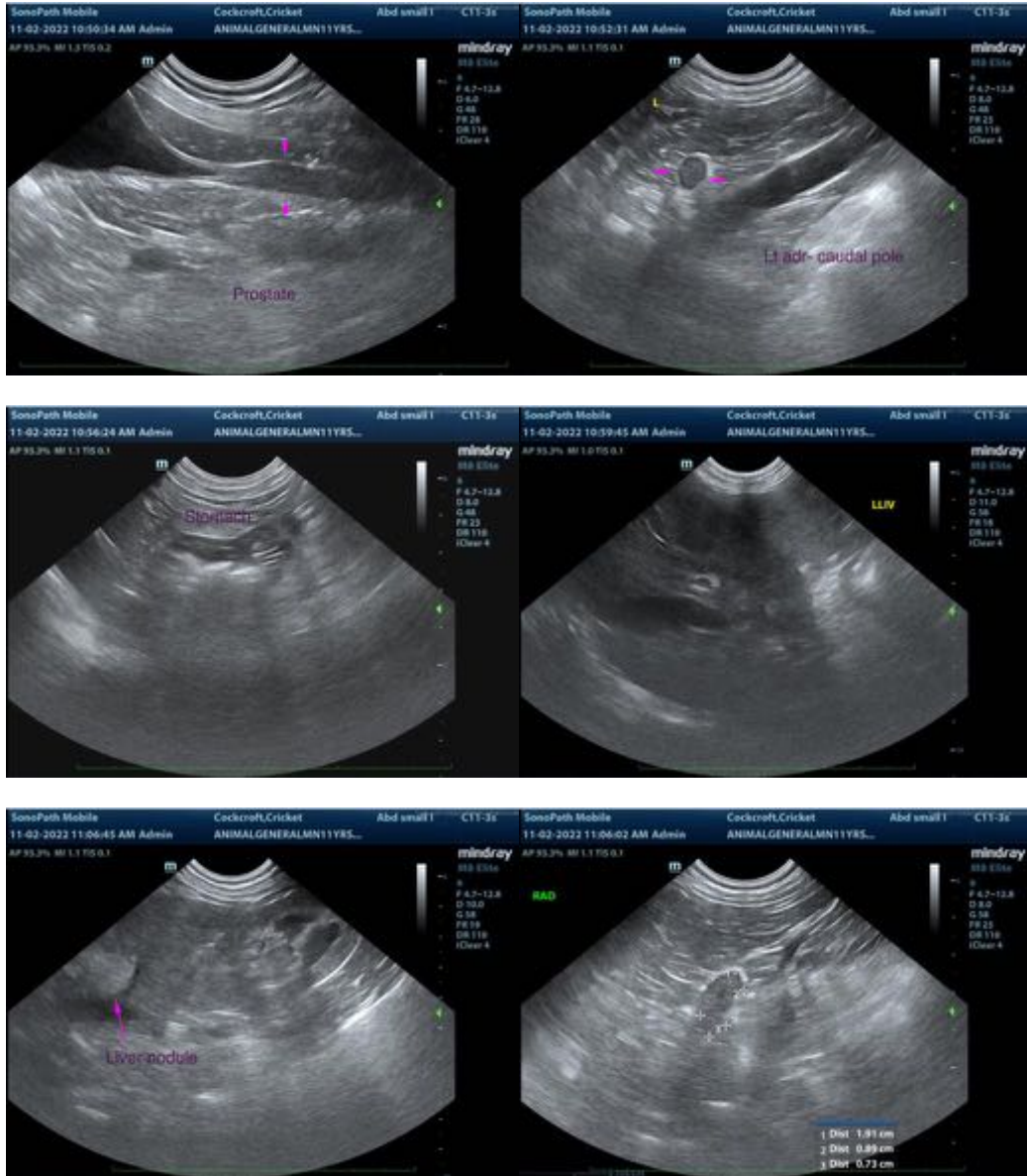
- Mild, bilateral, age-related renal changes
- The mild bilateral adrenomegaly could be consistent with hyperplastic change or may be a normal variant for this patient.
- The diffuse hepatic changes are non-specific and could be consistent with vacuolar hepatopathy, regenerative nodular hyperplasia, and/or age-related remodeling. Inflammatory and infiltrative disease are considered less likely. The hyperechoic hepatic nodule trends toward the benign (i.e., regenerative nodule) with a lower possibility of an emerging tumor.

*An obvious cause for the patient's decreased appetite is not identified in this study.

Considerations include underlying metabolic issue, primary GI disease, orthopedic or neurologic disease, occult neoplasia, other.

INTERPRETATION OF THE FINDINGS & FURTHER RECOMMENDATIONS

- Consider three-view thoracic radiographs to assess for occult disease in the chest.
- Also consider thorough orthopedic and neurologic examinations are recommended to assess for nonmetabolic causes of pain.
- A malabsorption panel, including serum cobalamin and folate, TLI and PLI, as well as a fecal evaluation for ova and Giardia. are recommended.
- Depending on the results of the above diagnostics, a more advanced GI work-up may be warranted.



The information and recommendations provided are based on the images presented by the referring veterinarian/sonographer. No evaluation can be communicated regarding pathology that was not visible in the image/video clips provided.

Thank you for this referral. If the clinical or image interpretation does not parallel your findings or if I can be of any further assistance, please contact me.

Andrea Nicastro, MPH, DVM, Diplomate DACVIM (Small Animal Internal Medicine)
info@SonoPath.com