



PATIENT

Coconut Mood

SPECIES

Canine

BREED

Bichon Frise

SEX

Intact Male

AGE

12/3/2013

WEIGHT

23.4 lbs

INTERPRETED BY

Andrea Nicastro, DVM,
Diplomate ACVIM
(Small Animal Internal
Medicine)

**IMAGING
PERFORMED BY**

Andrea Nicastro, DVM,
Diplomate ACVIM (Small
Animal Internal Medicine)

HOSPITAL NAME

Flowertown AH

REFERRING VET

Dr. Kline

INVOICE

11939

DATE

11.2.2022

PRESENTING CLINICAL SIGNS

Clinical Exam Findings: Acute onset vomiting, diarrhea and anorexia.
Abnormal lab-work values: None

ULTRASONOGRAPHIC EXAMINATION OF THE ABDOMEN

Urinary System

The urinary bladder, trigone, and pelvic urethra are normal in thickness and the mucosal surface is smooth. The bladder lumen is moderately distended with anechoic urine. No masses, inflammatory changes or calculi are observed. Ureteral papillae and visualized portion of the proximal urethra, visible to a depth of 2 cm, are normal.

The prostate is normal in size (2.98 cm in width) with smooth peripheral margins. Parenchyma is mildly hyperechoic relative to surrounding omental fat and homogenous in appearance. No focal lesions are observed. The prostatic urethra is not overtly dilated.

The left kidney is normal size (5.11 cm in length); normal shape and architecture with smooth peripheral margins. There is a normal 1:3 cortex to medulla ratio with minimal to mild loss of corticomedullary distinction. There is no evidence of pyelectasia, nephroliths, infarcts or hydronephrosis. Renal vasculature is normal.

The right kidney is normal size (5.08 cm in length); normal shape and architecture with smooth peripheral margins. There is a normal 1:3 cortex to medulla ratio with minimal to mild loss of corticomedullary distinction. There is no evidence of pyelectasia, nephroliths, infarcts or hydronephrosis. Renal vasculature is normal.

Adrenal Glands

The left adrenal gland is upper limits of normal size (0.60 cm at cranial pole) (0.68 cm at caudal pole); normal shape; homogenous parenchyma. The glandular echogenicity and detail are unremarkable. Capsule, cortex, and medullary definition are normal. The phrenicoabdominal vein and surrounding vasculature are normal.

The right adrenal gland is normal size (0.97 cm at cranial pole) (0.54 cm at caudal pole) (2.12 cm in length); normal shape; homogenous parenchyma. The glandular echogenicity and detail are unremarkable. Capsule, cortex, and medullary definition are normal. The phrenicoabdominal vein and surrounding vasculature are normal.

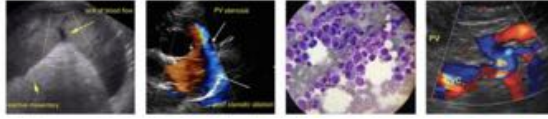
Spleen

The spleen is normal in size (1.43 cm in width at the level of the hilus) with a normal capsular contour. There is appropriate echogenicity and echotexture. No focal lesions are observed. Splenic vasculature is normal.

Liver

The liver is subjectively normal in size with normal contours and structure. There is appropriate echogenicity and echotexture. No overt structural evidence of inflammatory, infiltrative or regenerative pathology is evident. Vascular and biliary tracts are of normal volume with no evidence of congestion. No pathological hepatic lymphadenopathy observed. The portal vein to caudal vena cava ratio is approximately 1: 1.

The gall bladder is of normal contours and contains some dependent echogenic debris. The wall is normal in thickness. No choleliths are observed. The cystic and common bile ducts are normal/not seen.



PATIENT

Coconut Mood

SPECIES

Canine

BREED

Bichon Frise

SEX

Intact Male

AGE

12/3/2013

WEIGHT

23.4 lbs

INTERPRETED BY

Andrea Nicastro, DVM,
Diplomate ACVIM
(Small Animal Internal
Medicine)

IMAGING PERFORMED BY

Andrea Nicastro, DVM,
Diplomate ACVIM (Small
Animal Internal Medicine)

HOSPITAL NAME

Flowerstown AH

REFERRING VET

Dr. Kline

INVOICE

11939

DATE

11.2.2022

Gastrointestinal

The stomach and intestine are free of stasis and exhibit normal peristaltic activity. The gastric lumen is not distended. The gastric wall and pylorus are normal in thickness with a normal layering pattern. The pyloric outflow tract is patent. The small intestinal lumen is not dilated. The small intestinal wall thickness is normal with a normal layering pattern and appropriate mural detail. Discreet masses are not identified. The colonic wall is normal. No obstructive disease is noted.

Pancreas

The right limb of the pancreas is visible with normal curvilinear peripheral contours. The parenchyma is largely isoechoic relative to surrounding omental fat and slightly mottled in appearance. The pancreatic duct is visible but not overtly dilated. There is no evidence of peripancreatic inflammation or effusion.

Free Abdomen

The peritoneal cavity is normal. There is no evidence of inflammation or effusion. Two to three prominent mesenteric lymph nodes are visualized, the largest measuring 0.86 cm in length.

Other

A brief echocardiogram reveals no evidence of pericardial effusion or obvious right atrial/auricular mass.

The testicles are subjectively normal in size (left: 2.30 x 1.44 cm) (right: 2.50 x 1.18 cm) and symmetrical with homogenous parenchyma. No focal lesions are observed.

ULTRASONOGRAPHIC FINDINGS

Primary Findings

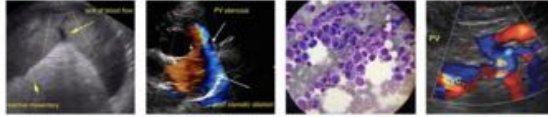
- An obvious cause for the patient's gastrointestinal signs is not identified in this study. Considerations include dietary indiscretion, infectious/parasitic disease, food allergy/intolerance, inflammatory bowel disease, underlying metabolic issue, low-grade pancreatitis, other.

Secondary Findings

- Mild, bilateral, degenerative renal changes
- The prostate changes are most consistent with benign prostatic hyperplasia. Bacterial prostatitis is also a differential but considered unlikely in the absence of lower urinary tract signs.
- The lymph node changes are most consistent with reactive lymphadenitis or lymphoid hyperplasia.
- The pancreatic changes are most consistent with age-related parenchymal remodeling, potentially secondary to a prior inflammatory episode, early fibrosis or chronic pancreatitis.

INTERPRETATION OF THE FINDINGS & FURTHER RECOMMENDATIONS

- Baseline lab work, including a CBC chemistry panel, urinalysis and T4 is recommended to assess overall metabolic function.
- Also consider a cPLI to assess for low-grade pancreatitis.



PATIENT

Coconut Mood

SPECIES

Canine

BREED

Bichon Frise

SEX

Intact Male

AGE

12/3/2013

WEIGHT

23.4 lbs

INTERPRETED BY

Andrea Nicastro, DVM,
Diplomate ACVIM
(Small Animal Internal
Medicine)

IMAGING PERFORMED BY

Andrea Nicastro, DVM,
Diplomate ACVIM (Small
Animal Internal Medicine)

HOSPITAL NAME

Flowerstown AH

REFERRING VET

Dr. Kline

INVOICE

11939

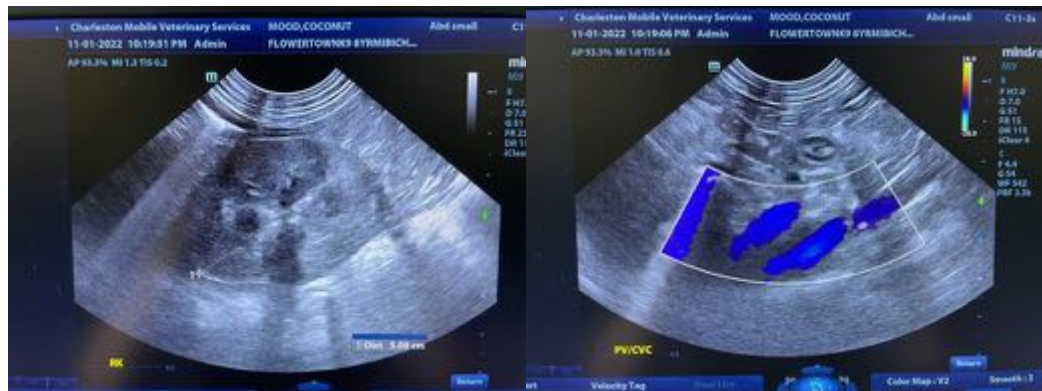
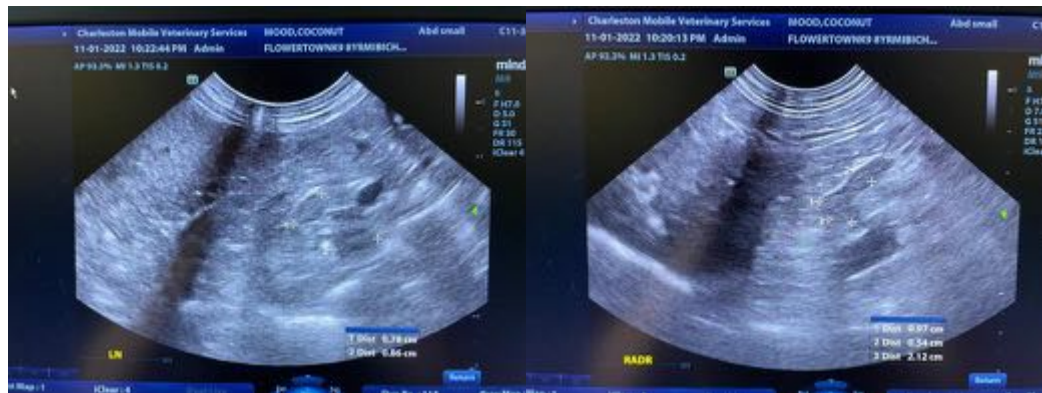
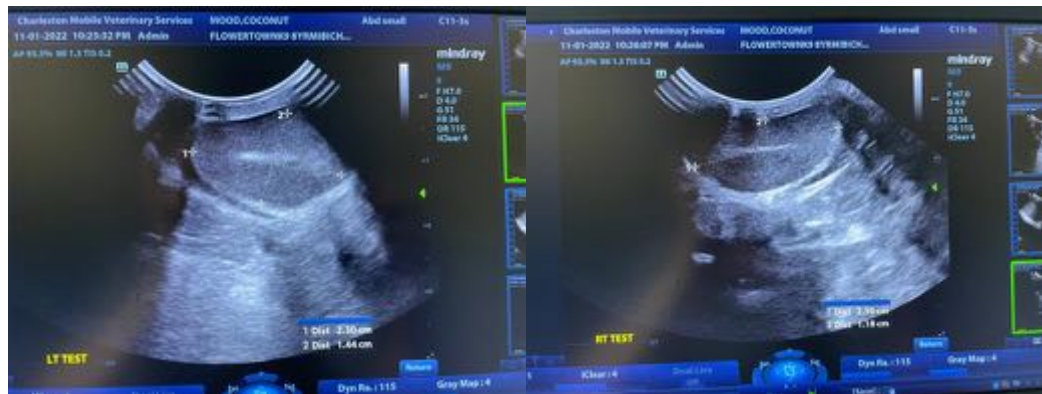DATE

11.2.2022

- A fecal evaluation for ova and Giardia is recommended.

- Consider prophylactic deworming with Fenbendazole

- Supportive care for acute gastroenteritis is recommended. If the patient's clinical signs do not begin to improve within 48-72 hours of medical management, a more advance GI work-up may be warranted.





PATIENT

Coconut Mood

SPECIES

Canine

BREED

Bichon Frise

SEX

Intact Male

AGE

12/3/2013

WEIGHT

23.4 lbs

INTERPRETED BY

Andrea Nicastro, DVM,
Diplomate ACVIM
(Small Animal Internal
Medicine)

**IMAGING
PERFORMED BY**

Andrea Nicastro, DVM,
Diplomate ACVIM (Small
Animal Internal Medicine)

HOSPITAL NAME

Flowertown AH

REFERRING VET

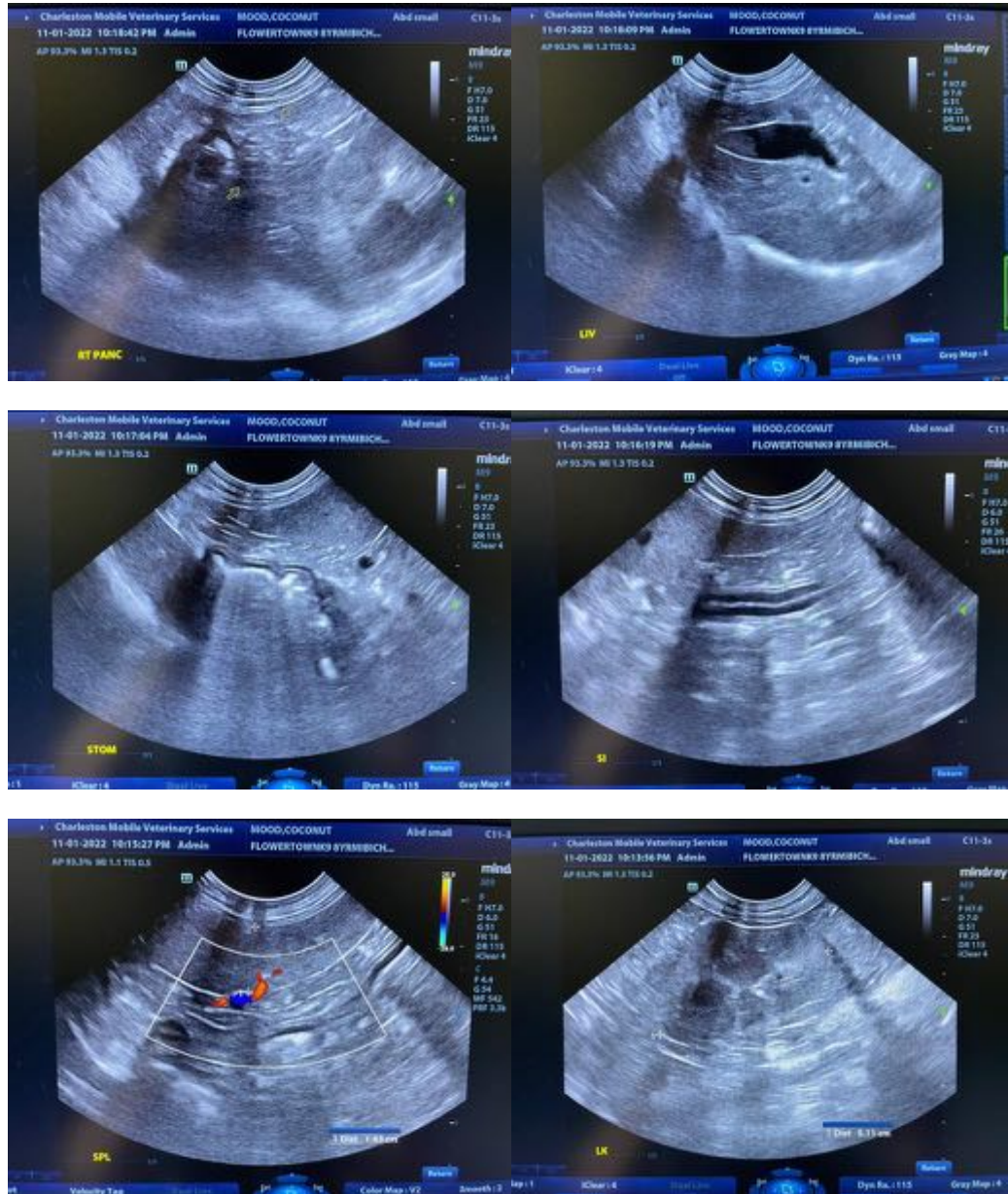Dr. Kline

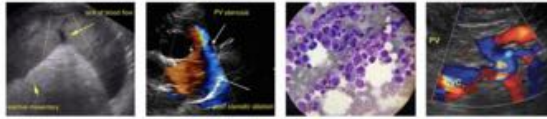
INVOICE

11939

DATE

11.2.2022





PATIENT

Coconut Mood

SPECIES

Canine

BREED

Bichon Frise

SEX

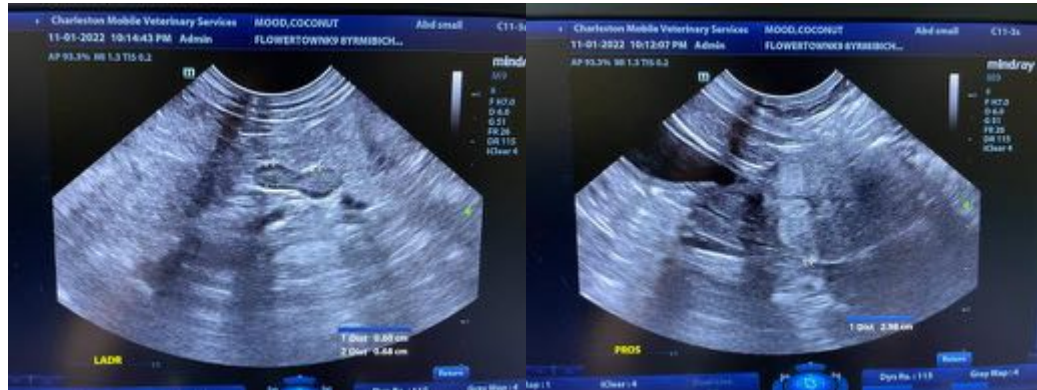
Intact Male

AGE

12/3/2013

WEIGHT

23.4 lbs



The information and recommendations provided are based on the images presented by the referring veterinarian/sonographer. No evaluation can be communicated regarding pathology that was not visible in the image/video clips provided.

Thank you for this referral. If the clinical or image interpretation does not parallel your findings or if I can be of any further assistance, please contact me.

Andrea Nicastro, MPH, DVM, Diplomate DACVIM (Small Animal Internal Medicine)
info@SonoPath.com

INTERPRETED BY

Andrea Nicastro, DVM,
Diplomate ACVIM
(Small Animal Internal
Medicine)

IMAGING PERFORMED BY

Andrea Nicastro, DVM,
Diplomate ACVIM (Small
Animal Internal Medicine)

HOSPITAL NAME

Flowertown AH

REFERRING VET

Dr. Kline

INVOICE

11939

DATE

11.2.2022