



## PATIENT PRESENTING CLINICAL SIGNS

**Koco Pena**  
**SPECIES** Canine  
History: Patient presented here on the evening of 11/15 as a transfer from the rDVM. O took P to Vetco yesterday following about 1 week of increased water intake and increased urination (large quantity, clear in color). Vetco ran bloodwork, showed elevated kidney values, and signs of pancreatitis. Vomiting every other day; once was large amount of undigested kibble. Eating well at home. Normal stools. Patient hospitalized on IVF last night and has been NPO after 9am

**BREED** Maltese Mix  
Abnormal PE/Chem/CBC/UA Results: rDVM Blood Work 11/14: HCT 45.1 (N), WBC 6.1 (N), Neut 4.04 (N), Lymph 1.434 (N), Mono 0.384 (N), Plt 588 (H) Chem: SDMA 26 (H), Creat 4.1 (H), BUN 98 (H), Phos 9.1 (H), K+ 5.5 (H)- suspect handling artifact, Glob 4.1 (H), ALT 161 (H), Lipase 460 (H) Spec cPL: 605 (H) UA: USG 1.013 (L), pH 6, Protein 2+, glucose/ketones/bilirubin negative, WBC 0-2/hpf, RBC 0-2/hpf, no bacteria/crystals reported T4: 1.6 (N) WilVet Salem Bloodwork 11/15: EPOC: pH 7.297 (L), K+ 4.7 (N), BUN 100 (H)\*\* , Creat 4.04 (H)\*\* , HCT 45 PCV/TS: 48%/8.6 Urine culture- pending to idexx

Neutered Male

## ULTRASONOGRAPHIC EXAMINATION OF THE ABDOMEN

### AGE *Urinary System*

16.5 The urinary bladder wall is normal in thickness. The mucosal surface is smooth. The bladder is moderately distended. Luminal contents are mostly anechoic. No cystic calculi are observed. The region of the trigone and visible portion of the proximal urethra are normal.

### WEIGHT

6 kg

The region of the prostate is not visualized due to its pelvic location.

## INTERPRETED BY

Andrea Nicastro, DVM,  
Diplomate ACVIM  
(Small Animal Internal  
Medicine)

The left kidney is normal in size (3.43 cm in length) with a normal shape, smooth peripheral margins, and normal internal architecture. There is mild to moderate loss of corticomedullary distinction. The cortex is isoechoic relative to the spleen. One-to-two, small, cortical cysts are seen. Several hyperechoic shadowing diverticular foci are observed. Pinpoint hyperechoic foci are observed within the cortex. Mild to moderate pyelectasia is present (0.21 cm in the transverse plane). There is no evidence of infarcts or hydroureter.

## IMAGING PERFORMED BY

Chris Hovenden

The right kidney is normal in size (4.74 cm in length) with a normal shape, architecture and smooth peripheral margins. There is a normal 1:3 cortex to medulla ratio with moderate loss of corticomedullary distinction. The cortex is isoechoic-to-hyperechoic relative to the spleen. Several cortical cysts are seen. Hyperechoic shadowing diverticular foci are visualized. Trace pyelectasia is present. There is no evidence of hydroureter.

## HOSPITAL NAME

Wilvet Salem

### *Adrenal Glands*

The left adrenal gland is mildly enlarged (0.44 cm at cranial pole) (0.55 cm at caudal pole) with a relatively normal shape. Glandular echogenicity and detail are normal. The phrenicoabdominal vein and surrounding vasculature are normal.

## REFERRING VET

Chris Hovenden

No images provided of the right adrenal gland.

## INVOICE

22266

### *Spleen*

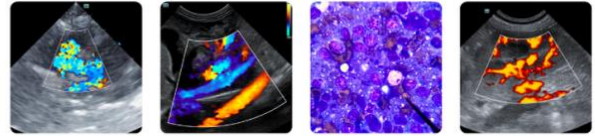
The spleen is normal in size (1.25 cm in width at the level of the hilus) with a normal capsular contour. The parenchyma is subtly mottled in appearance. A few, small, myelolipomas are observed in the region of the hilus. Splenic vasculature is normal.

## DATE

11-16-25

### *Liver*

The liver is normal to slightly prominent-in-size with smooth peripheral contours. The parenchyma is isoechoic relative to the spleen and exhibits mild heterogeneity. No distinct focal lesions are



## PATIENT

Koco Pena

## SPECIES

Canine

## BREED

Maltese Mix

## SEX

Neutered Male

## AGE

16.5

## WEIGHT

6 kg

## INTERPRETED BY

Andrea Nicastro, DVM,  
Diplomate ACVIM  
(Small Animal Internal  
Medicine)

## IMAGING PERFORMED BY

Chris Hovenden

## HOSPITAL NAME

Wilvet Salem

## REFERRING VET

Chris Hovenden

## INVOICE

22266

## DATE

11-16-25

observed. Hepatic vasculature and biliary tracts are of normal volume with no evidence of congestion. The portal vein to caudal vena cava ratio is approximately 1: 1.

The gallbladder lumen is moderately distended. The wall is thin and smooth. A few polypoid-like lesions are arising from the mucosal surface. A small to moderate amount of aggregated, echogenic-to-mineralized, mostly gravity-dependent debris/sand is observed within the lumen. The cystic and common bile ducts are normal/not seen. The duodenal papilla is normal-in-size (0.34 cm in width).

### Gastrointestinal

The gastric lumen is not distended. The gastric wall and pylorus are normal in thickness with a normal layering pattern. The pyloric outflow tract is patent. The small intestinal lumen is not dilated. The small intestinal wall is normal in thickness with a normal layering pattern and appropriate mural detail. Discreet masses are not identified. The colonic wall is normal. There is no evidence of an obstructive pattern.

### Pancreas

The base and limbs of the pancreas are visible with normal curvilinear peripheral contours. The parenchyma is largely isoechoic relative to surrounding omental fat and slightly mottled in appearance. The pancreatic duct is visible but not overtly dilated. There is no evidence of peripancreatic inflammation or effusion.

### Lymph Nodes

The abdominal lymph nodes are normal/not visible.

### Free Abdomen

There is no obvious evidence of free fluid.

## ULTRASONOGRAPHIC FINDINGS

### Primary Findings

- Bilateral nonspecific chronic renal changes with dystrophic mineralization, cortical cysts, and pyelectasia. The pyelectasia may be secondary to parenchymal remodeling, pyelonephritis, PU/PD (if applicable), fluid therapy (if applicable), or some combination thereof.

### Secondary Findings

- The pancreatic changes are most consistent with age-related parenchymal remodeling, potentially secondary to a prior inflammatory episode, early fibrosis or chronic pancreatitis.
- The hepatic changes are nonspecific and could be secondary to inflammatory disease (i.e., cholangiohepatitis, chronic hepatitis), Leptospirosis, hepatotoxicosis, infiltrative neoplasia (i.e., lymphoma), vacuolar hepatopathy, regenerative nodular hyperplasia, reactive hepatopathy, other hepatopathy, or some combination thereof.
- Gallbladder debris/sand, non-mucocele
- The splenic parenchymal changes are most consistent with a benign process such as lymphoid hyperplasia, extramedullary hematopoiesis, splenitis or antigenic stimulation with a low possibility of infiltrative neoplasia (i.e., lymphoma, mast cell neoplasia).
- Mild left adrenomegaly. (The right adrenal gland is not visualized in the available images).



**PATIENT INTERPRETATION OF THE FINDINGS & FURTHER RECOMMENDATIONS**

Koco Pena

**SPECIES**

Canine

**BREED**

Maltese Mix

**SEX**

Neutered Male

**AGE**

16.5

**WEIGHT**

6 kg

**INTERPRETED BY**

Andrea Nicastro, DVM,  
Diplomate ACVIM  
(Small Animal Internal  
Medicine)

**IMAGING PERFORMED BY**

Chris Hovenden

**HOSPITAL NAME**

Wilvet Salem

**REFERRING VET**

Chris Hovenden

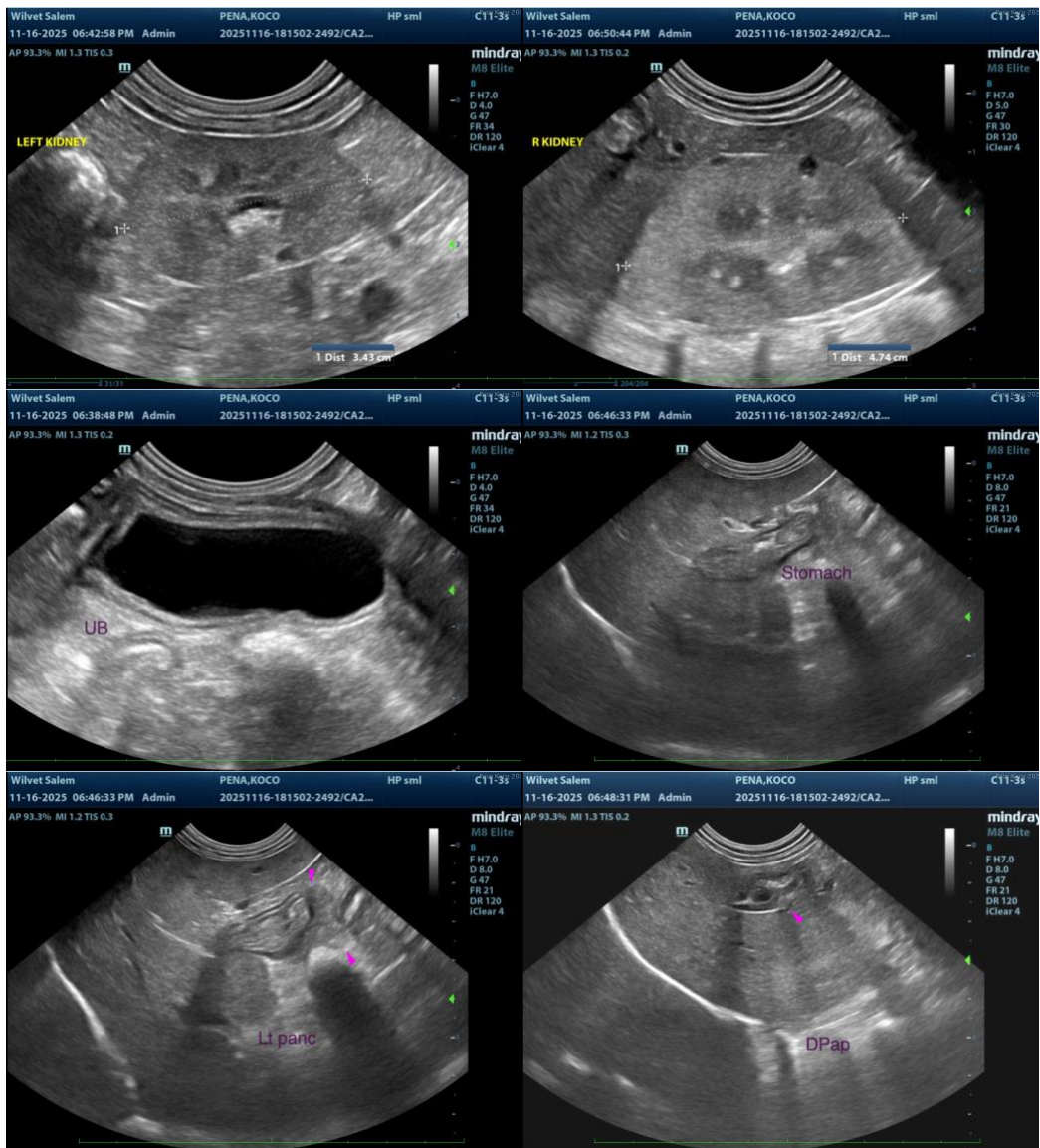
**INVOICE**

22266

**DATE**

11-16-25

- Given the patient's clinical history and sonographic changes, consider the following:
  1. UPC if proteinuria persists in the absence of infection
  2. Baseline blood pressure measurement
  3. Three-view thoracic radiographs to assess cardiopulmonary status
  4. Continued IV fluid diuresis and supportive care with serial monitoring of the patient's renal values to assess progression of the azotemia
  5. Once the patient is eating again, consider transitioning to a prescription renal diet (if tolerated).



The information and recommendations provided are based on the images presented by the referring veterinarian/sonographer. No evaluation can be communicated regarding pathology that was not visible in the image/video clips provided.



## PATIENT

Koco Pena

Thank you for this referral. If the clinical or image interpretation does not parallel your findings or if I can be of any further assistance, please contact me.

## SPECIES

Canine

**Andrea Nicastro, MPH, DVM, Diplomate DACVIM (Small Animal Internal Medicine)**  
[info@SonoPath.com](mailto:info@SonoPath.com)

## BREED

Maltese Mix

## SEX

Neutered Male

## AGE

16.5

## WEIGHT

6 kg

## INTERPRETED BY

Andrea Nicastro, DVM,  
Diplomate ACVIM  
(Small Animal Internal  
Medicine)

## IMAGING PERFORMED BY

Chris Hovenden

## HOSPITAL NAME

Wilvet Salem

## REFERRING VET

Chris Hovenden

## INVOICE

22266

## DATE

11-16-25