



PATIENT

Loki Wilson

SPECIES

Feline

BREED

Bengal

SEX

Male, neutered

AGE

6 Yrs.

WEIGHT

5.51 kg.

INTERPRETED BY

Andrea Nicastro, DVM,
Diplomate ACVIM
(Small Animal Internal
Medicine)

**IMAGING
PERFORMED BY**

Tom McNeill

HOSPITAL NAME

SVS Imaging CT

REFERRING VET

Dr. Graham

INVOICE

14239

DATE
11/16/22

PRESENTING CLINICAL SIGNS

History: Loki presented to the MVS Emergency Service on Nov 16, 2022, at (12:45pm), for evaluation for vomiting, anorexia, and febrile.

Abnormal PE/Chem/CBC/UA Results: For the last 3 days, Loki hasn't been acting like himself. He is usually very active, but has been hiding underneath the bed and has been disinterested in eating - he usually eats alot. He also hasn't been drinking or using the litterbox to owners knowledge. His temperature at the pcDVM this morning was 105.2°F Loki is otherwise a healthy cat.

ULTRASONOGRAPHIC EXAMINATION OF THE ABDOMEN

Urinary System

The urinary bladder wall is normal in thickness and the mucosal surface is smooth. The bladder lumen is mildly to moderately distended. A small amount of suspended echogenic debris is observed within the lumen. No masses, inflammatory changes or calculi are observed. Ureteral papillae and visualized portion of the proximal urethra, visible to a depth of 2 cm, are normal.

The left kidney is normal size (3.95 cm in length); normal shape and architecture with smooth peripheral margins. The cortex is mildly hyperechoic. There is a normal 1:3 cortex to medulla ratio with mild loss of corticomedullary distinction. There is no evidence of pyelectasia, nephroliths, infarcts or hydroureter.

The right kidney is normal size (3.40 cm in length); normal shape and architecture with smooth peripheral margins. The cortex is mildly hyperechoic. There is a normal 1:3 cortex to medulla ratio with mild to moderate loss of corticomedullary distinction. There is no evidence of pyelectasia, nephroliths, infarcts or hydroureter.

Adrenal Glands

The left adrenal gland is borderline enlarged (0.53 cm width). Normal shape and glandular echogenicity. The phrenicoabdominal vein and surrounding vasculature are normal.

The right adrenal gland is normal in size (0.42 cm width). Normal shape and glandular echogenicity. The phrenicoabdominal vein and surrounding vasculature are normal.

Spleen

The spleen is prominent in size (1.02 cm in width at the level of the hilus) with a slightly irregular medial contour. There is appropriate echogenicity and echotexture. No focal lesions are observed. Splenic vasculature is normal.

Liver

The liver is subjectively normal in size with normal contours and structure. There is appropriate echogenicity and echotexture. No overt structural evidence of inflammatory, infiltrative or regenerative pathology is evident. Vascular and biliary tracts are of normal volume with no evidence of congestion. No pathological hepatic lymphadenopathy observed. The gall bladder lumen is moderately distended. The wall is thin and smooth. Luminal contents are anechoic. The cystic and common bile ducts are normal/not seen.

Gastrointestinal

The gastric lumen is not distended. The gastric wall and pylorus are normal in thickness with a normal layering pattern. The pyloric outflow tract is patent. The small intestinal lumen is segmentally dilated with chyme. In one short (1.5-2 cm) segment of jejunum, the wall is thickened (up to 0.49 cm) with



PATIENT

Loki Wilson

possible early loss of the normal layering pattern. In the remaining small intestinal segments, the wall is normal in thickness with a normal layering pattern and appropriate mural detail. The ileocecolic junction and colonic wall are normal. No obstructive disease is noted.

SPECIES

Feline

Pancreas

The pancreas is diffusely visible/prominent with minimal deviation from the normal peripheral contours. The parenchyma is hypoechoic relative to surrounding omental fat and subtly mottled in appearance. No distinct focal lesions are observed. The pancreatic duct is visible but not overtly dilated (0.13 cm in diameter). Surrounding mesentery is hyperechoic.

BREED

Bengal

Free Abdomen

Trace free fluid is observed. Several prominent lymph nodes are observed at the ileocecolic junction, the largest measuring 0.99 cm in length. Several mesenteric lymph nodes are also observed, the largest measuring 2.01 cm in length. A 0.96 cm lymph node is also seen in the right cranial quadrant. The mesentery surrounding all nodes is hyperechoic.

SEX

Male, neutered

AGE

6 Yrs.

ULTRASONOGRAPHIC FINDINGS

Primary Findings:

- The pancreatic changes are most concerning for mild to moderate acute or chronic active pancreatitis.
- The thickening of the jejunal segment is concerning for emerging neoplasia (i.e., lymphoma). However, a focal inflammatory process cannot be completely excluded.
- The abdominal lymphadenopathy may be secondary to emerging neoplasia (i.e., lymphoma) or reactive change.
- The trace ascites may be secondary to increased vascular permeability (i.e., due to vasculitis), low oncotic pressure or increased hydrostatic pressure. Correlation with the patient's clinical history is recommended.

Secondary Findings:

- The borderline left adrenomegaly may be secondary to stress, hyperplasia or less likely, an emerging tumor.
- Bilateral, chronic age-related renal changes.

INTERPRETATION OF THE FINDINGS & FURTHER RECOMMENDATIONS

- Baseline labwork including a CBC chemistry panel, urinalysis and T4 is recommended to assess overall metabolic function.
- Three-view thoracic radiographs are recommended to assess cardiopulmonary status, if not already performed.
- Supportive care for pancreatitis is recommended including IV fluid therapy, gastric protectants, antiemetics, pain medication as needed, +/- fresh frozen plasma.

INTERPRETED BY

Andrea Nicastro, DVM,
Diplomate ACVIM
(*Small Animal Internal
Medicine*)

**IMAGING
PERFORMED BY**

Tom McNeill

HOSPITAL NAME

SVS Imaging CT

REFERRING VET

Dr. Graham

INVOICE

14239

DATE

11/16/22



PATIENT

Loki Wilson

- Consider a malabsorption panel including serum cobalamin, folate, TLI and PLI.
- Regarding the jejunal thickening, surgical biopsies would be necessary to get a definitive diagnosis. If surgery is not pursued at this time, consider a repeat ultrasound in 2-3 weeks to assess for progression.

SPECIES

Feline

BREED

Bengal

SEX

Male, neutered

AGE

6 Yrs.

WEIGHT

5.51 kg.

INTERPRETED BY

Andrea Nicastro, DVM,
Diplomate ACVIM
(Small Animal Internal
Medicine)

IMAGING PERFORMED BY

Tom McNeill

HOSPITAL NAME

SVS Imaging CT

REFERRING VET

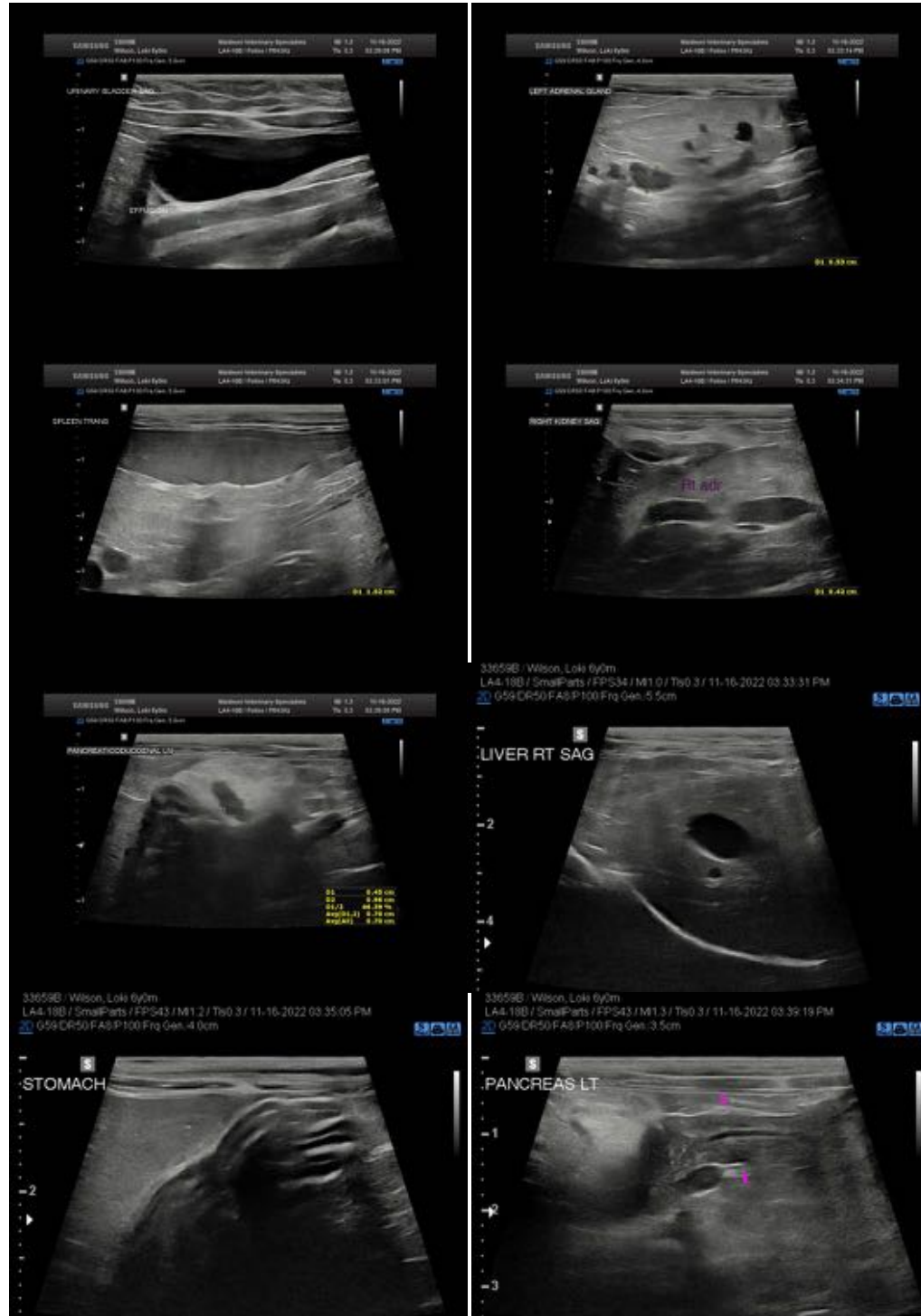Dr. Graham

INVOICE

14239

DATE

11/16/22





PATIENT

Loki Wilson

SPECIES

Feline

BREED

Bengal

SEX

Male, neutered

AGE

6 Yrs.

WEIGHT

5.51 kg.

INTERPRETED BY

Andrea Nicastro, DVM,
Diplomate ACVIM
(Small Animal Internal
Medicine)

**IMAGING
PERFORMED BY**

Tom McNeill

HOSPITAL NAME

SVS Imaging CT

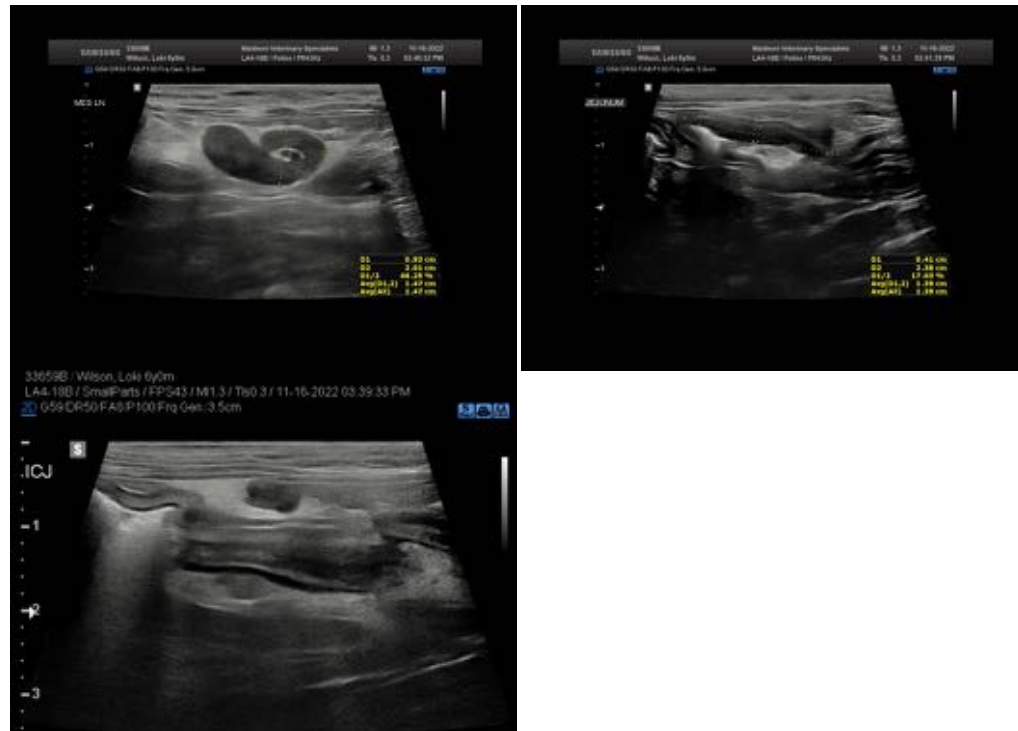
REFERRING VET

Dr. Graham

INVOICE

14239

DATE
11/16/22



The information and recommendations provided are based on the images presented by the referring veterinarian/sonographer. No evaluation can be communicated regarding pathology that was not visible in the image/video clips provided.

Thank you for this referral. If the clinical or image interpretation does not parallel your findings or if I can be of any further assistance please contact me.

Andrea Nicastro, MPH, DVM, Diplomate DACVIM (Small Animal Internal Medicine)
info@SonoPath.com