**DATE**

11/16/21

PRESENTING CLINICAL SIGNS

History: Vomiting & Appetite Decreased.

Date: 11-16-2021 Notes: Diabetic since March also diagnosed with a mass between the pancreas and liver. Not eating for 2 days.

PATIENT

Molly Fritz

Date of Previous IntraPet Ultrasound: 6/15/21.

Sedation: Not required to complete full diagnostic ultrasound.

Stat Report: Not requested.

SPECIES

Canine

BREED

Puggle

SEX

Female, spayed

AGE

2011

WEIGHT

23.1 lbs.

INTERPRETED BY

Andrea Nicastro,
DVM, Diplomate
ACVIM (*Small
Animal Internal
Medicine*)

IMAGING PERFORMED BY

Rachel Brillhart
RDMS

HOSPITAL NAME

Animal Emergency
Hospital

REFERRING VET

Dr. Ruby

INVOICE

12550

ULTRASONOGRAPHIC EXAMINATION OF THE ABDOMEN**Urinary System**

The urinary bladder is moderately distended. The wall is normal to mildly thickened (up to 0.32 cm) with a smooth mucosal surface. Luminal contents are anechoic. No cystic calculi are observed. The region of the trigone and the visible portion of the proximal urethra are normal.

The left kidney is normal size (6.78 cm in length); normal shape and architecture with smooth peripheral margins. There is a normal 1:3 cortex to medulla ratio with minimal loss of corticomedullary distinction. The cortex is hyperechoic. A thin, hyperechoic medullary band is observed adjacent to the corticomedullary junction. Mild pyelectasia is present (0.32 cm in the longitudinal plane). There is no evidence of nephroliths, infarcts or hydronephrosis. Renal vasculature is normal.

The right kidney is normal size (7.44 cm in length); normal shape and architecture with smooth peripheral margins. There is a normal 1:3 cortex to medulla ratio with minimal loss of corticomedullary distinction. The cortex is hyperechoic. A thin, hyperechoic medullary band is observed at the corticomedullary junction. A small cortical cyst is observed at the lateral aspect. There is no evidence of pyelectasia, nephroliths, infarcts or hydronephrosis. Renal vasculature is normal.

Adrenal Glands

The left adrenal gland is mildly enlarged (0.73 cm at cranial pole) (0.80 cm at caudal pole) (2.65 cm in length); normal shape; homogenous parenchyma. The glandular echogenicity and detail are unremarkable. Capsule, cortex, and medullary definition are normal. The phrenicoabdominal vein and surrounding vasculature are normal.

The right adrenal gland is mildly enlarged (0.98 cm at cranial pole) (0.88 cm at caudal pole) (2.35 cm in length); normal shape; homogenous parenchyma. The glandular echogenicity and detail are unremarkable. Capsule, cortex, and medullary definition are normal. The phrenicoabdominal vein and surrounding vasculature are normal.

Spleen

A 3.54 x 2.95 cm irregular hyperechoic mass is arising from the caudal aspect. The mass causes capsular expansion. The remaining splenic contours are curvilinear. The remaining parenchyma is mostly homogeneous. Splenic vasculature is normal with no evidence of thrombosis.

Liver

The liver is subjectively prominent in size with normal curvilinear peripheral contours. The parenchyma is similar in echogenicity relative to the spleen and diffusely heterogeneous in appearance with several ill-defined hyperechoic nodules throughout the organ. Vascular and biliary tracts are of normal volume with no evidence of congestion. The gallbladder is of normal contours and contains some dependent echogenic debris. The wall is normal in thickness. No choleliths are observed. The cystic and common bile ducts are normal.

Gastrointestinal

The stomach and intestine are free of stasis and exhibit normal peristaltic activity. The gastric lumen is not distended. The gastric wall and pylorus are normal in thickness with a normal layering pattern. The pyloric outflow tract is patent. The small intestinal lumen is not dilated. The small intestinal wall thickness is normal with a normal layering pattern and appropriate mural detail. Discreet masses are not identified. The colonic wall is normal. No obstructive disease is noted.

Pancreas

The pancreas is diffusely enlarged with slightly irregular peripheral contours. The parenchyma is hypoechoic relative to surrounding omental fat and mottled in appearance. The pancreatic duct is dilated (0.34 cm in diameter). The mesentery effacing the serosal surface is slightly hyperechoic.

Free Abdomen

There is no evidence of free fluid. A 2.12 cm lymph node is observed at the aortic trifurcation.

Other

A 1.40 x 0.93 cm echogenic nodule is observed in the left cranial quadrant.

A brief echocardiogram reveals no evidence of pericardial effusion.

ULTRASONOGRAPHIC FINDINGS

Primary Findings:

- Splenic mass- similar in size compared to previous sonogram.
- The hepatic parenchymal changes are non-specific and could be secondary to benign age-related pathology. Alternatively, infiltrative neoplasia (i.e., round cell tumor) may be present. Cytology or histopathology would be necessary to differentiate these possibilities.
- The pancreatic changes could be consistent with acute or chronic active pancreatitis.

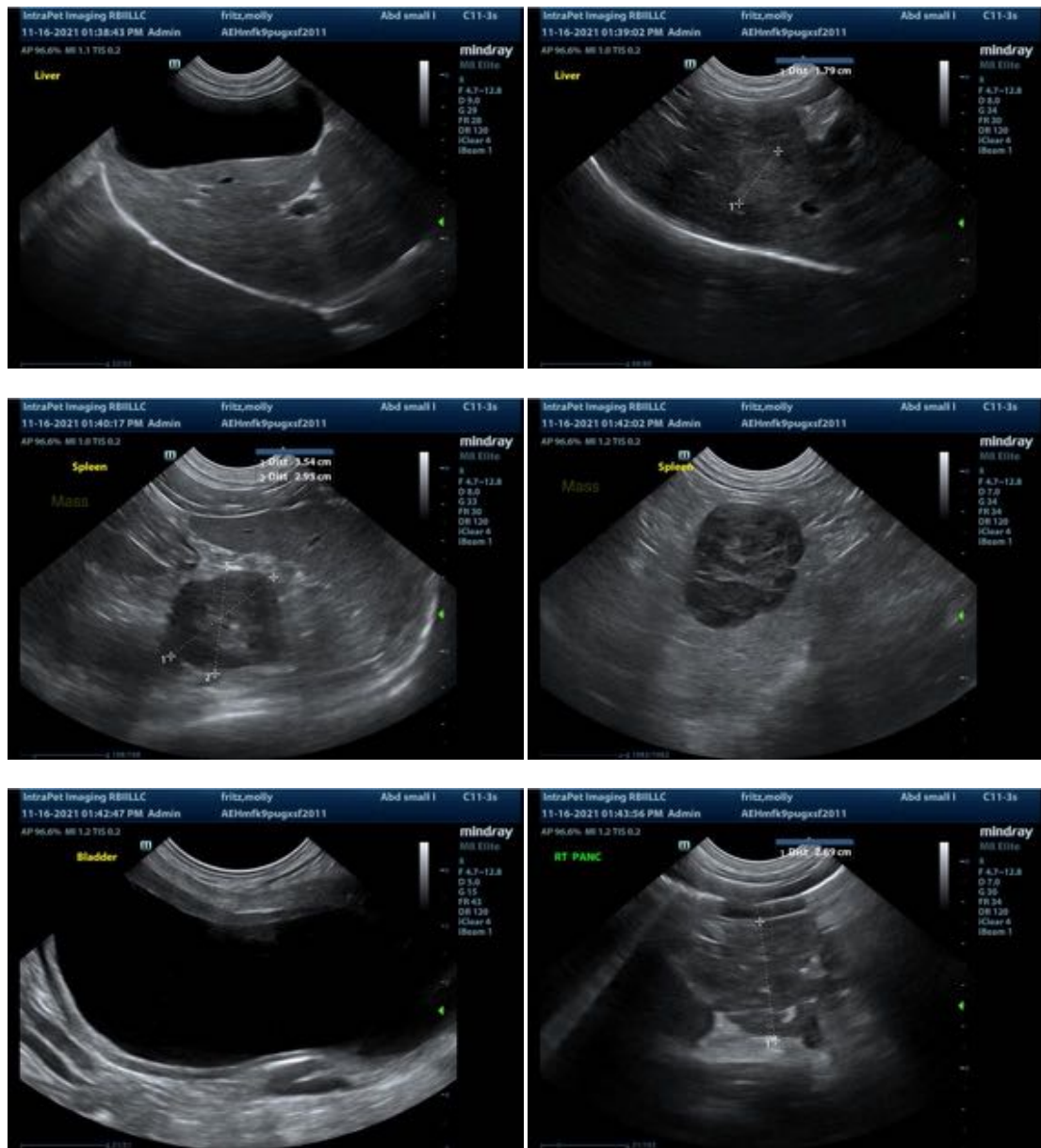
Secondary Findings:

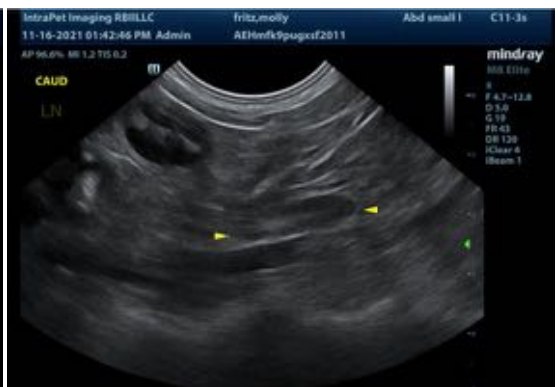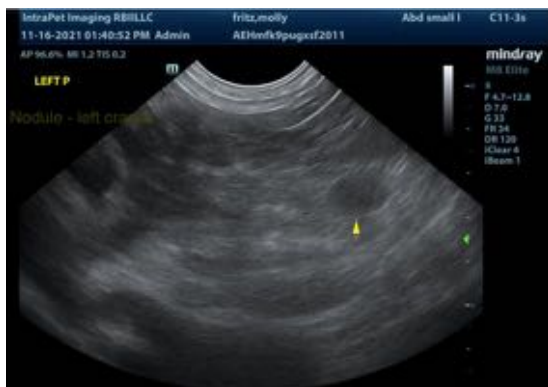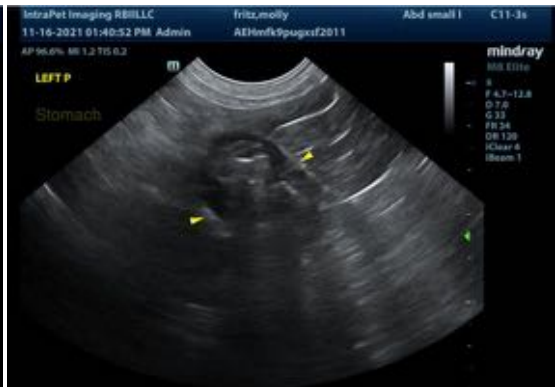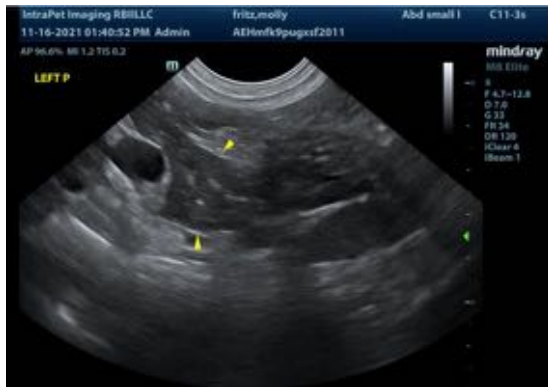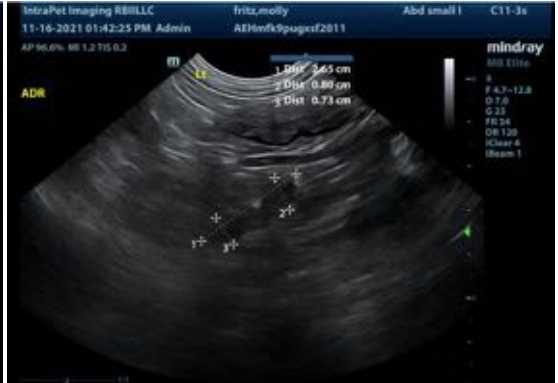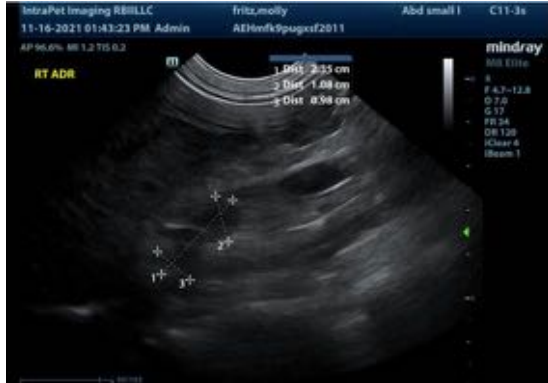- Mild bilateral adrenomegaly- previously observed/no significant changes.
- The bilateral age-related renal changes are similar to the previous sonogram.
- The mild bladder wall thickening may represent a normal variant for this patient or may be secondary to low-grade cystitis. Correlation with clinical findings is recommended.
- The echogenic nodule in the left cranial quadrant is similar in size compared to the previous sonogram.

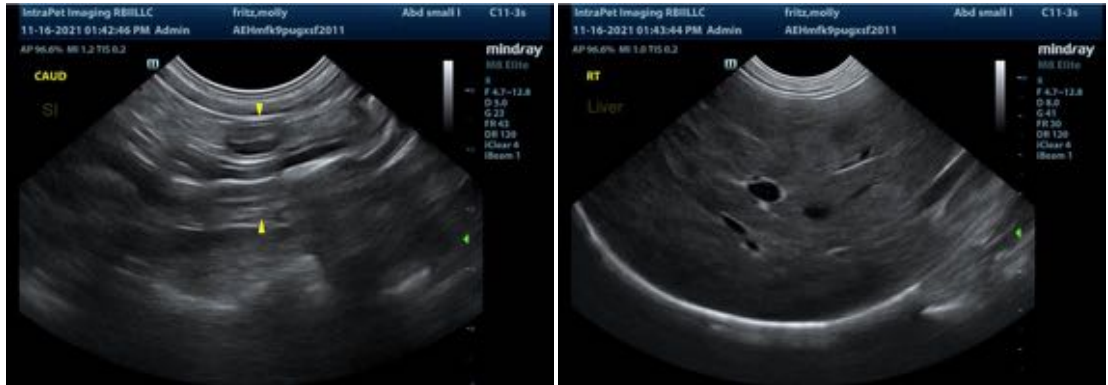
INTERPRETATION OF THE FINDINGS & FURTHER RECOMMENDATIONS

- Baseline labwork including a CBC chemistry panel, urinalysis and T4 is recommended, if not already performed.
- Supportive care for pancreatitis is recommended including fluid therapy, gastric protectants, pain medications +/- fresh frozen plasma.

- Also consider a GI panel (sent to Texas A&M) to further assess for small intestinal disease and to confirm pancreatitis.
- Given the patient's age, three-view thoracic radiographs are recommended to assess cardiopulmonary status.







The information and recommendations provided are based on the images presented by the referring veterinarian. No evaluation can be communicated regarding pathology that was not visible in the image/video clips provided.

Thank you for this referral. If the clinical or image interpretation does not parallel your findings or if I can be of any further assistance please contact me.

Andrea Nicastro, DVM, Diplomate ACVIM (*Small Animal Internal Medicine*)
Andrea.nicastro@sonopath.com