

**DATE PRESENTING CLINICAL SIGNS**

11/12/21

History: Patient presented on 11/02 annual exam and vaccines with lab work. Patient has a grade II/VI left systolic heart murmur. Moderate dental tartar. Mild cervical spinal pain. Otherwise PE WNL.

**PATIENT**

Broncho Mashii

When performing ultrasound-guided cystocentesis to obtain a urine sample, the tissue surrounding the bladder was found to be hyperechoic, therefore a sample was not obtained and full abdominal ultrasound recommended.

**SPECIES**

Canine

Current Medications: Gabapentin 50mg: 1.5 tab PO BID  
 Lab Results: Chem: Significant lipase elevation, otherwise WNL  
 Urinalysis (free catch dropped off by owner): rare cocci noted  
 Date of Previous IntraPet Ultrasound: No previous

**BREED**

Miniature Schnauzer

Sedation: Not required for scan.  
 Stat Report: Not requested.

**ULTRASONOGRAPHIC EXAMINATION OF THE ABDOMEN****SEX**

Neutered Male

**Urinary System**

The urinary bladder, trigone, and pelvic urethra are normal in thickness and the mucosal surface is smooth. The bladder lumen is moderately distended with anechoic urine. No masses, inflammatory changes or calculi are observed. Ureteral papillae and visualized portion of the proximal urethra, visible to a depth of 2 cm, are normal.

**AGE**

2010

The prostate is normal in size (0.95 cm) and shape. Parenchyma is homogenous. The prostatic urethra appears normal without evidence of dilation or obstruction.

**WEIGHT**

18.1 Pounds

The left kidney presented normal size (4.94 cm in length); normal shape and architecture with smooth peripheral margins. There is a normal 1:3 cortex to medulla ratio with normal corticomedullary distinction. Pinpoint nephroliths are visualized. There is no evidence of pyelectasia, infarcts or hydroureter. Renal vasculature is normal.

**INTERPRETED BY**

Andrea Nicastro, DMV,  
 Diplomate DACVIM  
 (Small Animal  
 Internal Medicine)

The right kidney presented normal size (4.97 cm in length); normal shape and architecture with smooth peripheral margins. There is a normal 1:3 cortex to medulla ratio with normal corticomedullary distinction. Pinpoint nephroliths are visualized. There is no evidence of pyelectasia, infarcts or hydroureter. Renal vasculature is normal.

**IMAGING PERFORMED BY**

Rachel Brilhart RDMS

**Adrenal Glands**

The left adrenal gland is normal size (0.57 cm at cranial pole) (0.50 cm at caudal pole) (1.91 cm in length); normal shape; homogenous parenchyma. The glandular echogenicity and detail are unremarkable. Capsule, cortex, and medullary definition are normal. The phrenicoabdominal vein and surrounding vasculature are normal.

**HOSPITAL NAME**

Churchville Vet Clinic

The right adrenal gland is normal size (0.72 cm at cranial pole) (0.48 cm at caudal pole) (2.41 cm in length); normal shape; homogenous parenchyma. The glandular echogenicity and detail are unremarkable. Capsule, cortex, and medullary definition are normal. The phrenicoabdominal vein and surrounding vasculature are normal.

**REFERRING VET**

Dr. Kauffman

**Spleen**

The spleen is normal in size (1.58 cm) with a normal capsular contour. The parenchyma is subtly mottled in appearance. No focal lesions are observed. Splenic vasculature is normal.

**INVOICE**

29803

### ***Liver***

The liver is subjectively normal in size with normal curvilinear peripheral contours. The parenchyma is hypoechoic relative to the spleen and has a finely heterogeneous pattern. A 1.33 cm x 1.21 cm hyperechoic nodule is observed at the caudal aspect. Hepatic vasculature and intrahepatic biliary tracts are of normal volume with no evidence of congestion.

The gall bladder lumen is moderately distended. The wall is thin and smooth. A moderate amount of aggregated echogenic to mineralized partially dependent sludge is observed within the lumen. The cystic and common bile ducts are normal.

### ***Gastrointestinal***

The stomach and intestine are free of stasis and exhibit normal peristaltic activity. The gastric lumen is not distended. The gastric wall and pylorus are normal in thickness with a normal layering pattern. The small intestinal lumen is diffusely distended with chyme. The small intestinal wall thickness is normal with a normal layering pattern and appropriate mural detail. Discreet masses are not identified. The colonic wall is normal. No obstructive or overt infiltrative disease is noted.

### ***Pancreas***

The body/right limb of the pancreas is prominent in size with minimal deviation from the normal peripheral contours. The parenchyma is isoechoic relative to surrounding omental fat and is mottled in appearance. No distinct focal lesions are observed. The pancreatic duct is not overtly dilated. The mesentery effacing the serosal surface is mildly hyperechoic.

### ***Free Abdomen***

There is no evidence of free fluid. The abdominal lymph nodes are normal/not visible.

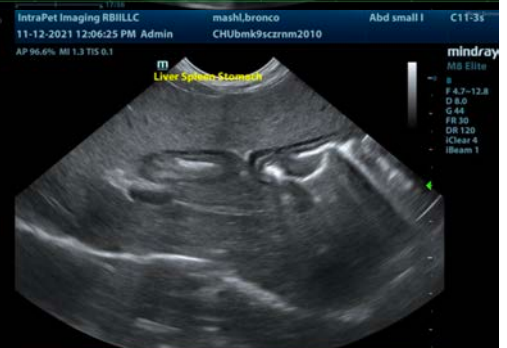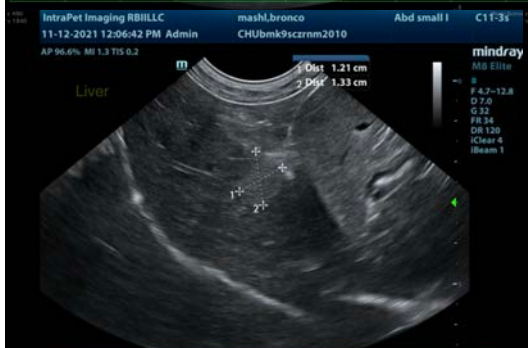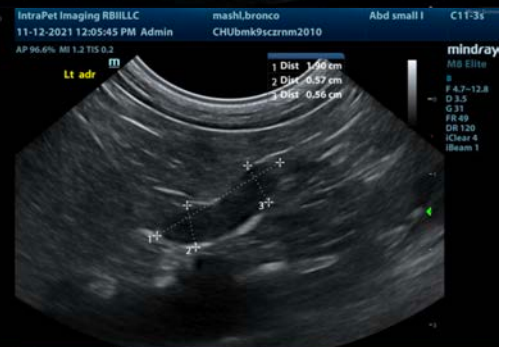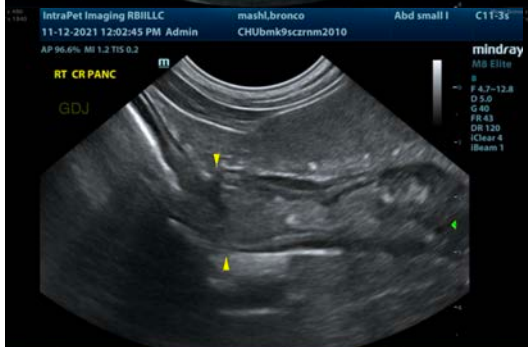
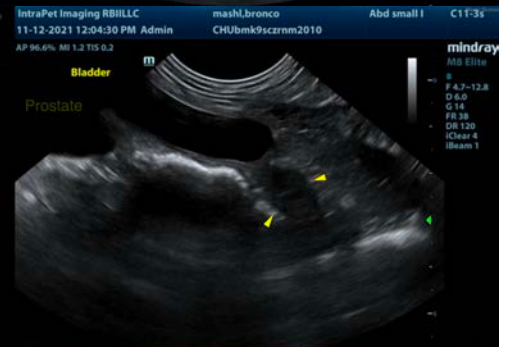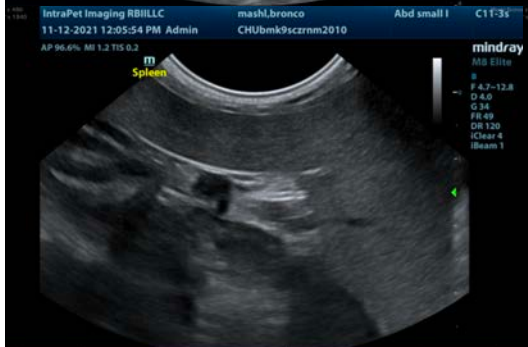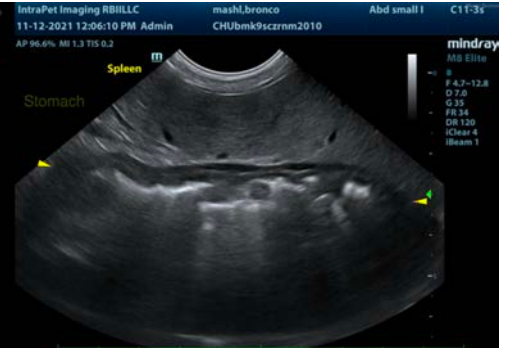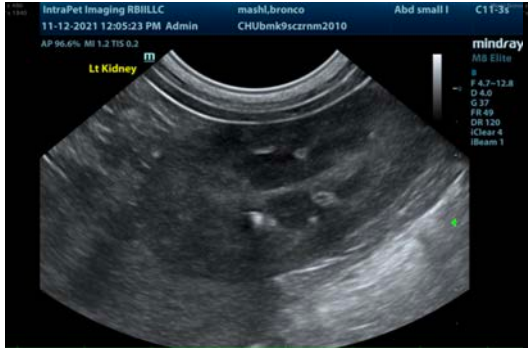## **ULTRASONOGRAPHIC FINDINGS**

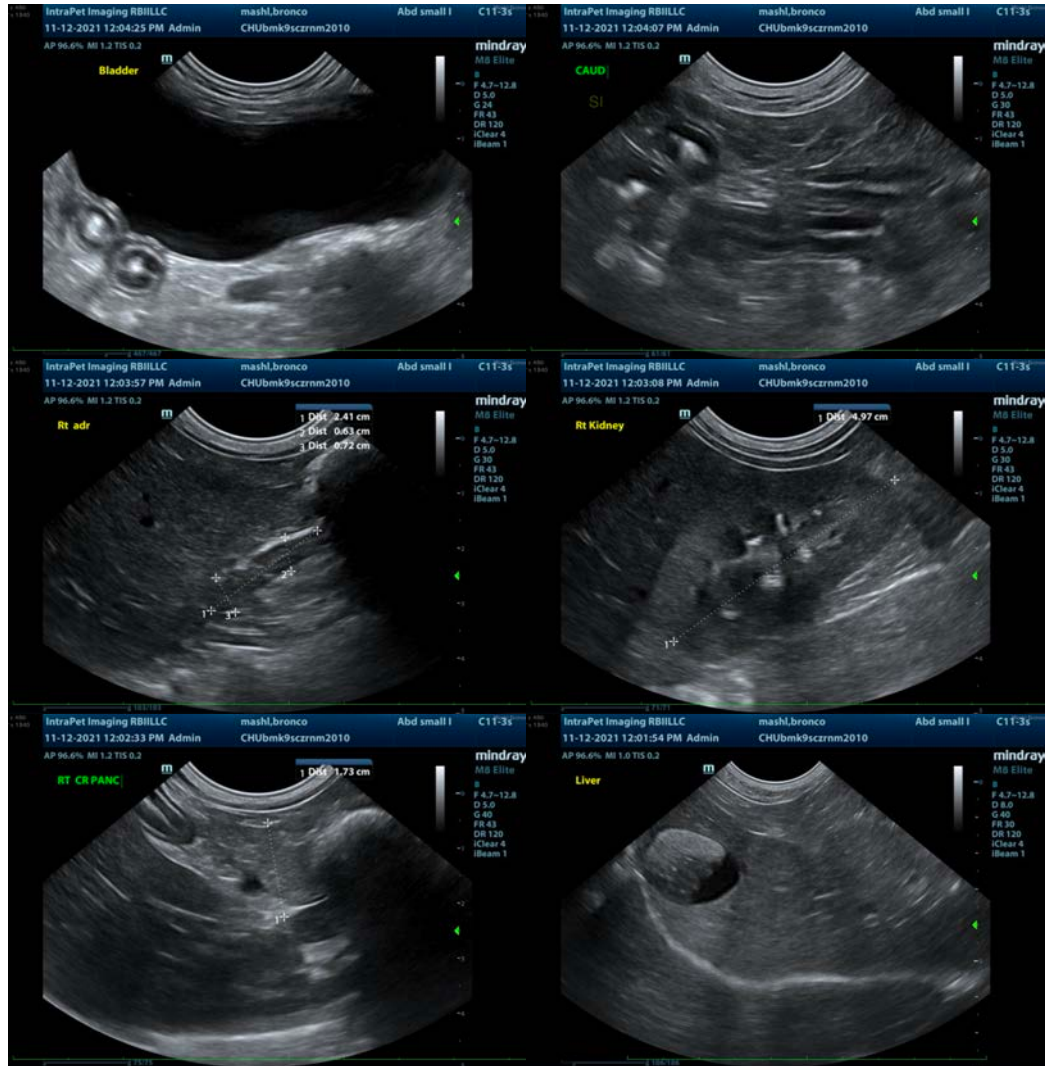
- The diffuse hepatic changes are non-specific and could be consistent with vacuolar hepatopathy, regenerative nodular hyperplasia, and/or age-related remodeling. Inflammatory and infiltrative disease are considered unlikely.
- Gallbladder sludge, non-mucocele
- The pancreatic changes are consistent with chronic active pancreatitis.
- Bilateral non-obstructive nephrolithiasis
- \*\*There is no evidence of inflammatory tissue surrounding the urinary bladder at the time of the study.

## **INTERPRETATION OF THE FINDINGS & FURTHER RECOMMENDATIONS**

Given the pancreatic changes and elevated lipase, a prescription low-fat diet is recommended as long-term maintenance to help prevent pancreatitis episodes.

Given the presence of a heart murmur, 3-view thoracic radiographs and echocardiogram, baseline blood pressure, +/- ECG should be considered.





The information and recommendations provided are based on the images presented by the referring veterinarian. No evaluation can be communicated regarding pathology that was not visible in the image/video clips provided.

Thank you for this referral. If the clinical or image interpretation does not parallel your findings or if I can be of any further assistance please contact me.

**Andrea Nicastro**, DVM, Diplomate DACVIM (Small Animal Internal Medicine)  
[info@SonoPath.com](mailto:info@SonoPath.com)