



PATIENT

Gracie Davies

SPECIES

Canine

BREED

Boykin Spaniel

SEX

Female Spayed

AGE

11/14/14

WEIGHT

35

INTERPRETED BY

Andrea Nicastro DVM
Diplomate ACVIM
(Sm Animal Internal Med)

**IMAGING
PERFORMED BY**

Andrea Nicastro DVM
Diplomate ACVIM
(Sm Animal Internal Med)

HOSPITAL NAME

Saddleback Mobile VC

REFERRING VET

Dr Russell Bauman

INVOICE

22242

DATE

11-10-25

PRESENTING CLINICAL SIGNS

Patient had a left medial liver lobectomy in June of 2025 for a liver mass. Biopsy results not available. Patient is doing fine. Recently had a skin mass removal of which biopsy results are pending. This is a follow-up to look for recurrence of the liver mass.

ULTRASONOGRAPHIC EXAMINATION OF THE ABDOMEN

Urinary System

The urinary bladder wall is normal in thickness. The mucosal surface is smooth. The bladder is moderately distended. Luminal contents are anechoic. No cystic calculi are observed. The region of the trigone and the proximal urethra, visible to a depth of 2 cm, are normal.

The left kidney is normal in size (5.80 cm in length) with a normal shape, architecture and smooth peripheral margins. There is a normal 1:3 cortex to medulla ratio with minimal loss of corticomedullary distinction. There is no evidence of pyelectasia, nephroliths, infarcts or hydronephrosis. Renal vasculature is normal.

The right kidney is normal in size (5.83 cm in length) with a normal shape, architecture and smooth peripheral margins. There is a normal 1:3 cortex to medulla ratio with minimal loss of corticomedullary distinction. There is no evidence of pyelectasia, nephroliths, infarcts or hydronephrosis. Renal vasculature is normal.

Adrenal Glands

The left adrenal gland is normal in size (0.47 cm at cranial pole) (0.54 cm at caudal pole) with a normal shape and homogenous parenchyma. The glandular echogenicity and detail are unremarkable. Capsule, cortex, and medullary definition are normal. The phrenicoabdominal vein and surrounding vasculature are normal.

The right adrenal gland is normal in size (0.91 cm at cranial pole) (0.51 cm at caudal pole) with a normal shape and homogenous parenchyma. The glandular echogenicity and detail are unremarkable. Capsule, cortex, and medullary definition are normal. The phrenicoabdominal vein and surrounding vasculature are normal.

Spleen

The spleen is normal in size (1.52 cm in width at the level of the hilus) with a normal capsular contour. There is appropriate echogenicity and echotexture. No focal lesions are observed. Splenic vasculature is normal.

Liver

The liver is subjectively normal in size with normal curvilinear peripheral contours. The parenchyma is hypoechoic relative to the spleen with minor changes consistent with age-related remodeling. No focal lesions are observed. Hepatic vasculature and biliary tracts are of normal volume with no evidence of congestion. The portal vein to caudal vena cava ratio is approximately 1: 1.

The gallbladder lumen is moderately distended. The wall is thin and smooth. A small amount of aggregated, echogenic to mineralized gravity-dependent d/sludge/sand is observed within the lumen. The cystic and common bile ducts are normal/not seen.

Gastrointestinal

The gastric lumen is minimally fluid-distended. The gastric wall and pylorus are normal in thickness with a normal layering pattern. The pyloric outflow tract is patent. The small intestinal lumen is not dilated. The small intestinal wall is normal in thickness with a normal layering pattern and appropriate mural detail. Discreet masses are not identified. The ileocecolic junction and colonic wall are normal. There is no evidence of an obstructive pattern.



PATIENT

Gracie Davies

Pancreas

The region of the pancreas is isoechoic relative to surrounding omental fat. No obvious parenchymal abnormalities are observed. There is no evidence of regional inflammation or effusion.

SPECIES

Canine

Lymph Nodes

The abdominal lymph nodes are normal/not visible.

BREED

Boykin Spaniel

Free Abdomen

The peritoneal cavity is normal. There is no evidence of inflammation or effusion.

SEX

Female Spayed

Other

A brief echocardiogram reveals no obvious evidence of right atrial or auricular mass. There is no obvious evidence of pericardial effusion.

ULTRASONOGRAPHIC FINDINGS

AGE

11/14/14

- The hepatic changes are consistent with age-related parenchymal remodeling and are not considered clinically significant at this time.
- Gallbladder debris/sand/sludge, non-mucocele

WEIGHT

35

*There is no obvious evidence of recurrence of the hepatic mass.

INTERPRETATION OF THE FINDINGS & FURTHER RECOMMENDATIONS

INTERPRETED BY

Andrea Nicastro DVM
 Diplomate ACVIM
 (Sm Animal Internal Med)

- Three-view thoracic radiographs are recommended to assess for pulmonary metastases.
- Consider a recheck ultrasound in 3-6 months to reassess for recurrence of the liver mass.

IMAGING PERFORMED BY

Andrea Nicastro DVM
 Diplomate ACVIM
 (Sm Animal Internal Med)

HOSPITAL NAME

Saddleback Mobile VC

REFERRING VET

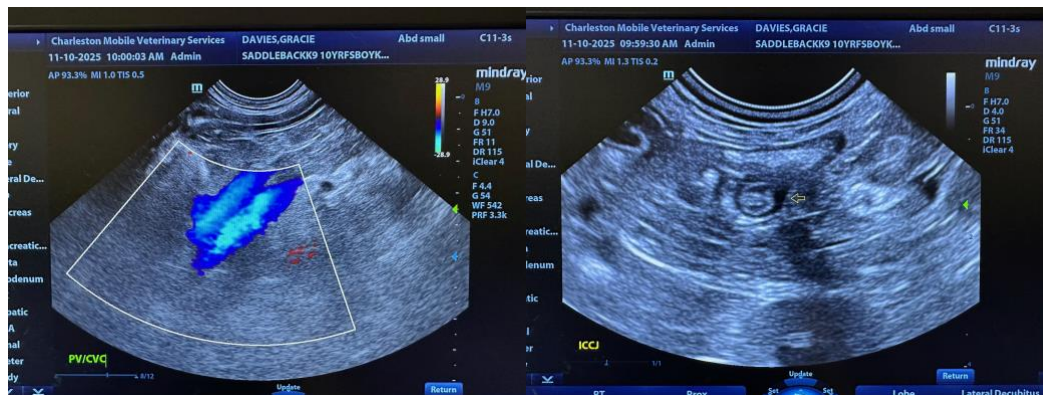
Dr Russell Bauman

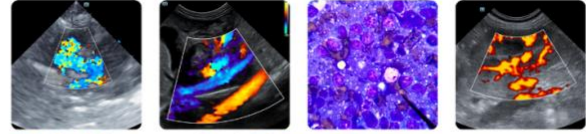
INVOICE

22242

DATE

11-10-25





PATIENT

Gracie Davies

SPECIES

Canine

BREED

Boykin Spaniel

SEX

Female Spayed

AGE

11/14/14

WEIGHT

35

INTERPRETED BY

Andrea Nicastrò DVM
 Diplomate ACVIM
 (Sm Animal Internal Med)

IMAGING PERFORMED BY

Andrea Nicastrò DVM
 Diplomate ACVIM
 (Sm Animal Internal Med)

HOSPITAL NAME

Saddleback Mobile VC

REFERRING VET

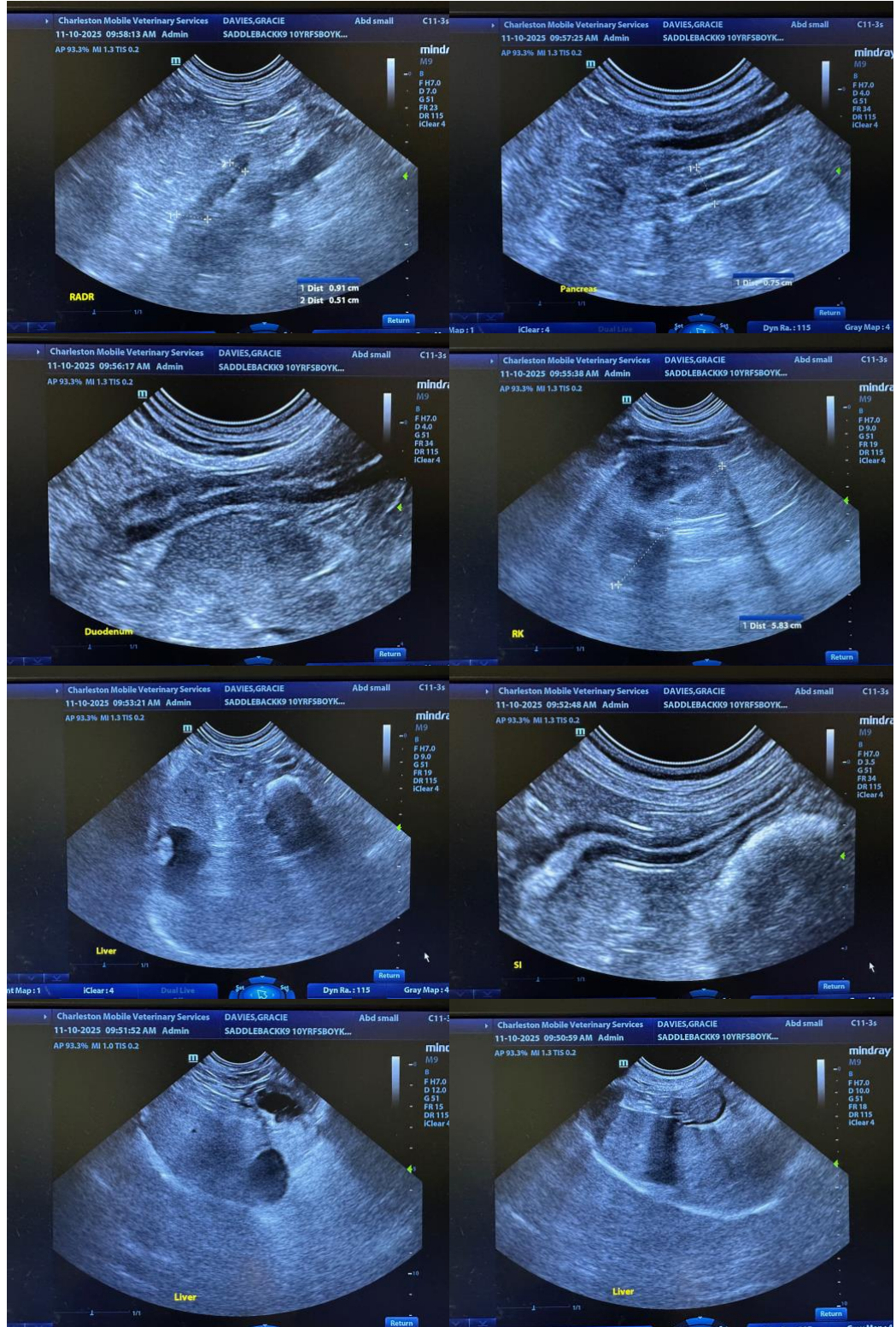
Dr Russell Bauman

INVOICE

22242

DATE

11-10-25





PATIENT

Gracie Davies

SPECIES

Canine

BREED

Boykin Spaniel

SEX

Female Spayed

AGE

11/14/14

WEIGHT

35

INTERPRETED BY

Andrea Nicastro DVM
 Diplomate ACVIM
 (Sm Animal Internal Med)

IMAGING PERFORMED BY

Andrea Nicastro DVM
 Diplomate ACVIM
 (Sm Animal Internal Med)

HOSPITAL NAME

Saddleback Mobile VC

REFERRING VET

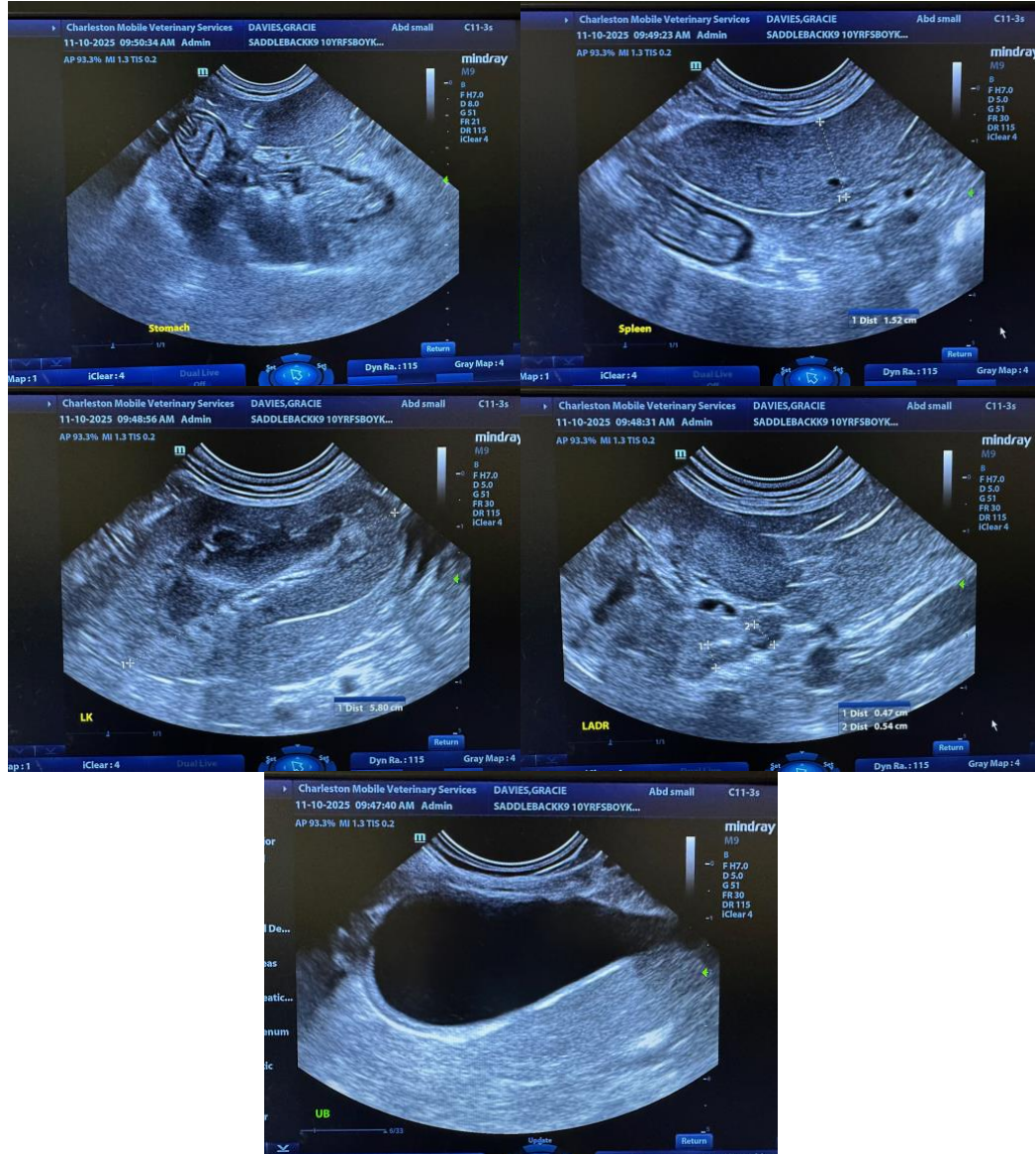
Dr Russell Bauman

INVOICE

22242

DATE

11-10-25



The information and recommendations provided are based on the images presented by the referring veterinarian/sonographer. No evaluation can be communicated regarding pathology that was not visible in the image/video clips provided.

Thank you for this referral. If the clinical or image interpretation does not parallel your findings or if I can be of any further assistance, please contact me.

Andrea Nicastro, MPH, DVM, Diplomate DACVIM (Small Animal Internal Medicine)
info@SonoPath.com