



**PATIENT PRESENTING CLINICAL SIGNS**

**Odin Kreff** History: Hx of chronic intermittent vomiting/poor appetite about twice/month. Gelatinous stools. Abnormal PE/Chem/CBC/UA Results: NSF on PE BW results: CBC: HCT (59%) Chem: UR

**SPECIES ULTRASONOGRAPHIC EXAMINATION OF THE ABDOMEN**

**Canine Urinary System**

The urinary bladder, trigone, and pelvic urethra are normal in thickness and the mucosal surface is smooth. The bladder lumen is moderately distended with anechoic urine. No masses, inflammatory changes or calculi are observed. Ureteral papillae and visualized portion of the proximal urethra, visible to a depth of 2-3 cm, are normal.

**BREED**

**Dachshund**

**SEX**

**Intact Male**

The prostate is enlarged (2.00 cm in width) with smooth peripheral contours. Parenchyma is mildly hyperechoic relative to surrounding omental fat and subtly heterogenous in appearance. A few, small, ill-defined cystic areas are visualized. The prostatic urethra is not overtly dilated.

**AGE**

**7 years**

The left kidney is normal size (5.31 cm in length); normal shape and smooth peripheral contours. The cortex is mildly thickened. There is mild to moderate loss of corticomedullary distinction. There is no evidence of pyelectasia, nephroliths, infarcts or hydronephrosis. Renal vasculature is normal.

**WEIGHT**

**19.7 lbs**

The right kidney is normal size (5.37 cm in length); with a normal shape, smooth peripheral margins, and normal internal architecture. There is mild to moderate loss of corticomedullary distinction. Several hyperechoic shadowing diverticular foci are observed. There is no evidence of pyelectasia, infarcts or hydronephrosis. Renal vasculature is normal.

**INTERPRETED BY**

Andrea Nicastro,  
DVM, Diplomate  
ACVIM (Small Animal  
Internal Medicine)

**IMAGING PERFORMED BY**

Jessica Bailes

**HOSPITAL NAME**

All Creatures Gr&Sm  
VC, Corvallis, OR

**REFERRING VET**

Dr. Beth Marszewski

**Adrenal Glands**

The left adrenal gland is normal size (0.40 cm at cranial pole) (0.49 cm at caudal pole) (1.84 cm in length); normal shape; homogenous parenchyma. The glandular echogenicity and detail are unremarkable. Capsule, cortex, and medullary definition are normal. The phrenicoabdominal vein and surrounding vasculature are normal.

The right adrenal gland is normal size (0.42 cm at cranial pole) (0.43cm at caudal pole) (1.74 cm in length); normal shape; homogenous parenchyma. The glandular echogenicity and detail are unremarkable. Capsule, cortex, and medullary definition are normal. The phrenicoabdominal vein and surrounding vasculature are normal.

**Spleen**

The spleen is normal in size (1.27 cm in width at the level of the hilus) with a normal capsular contour. There is appropriate echogenicity and echotexture. No focal lesions are observed. Splenic vasculature is normal.

**Liver**

The liver is subjectively normal in size with normal contours and structure. There is appropriate echogenicity and echotexture. No overt structural evidence of inflammatory, infiltrative or regenerative pathology is evident. Vascular and biliary tracts are of normal volume with no evidence of congestion. No pathological hepatic lymphadenopathy observed.

The gall bladder lumen is moderately distended. The wall is thin and smooth. Luminal contents are anechoic. The cystic and common bile ducts are normal/not seen.

**INVOICE**

11998

**DATE**

11.10.22

### ***Gastrointestinal***

The gastric lumen is not distended. The gastric wall is normal to borderline thickened (up to 0.84 cm) with retention of the normal layering pattern. The pyloric outflow tract appears patent. The small intestinal lumen is not dilated. The small intestinal wall is normal in with retention of the normal layering pattern. There is slight disruption in the normal 1:3 muscularis: mucosal ratio in some segments. Discreet masses are not identified. The colonic wall is normal. There is no evidence of an obstructive pattern.

### ***Pancreas***

The region of the pancreas is isoechoic relative to surrounding omental fat. No obvious parenchymal abnormalities are observed. There is no evidence of regional inflammation or effusion.

### ***Free Abdomen***

The peritoneal cavity is normal. There is no evidence of inflammation or effusion. A few prominent jejunal lymph nodes are visualized, the largest measuring 1.93 cm in length.

## **ULTRASONOGRAPHIC FINDINGS**

### **Primary Findings**

- The small intestinal wall changes are suggestive of inflammatory bowel disease. There is some potential for emerging lymphoma. However, neoplasia is considered less likely at this time.
- The lymph node changes are most consistent with reactive lymphadenitis or lymphoid hyperplasia.

### **Secondary Findings**

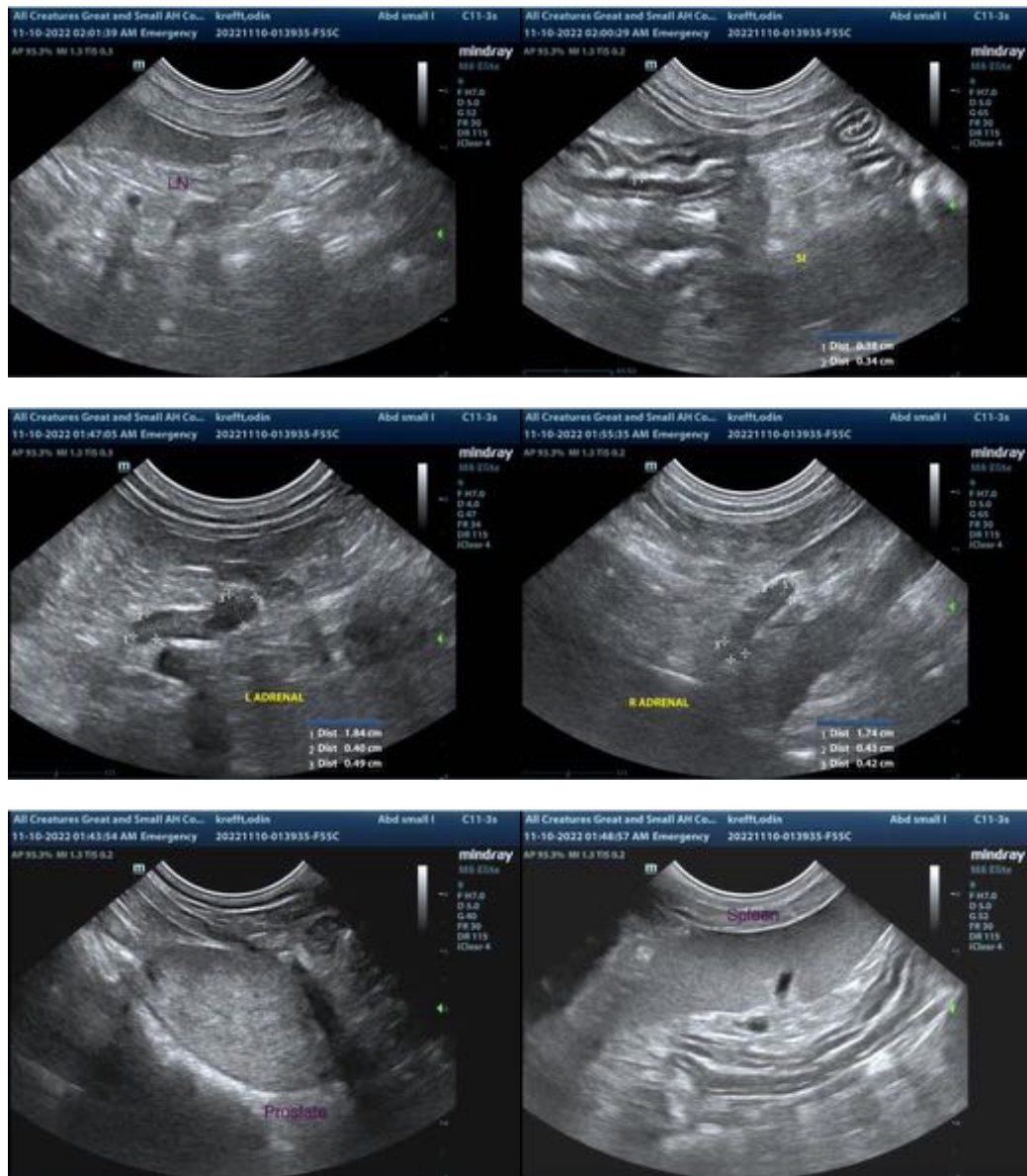
- Bilateral chronic age-related renal changes
- The prostate changes are most consistent with benign prostatic hyperplasia. Bacterial prostatitis is also a differential but considered unlikely in the absence of lower urinary tract signs.

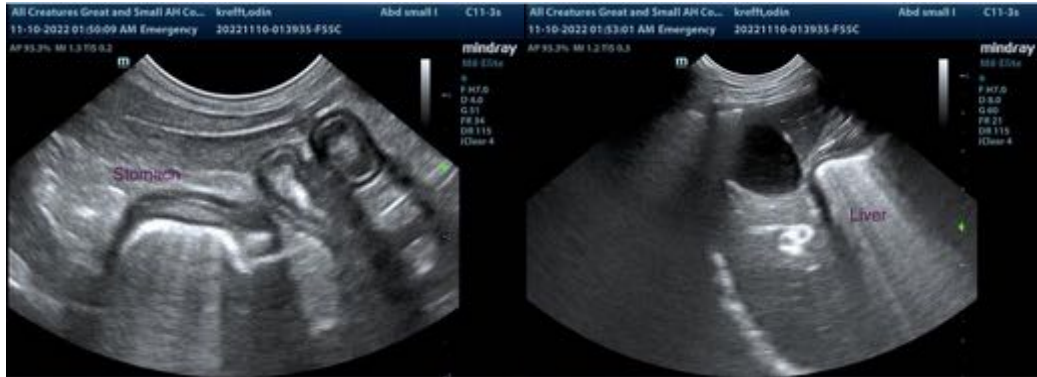## **INTERPRETATION OF THE FINDINGS & FURTHER RECOMMENDATIONS**

The following diagnostics/treatment recommendations can be considered:

1. Serum cobalamin, folate, PLI and TLI
2. A fecal evaluation for ova/Giardia
3. Prophylactic deworming with Fenbendazole at 50 mg/kg once a day for 5 days is recommended. Repeat above protocol in 3 weeks.
4. A 6-week limited antigen or hydrolyzed protein diet trial to assess for food allergies.
5. Consider a 4-week course of Tylosin at 15-20 mg/kg by mouth every 12 hours as empirical treatment for small intestinal bacterial overgrowth.
6. Also consider initiation of a probiotic as well as a fiber supplement (i.e., Metamusil or Konsyl).
7. A resting cortisol level to screen for hypoadrenocorticism. If resting cortisol level is < 2.0 mcg/dL, an ACTH stimulation test is recommended.

8. Depending on the results of the above diagnostics/therapeutics, endoscopic or surgical gastrointestinal biopsies may be warranted. Three-view thoracic radiographs should be performed prior to any anesthetic event.





The information and recommendations provided are based on the images presented by the referring veterinarian/sonographer. No evaluation can be communicated regarding pathology that was not visible in the image/video clips provided.

Thank you for this referral. If the clinical or image interpretation does not parallel your findings or if I can be of any further assistance, please contact me.

**Andrea Nicastro, MPH, DVM, Diplomate DACVIM (Small Animal Internal Medicine)**  
[info@SonoPath.com](mailto:info@SonoPath.com)