

PATIENT

Sharik Sagatelyn

SPECIES

Canine

BREED

Austr Kelpie

SEX

Spayed Female

AGE

9 years, 11 mos

WEIGHT

39 lbs

INTERPRETED BY

Andrea Nicastro,
DVM, Diplomate
ACVIM (Small Animal
Internal Medicine)

IMAGING PERFORMED BY

Loetitia Saint-Jacques,
RVT LVT

HOSPITAL NAME

Pine Creek VC

REFERRING VET

Dr Denny Nolet

INVOICE

11785

DATE

10.6.22

PRESENTING CLINICAL SIGNS

History: On Proin 25 mg (1T PO BID) and prevention (Trifexis). On drop off form O mentioned increase water but normal appetite. AUS to look at liver- has been on Denamarin for one month after liver labs- Sedation dex/torb- Has been on Carprofen since Feb for limping

Abnormal PE/Chem/CBC/UA Results: CBC - WBC count of 8,900 with 6,675 neutrophils; HCT 58%; PLT count of 426,000 Chem - TP 7.5 with 4.4 albumin; ALT 168; ALP 374 (r/o vacuolar hepatopathy; chronic active hepatitis; cholangiohepatitis, neoplasia, HAC, other); BUN 16; Creat 0.9; SDMA 8.1; Remainder unremarkable T4 - 1.4

ULTRASONOGRAPHIC EXAMINATION OF THE ABDOMEN

Urinary System

The **urinary bladder** wall is normal in thickness and the mucosal surface is smooth. The bladder lumen is moderately distended with anechoic urine. No masses, inflammatory changes or calculi are observed. The region of the trigone and the visible portion of the proximal urethra are normal.

The **left kidney** is normal size (6.19 cm in length); normal shape and architecture with smooth peripheral margins. There is a normal 1:3 cortex to medulla ratio with mild loss of corticomedullary distinction. There is no evidence of pyelectasia, nephroliths, infarcts or hydroureter.

The **right kidney** is normal size (6.05 cm in length); normal shape and architecture with smooth peripheral margins. There is a normal 1:3 cortex to medulla ratio with normal corticomedullary distinction. There is no evidence of pyelectasia, nephroliths, infarcts or hydroureter. Renal vasculature is normal.

Adrenal Glands

The **left adrenal gland** is borderline enlarged (0.82 cm at cranial pole) (0.81 cm at caudal pole); normal shape; homogenous parenchyma. The glandular echogenicity and detail are unremarkable. Capsule, cortex, and medullary definition are normal. The phrenicoabdominal vein and surrounding vasculature are normal.

The **right adrenal gland** is borderline enlarged (0.98 cm at cranial pole) (0.80 cm at caudal pole); normal shape; homogenous parenchyma. The glandular echogenicity and detail are unremarkable. Capsule, cortex, and medullary definition are normal. The phrenicoabdominal vein and surrounding vasculature are normal.

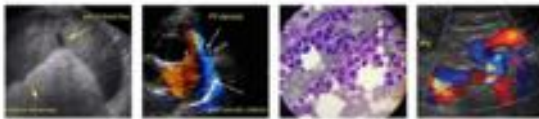
Spleen

The **spleen** is normal in size (1.85 cm in width at the level of the hilus) with a normal capsular contour. There is appropriate echogenicity and echotexture. A pinpoint hyperechoic focus is observed at the caudolateral aspect. Splenic vasculature is normal.

Liver

The **liver** is subjectively prominent in size with slightly swollen peripheral contours. The parenchyma is isoechoic relative to the spleen. A 3.31 x 2.46 cm irregular hypoechoic nodule/mass is observed deep on the left side. The remaining parenchyma is slightly mottled in appearance, particularly on the left side. Hepatic vasculature and intrahepatic biliary tracts are of normal volume with no evidence of congestion.

The **gall bladder** lumen is moderately distended. The wall is thin and smooth. Luminal contents are anechoic. The cystic and common bile ducts are normal/not seen.



PATIENT

Sharik Sagatelyn

SPECIES

Canine

BREED

Austr Kelpie

SEX

Spayed Female

AGE

9 years, 11 mos

WEIGHT

39 lbs

INTERPRETED BY

Andrea Nicastro,
DVM, Diplomate
ACVIM (Small Animal
Internal Medicine)

IMAGING PERFORMED BY

Loetitia Saint-Jacques,
RVT LVT

HOSPITAL NAME

Pine Creek VC

REFERRING VET

Dr Denny Nolet

INVOICE

11785

DATE

10.6.22

Gastrointestinal

The **gastric lumen** is not distended. The gastric wall and pylorus are normal in thickness with a normal layering pattern. The pyloric outflow tract is patent. In the early part of the study, an approximately 1.50 cm segment of jejunum was dilated with an area of soft, shadowing material. Oral and aboral to this region, the small intestinal lumen is empty. At the end of the study, this lesion was no longer visualized. The small intestinal wall is normal in thickness with a normal layering pattern and appropriate mural detail. The ileoceocolic junction and colonic wall are normal. There is no evidence of an obstructive pattern.

Pancreas

The region of the **pancreas** is isoechoic relative to surrounding omental fat. No obvious parenchymal abnormalities are observed. There is no evidence of regional inflammation or effusion.

Free Abdomen

The **peritoneal cavity** is normal. There is no evidence of inflammation or effusion. The abdominal **lymph nodes** are normal/not visible.

Other

A **brief echocardiogram** reveals no evidence of pericardial effusion or obvious right atrial/auricular mass.

ULTRASONOGRAPHIC FINDINGS

Primary Findings

- The left hepatic nodule/mass could be consistent with a large regenerative nodule. Alternatively, neoplasia (i.e., adenoma, adenocarcinoma) may be present. The diffuse hepatic parenchymal changes trend toward the benign (i.e., vacuolar hepatopathy and/or regenerative nodular hyperplasia).

Secondary Findings

- The transient focal jejunal dilation with soft shadowing within the lumen may represent transient, nonobstructive foreign material (i.e., grass).
- Mild bilateral, chronic, age-related renal changes
- Borderline bilateral adrenomegaly

INTERPRETATION OF THE FINDINGS & FURTHER RECOMMENDATIONS

A urinalysis is recommended to evaluate for isosthenuria. If present, consider further testing for Cushing's disease (i.e., low-dose dexamethasone suppression test or ACTH stimulation test).

Regarding the hepatic lesion, consider a fine-needle aspirate, if clotting status is appropriate. A 25-gauge needle should be used. If cytology results are inconclusive, surgical biopsies can be considered. Alternatively, a repeat ultrasound should be considered in 4-6 weeks to assess for progression (or sooner if gastrointestinal signs develop).

Regarding the focal jejunal dilation, consider a repeat ultrasound if the patient develops GI signs.



PATIENT

Sharik Sagatelyn

SPECIES

Canine

BREED

Austr Kelpie

SEX

Spayed Female

AGE

9 years, 11 mos

WEIGHT

39 lbs

INTERPRETED BY

Andrea Nicastro,
DVM, Diplomate
ACVIM (Small Animal
Internal Medicine)

**IMAGING
PERFORMED BY**

Loetitia Saint-Jacques,
RVT LVT

HOSPITAL NAME

Pine Creek VC

REFERRING VET

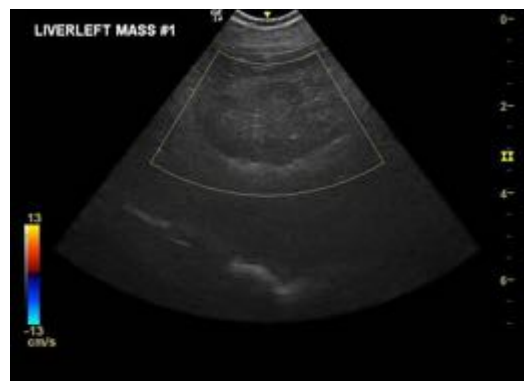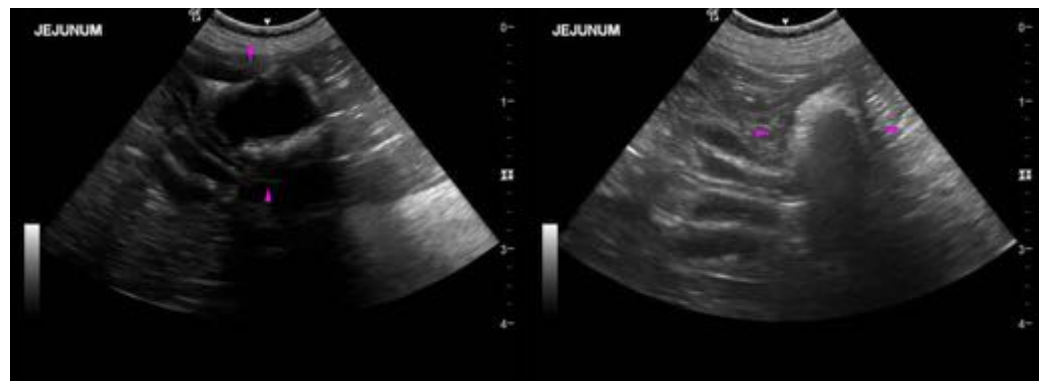
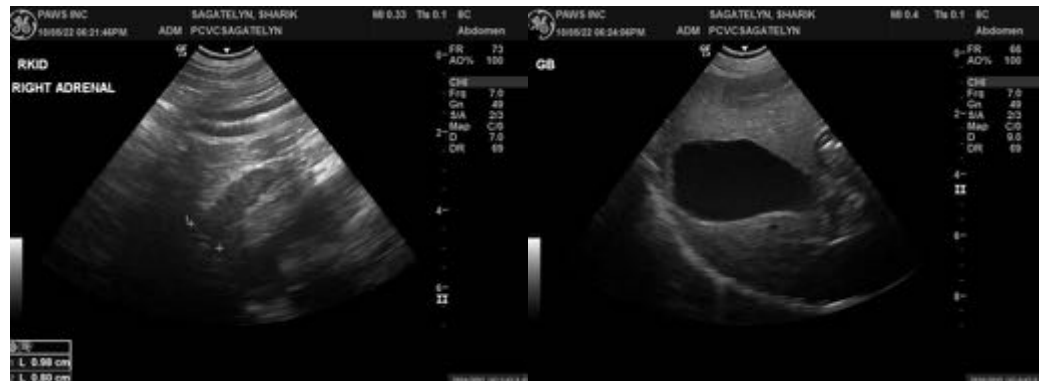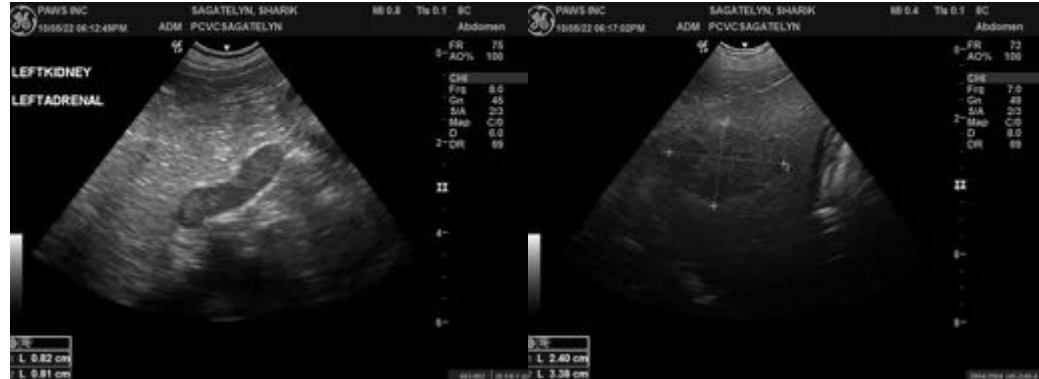
Dr Denny Nolet

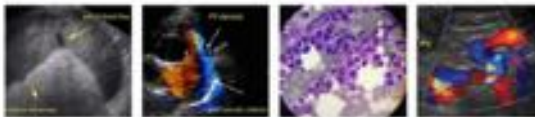
INVOICE

11785

DATE

10.6.22





PATIENT

Sharik Sagatelyn

The information and recommendations provided are based on the images presented by the referring veterinarian/sonographer. No evaluation can be communicated regarding pathology that was not visible in the image/video clips provided.

SPECIES

Canine

Thank you for this referral. If the clinical or image interpretation does not parallel your findings or if I can be of any further assistance, please contact me.

BREED

Austr Kelpie

Andrea Nicastro, MPH, DVM, Diplomate DACVIM (Small Animal Internal Medicine)
info@SonoPath.com

SEX

Spayed Female

AGE

9 years, 11 mos

WEIGHT

39 lbs

INTERPRETED BY

Andrea Nicastro,
DVM, Diplomate
ACVIM (Small Animal
Internal Medicine)

IMAGING PERFORMED BY

Loetitia Saint-Jacques,
RVT LVT

HOSPITAL NAME

Pine Creek VC

REFERRING VET

Dr Denny Nolet

INVOICE

11785

DATE

10.6.22