



**PATIENT**

Moe Wolff

**PRESENTING CLINICAL SIGNS**

History: Anorexia, ADR, lethargic. Gastroenteropathy and decreased serosal detail on rad.  
Abnormal PE/Chem/CBC/UA Results: Elevated neuts, decreased phos. FPL neg. USG 1.050, proteinuria.

**SPECIES**

Feline

**ULTRASONOGRAPHIC EXAMINATION OF THE ABDOMEN**

*Urinary System*

The urinary bladder, trigone, and pelvic urethra are normal in thickness and the mucosal surface is smooth. The bladder lumen is distended. A small to moderate amount of suspended echogenic debris is observed within the lumen. No masses, inflammatory changes or calculi are observed. Ureteral papillae and visualized portion of the proximal urethra, visible to a depth of 2 cm, are normal.

**BREED**

Domestic shorthair

**SEX**

Male, neutered

The left kidney is normal size (4.62 cm in length); normal shape and architecture with smooth peripheral margins. There is a normal 1:3 cortex to medulla ratio with normal corticomedullary distinction. There is no evidence of pyelectasia, nephroliths, infarcts or hydronephrosis. Renal vasculature is normal.

**AGE**

10 Yrs.

The right kidney is normal size (4.69 cm in length); normal shape and architecture with smooth peripheral margins. There is a normal 1:3 cortex to medulla ratio with minimal to mild loss of corticomedullary distinction. There is no evidence of pyelectasia, nephroliths, infarcts or hydronephrosis. Renal vasculature is normal.

**WEIGHT**

12.4 lbs.

*Adrenal Glands*

The left adrenal gland is mildly enlarged (0.58 cm width). Normal shape and glandular echogenicity. The phrenicoabdominal vein and surrounding vasculature are normal.

**INTERPRETED BY**

Andrea Nicastro, DVM,  
Diplomate ACVIM  
(Small Animal Internal  
Medicine)

The right adrenal gland is normal in size (0.43 cm width). Normal shape and glandular echogenicity. The phrenicoabdominal vein and surrounding vasculature are normal.

*Spleen*

The spleen is subjectively prominent in size (0.99 cm in width at the level of the hilus) with slight scalloping of the medial contour. Using the high frequency probe, the parenchyma appears slightly mottled. No focal lesions are observed. Splenic vasculature is normal.

**IMAGING PERFORMED BY**

Shari Reffi CVT

*Liver*

The liver is subjectively normal in size with normal contours and structure. There is appropriate echogenicity and echotexture. No overt structural evidence of inflammatory, infiltrative or regenerative pathology is evident. Vascular and biliary tracts are of normal volume with no evidence of congestion. No pathological hepatic lymphadenopathy observed. The gall bladder lumen is moderately distended. The wall is thin and smooth. A small amount of aggregated echogenic mostly gravity-dependent debris is observed within the lumen. The cystic and common bile ducts are normal.

**HOSPITAL NAME**

Newton VH

**REFERRING VET**

Dr. Barron

*Gastrointestinal*

The stomach and intestine are free of stasis and exhibit normal peristaltic activity. The gastric lumen is not distended. The gastric wall and pylorus are normal in thickness with a normal layering pattern. The pyloric outflow tract is patent. The small intestinal lumen is not dilated. A mass effect is infiltrating a >5 cm segment of small intestine. The wall within this region is severely thickened (up to 1.02 cm), irregular and hypoechoic with a loss of the normal layering pattern. The mesentery and regional lymph nodes are adhered to this segment of bowel. In the remaining small intestinal segments, the wall is normal to mildly

**INVOICE**

12298

**DATE**

10/6/21



**PATIENT**

Moe Wolff

thickened (up to 0.32 cm) with a normal layering pattern. There is slight disruption in the normal 1:3 muscularis: mucosal ratio in some segments. The ileocecal colic junction and colonic wall are normal. No obstructive disease is noted.

**SPECIES**

Feline

**Pancreas**

A portion of the pancreas is obscured by the bowel pathology. In the visualized portion, no obvious abnormalities are seen.

**BREED**

Domestic shorthair

**Free Abdomen**

The mesentery throughout the cranial and mid-abdomen is hyperechoic. Trace free fluid is observed. Several enlarged, hypoechoic irregular clustered lymph nodes are adhered to the small intestinal mass. Surrounding mesentery is hyperechoic. A few additional prominent lymph nodes are observed in the mid to cranial abdomen.

**SEX**

Male, neutered

**AGE**

10 Yrs.

**ULTRASONOGRAPHIC FINDINGS**

**Primary Findings:**

- Small intestinal mass effect with regional peritonitis. Neoplasia (i.e., round cell tumor, adenocarcinoma) is considered likely with a lower possibility of a severe inflammatory process (i.e., pyogranulomatous). The remaining bowel pattern is consistent with inflammatory bowel disease or emerging lymphoma. The regional lymphadenopathy consistent with infiltrative neoplasia, reactive lymphadenitis, or lymphoid hyperplasia.

**Secondary Findings:**

- The splenic changes could be consistent with benign pathology (i.e., extramedullary hematopoiesis or lymphoid hyperplasia). Alternatively, infiltrative neoplasia (i.e., round cell tumor) is possible. Benign pathology is favored.
- Bilateral age-related renal changes.
- Urinary bladder debris.
- The mild left adrenomegaly may be secondary to hyperplasia, stress, or less likely, an early neoplastic process.

**INTERPRETED BY**

Andrea Nicastro, DVM,  
Diplomate ACVIM  
(Small Animal Internal  
Medicine)

**IMAGING PERFORMED BY**

Shari Reffi CVT

**HOSPITAL NAME**

Newton VH

**INTERPRETATION OF THE FINDINGS & FURTHER RECOMMENDATIONS**

- Three-view thoracic radiographs are recommended to assess for pulmonary metastases.
- Fine needle aspirates of the bowel mass and/or enlarged abdominal lymph nodes are recommended (if clotting status is appropriate). 25-gauge needles should be used. If cytologic evaluations are inconclusive, surgical biopsies may be necessary to get a definitive diagnosis.
- A GI panel should also be considered.

**REFERRING VET**

Dr. Barron

**INVOICE**

12298

**DATE**

10/6/21



**PATIENT**

Moe Wolff

**SPECIES**

Feline

**BREED**

Domestic shorthair

**SEX**

Male, neutered

**AGE**

10 Yrs.

**WEIGHT**

12.4 lbs.

**INTERPRETED BY**

Andrea Nicastro, DVM,  
Diplomate ACVIM  
(Small Animal Internal  
Medicine)

**IMAGING  
PERFORMED BY**

Shari Reffi CVT

**HOSPITAL NAME**

Newton VH

**REFERRING VET**

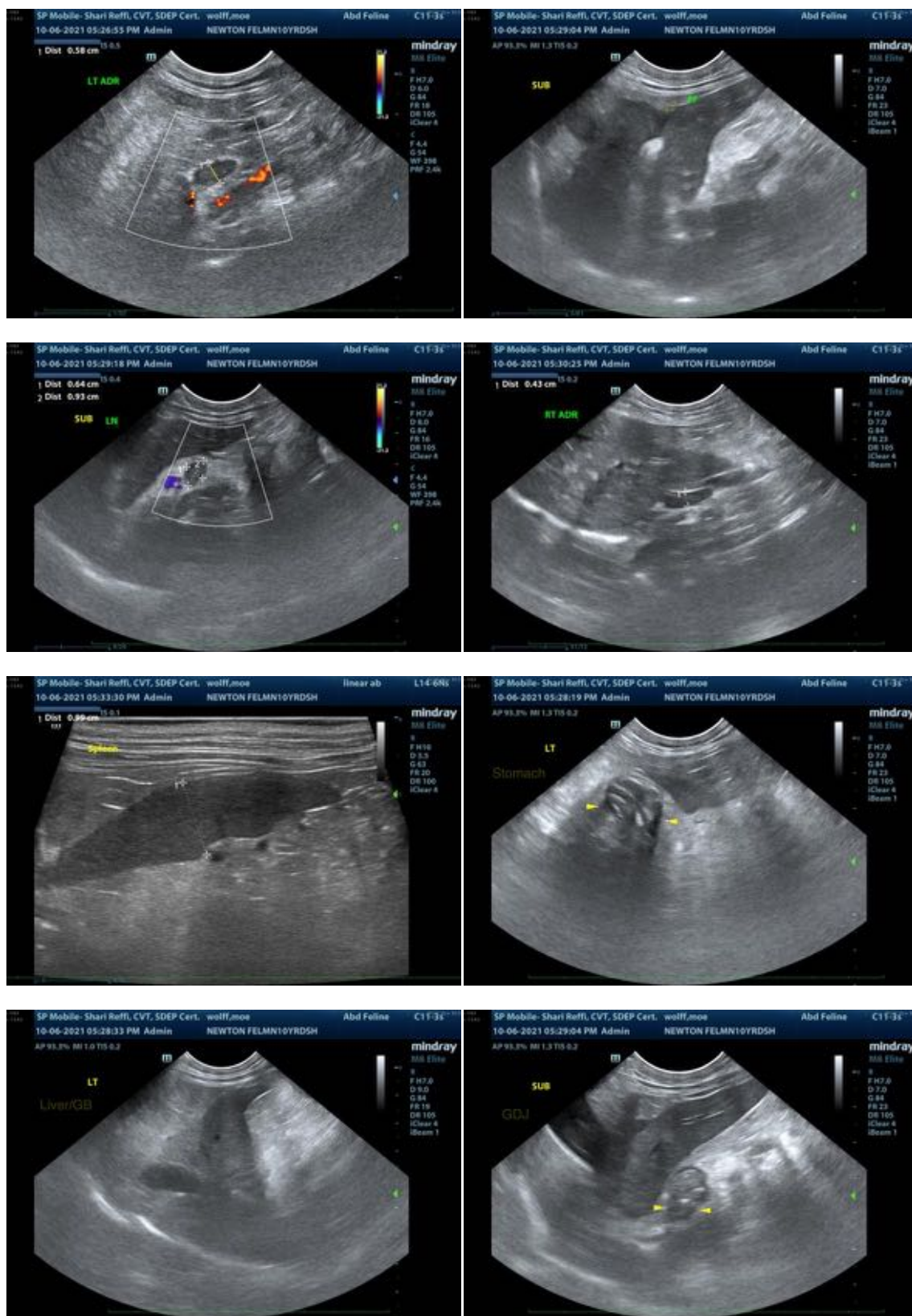
Dr. Barron

**INVOICE**

12298

**DATE**

10/6/21





**PATIENT**

Moe Wolff

**SPECIES**

Feline

**BREED**

Domestic shorthair

**SEX**

Male, neutered

**AGE**

10 Yrs.

**WEIGHT**

12.4 lbs.

**INTERPRETED BY**

Andrea Nicastro, DVM,  
Diplomate ACVIM  
(Small Animal Internal  
Medicine)

**IMAGING  
PERFORMED BY**

Shari Reffi CVT

**HOSPITAL NAME**

Newton VH

**REFERRING VET**

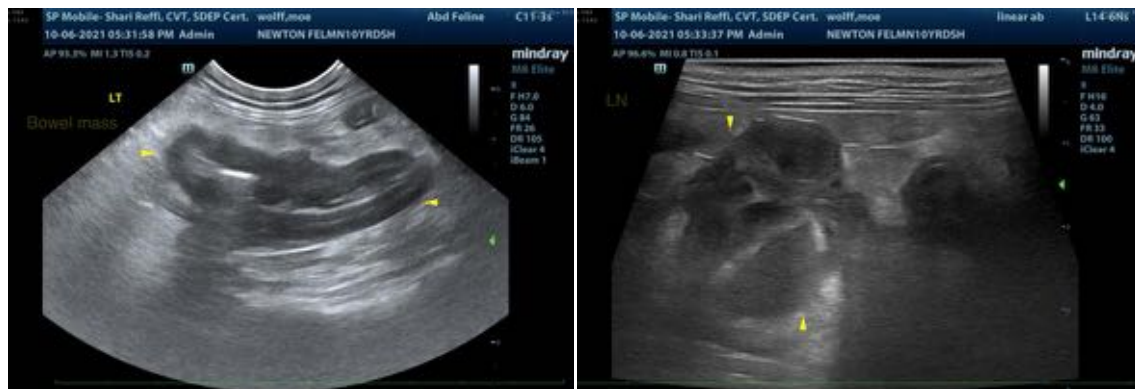
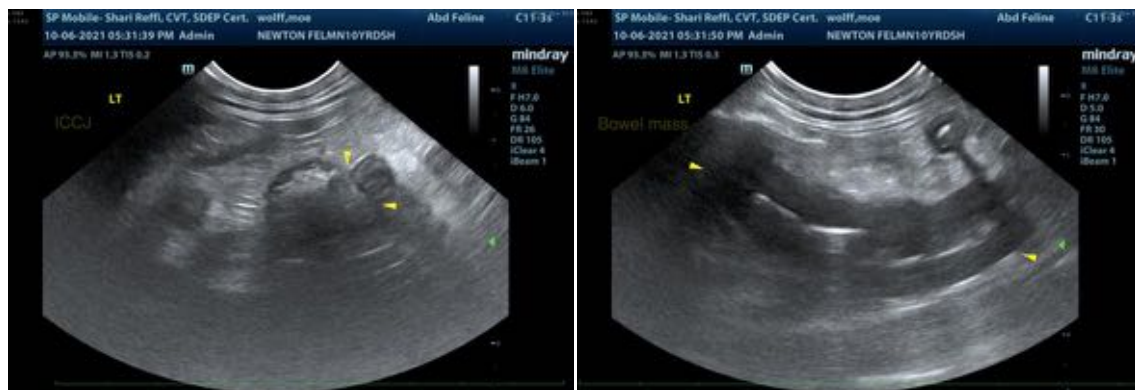
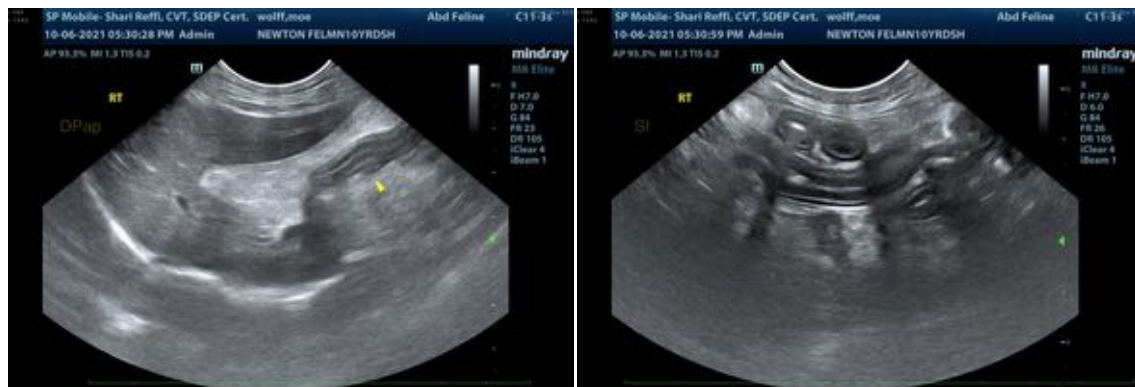
Dr. Barron

**INVOICE**

12298

**DATE**

10/6/21



The information and recommendations provided are based on the images presented by the referring veterinarian. No evaluation can be communicated regarding pathology that was not visible in the image/video clips provided.

Thank you for this referral. If the clinical or image interpretation does not parallel your findings or if I can be of any further assistance please contact me.

Andrea Nicastro, DVM, Diplomate ACVIM (Small Animal Internal Medicine)

Andrea.nicastro@sonopath.com