



PATIENT

Mauler Koch

SPECIES

Feline

BREED

Domestic shorthair

SEX

Male, neutered

AGE

4 Yrs.

WEIGHT

9.1 lbs.

INTERPRETED BY

Andrea Nicastro, DVM,
Diplomate ACVIM
(Small Animal Internal
Medicine)

**IMAGING
PERFORMED BY**

Dr. Saum Hadi

HOSPITAL NAME

Bethany Family Pet
Clinic

REFERRING VET

Dr. Saum Hadi

INVOICE

14059

DATE

10/4/22

PRESENTING CLINICAL SIGNS

History: P presented for weight loss and hyporexia. Weight down from 10.56 to 9.1 lbs in 2 months. Lab work revealed azotemia and non-concentrated urine. Following ultrasound that showed renal change, x-rays were taken and were suspicious for nephro + ureterolithiasis. Urine culture pending. Abnormal PE/Chem/CBC/UA Results: SDMA: 23.9 ug/dL Creatinine: 3.0 mg/dL BUN: 37 mg/dL USG: 1.023 Rest WNL

ULTRASONOGRAPHIC EXAMINATION OF THE ABDOMEN

Urinary System

The urinary bladder wall is normal in thickness and the mucosal surface is smooth. The bladder lumen is mildly distended with anechoic urine. No masses, inflammatory changes or calculi are observed. The region of the trigone and the visible portion of the proximal urethra are normal.

The left kidney is normal size (3.30 cm in length); normal shape and architecture with smooth peripheral margins. There is a normal 1:3 cortex to medulla ratio with mild loss of corticomedullary distinction. A cortical infarct is observed at the craniomedial aspect. Small non-obstructive foci of mineralization are visualized. Trace pyelectasia is present. There is no evidence of hydroureter.

The right kidney is normal size (3.87 cm in length) with a normal shape and smooth peripheral contours. There is a normal 1:3 cortex to medulla ratio with mild loss of corticomedullary distinction. Hydronephrosis is present (1.28 cm in the longitudinal plane). Echogenic material is suspended within the renal pelvis. There is no obvious evidence of nephroliths within the kidney. The right ureter is dilated (up to 0.224 cm). Within the proximal ureter, a 0.17 cm ureterolith is visualized. Distal to this stone, pinpoint foci of mineralization are seen within the ureteral lumen.

Adrenal Glands

The region of the adrenal glands is evaluated. No obvious pathology is seen.

Spleen

The spleen is normal in size (0.53 cm in width at the level of the hilus) with a normal capsular contour. There is appropriate echogenicity and echotexture. No focal lesions are observed. Splenic vasculature is normal.

Liver

The liver is subjectively normal in size with normal curvilinear peripheral contours. The parenchyma is hypoechoic relative to the spleen and relatively homogeneous in appearance. There is an increase in portal markings. Vascular and biliary tracts are of normal volume with no evidence of congestion. The gall bladder lumen is mildly distended. The wall is slightly thickened (up to 0.17 cm) and hyperechoic. Luminal contents are anechoic. The cystic and common bile ducts are normal/not seen.

Gastrointestinal

The gastric lumen is not distended. The gastric wall is normal in thickness with a normal layering pattern. The small intestinal lumen is segmentally dilated with chyme. The small intestinal wall thickness is normal with a normal layering pattern and appropriate mural detail. Discreet masses are not identified. The ileoceocolic junction and colonic wall are normal. No obstructive disease is noted.



PATIENT

Pancreas

Mauler Koch

The region of the pancreas is isoechoic relative to surrounding omental fat. No obvious parenchymal abnormalities are observed. There is no evidence of regional inflammation or effusion.

SPECIES

Feline

Free Abdomen

The peritoneal cavity is normal. There is no evidence of inflammation or effusion. The abdominal lymph nodes are normal/not visible.

BREED

Domestic shorthair

SEX

Male, neutered

Primary Findings:

- Right hydronephrosis/hydroureter with multiple ureteroliths. There is evidence of chronic renal changes in both kidneys with non-obstructive mineralizations and a cortical infarct in the left kidney.

AGE

4 Yrs.

Secondary Findings:

- The gallbladder wall changes may be artifactual due to lack of full repletion and may be secondary to cholecystitis. Correlation with the patient's clinical history is recommended.
- The increase in portal markings may be a normal variant for this patient or may be secondary to an inflammatory hepatopathy.

WEIGHT

9.1 lbs.

INTERPRETED BY

Andrea Nicastro, DVM,
Diplomate ACVIM
(Small Animal Internal
Medicine)

INTERPRETATION OF THE FINDINGS & FURTHER RECOMMENDATIONS

- Urine culture and sensitivity.
- IV fluid diuresis is recommended along with initiation of broad spectrum antibiotics (while awaiting urine culture and sensitivity results). If the ureteroliths do not pass into the urinary bladder, referral to a board certified surgeon for ureteral stenting or subcutaneous ureteral bypass may be warranted.

IMAGING PERFORMED BY

Dr. Saum Hadi

HOSPITAL NAME

Bethany Family Pet
Clinic

REFERRING VET

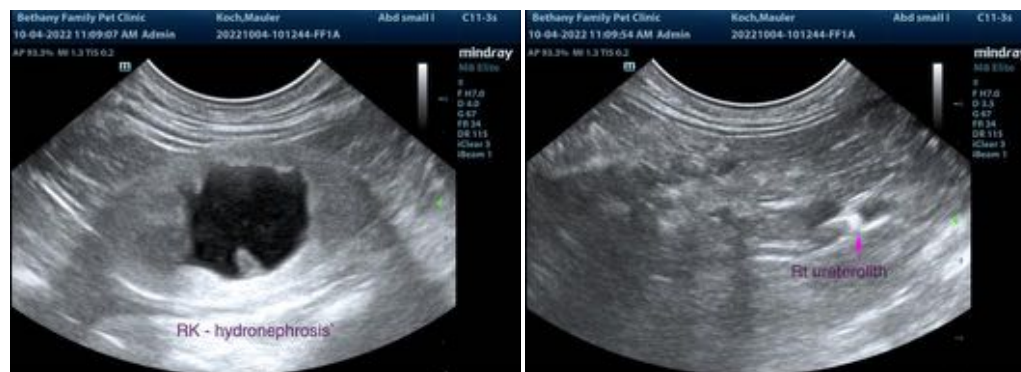
Dr. Saum Hadi

INVOICE

14059

DATE

10/4/22





PATIENT

Mauler Koch

SPECIES

Feline

BREED

Domestic shorthair

SEX

Male, neutered

AGE

4 Yrs.

WEIGHT

9.1 lbs.

INTERPRETED BY

Andrea Nicastro, DVM,
Diplomate ACVIM
(Small Animal Internal
Medicine)

**IMAGING
PERFORMED BY**

Dr. Saum Hadi

HOSPITAL NAME

Bethany Family Pet
Clinic

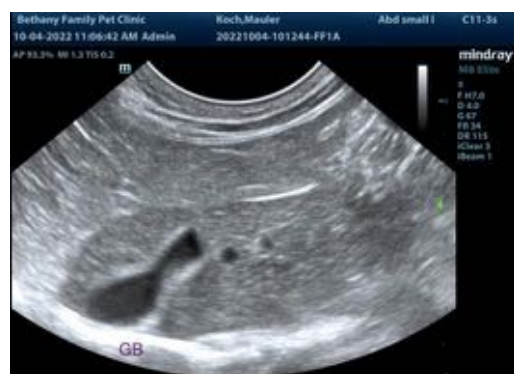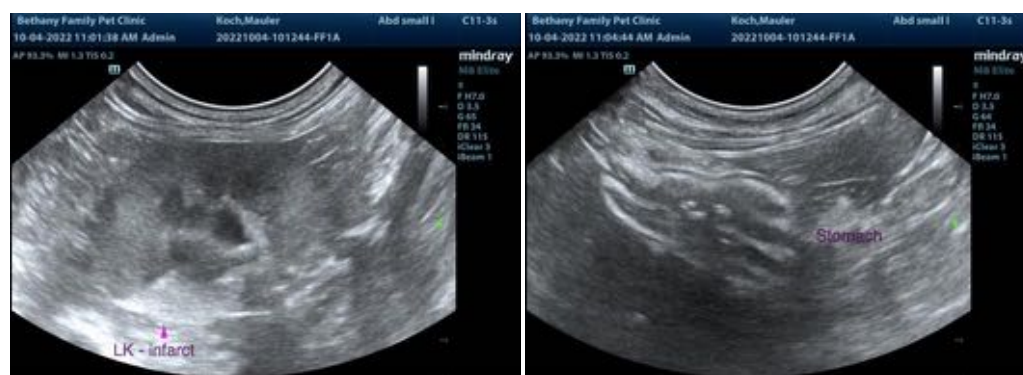
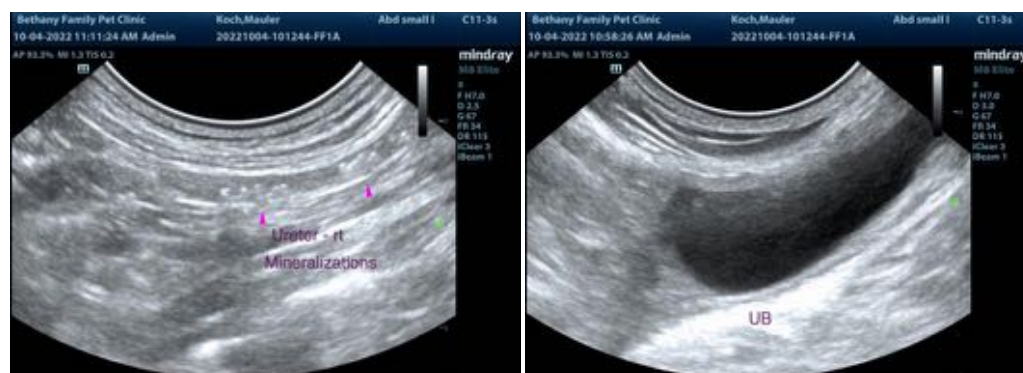
REFERRING VET

Dr. Saum Hadi

INVOICE

14059

DATE
10/4/22



The information and recommendations provided are based on the images presented by the referring veterinarian/sonographer. No evaluation can be communicated regarding pathology that was not visible in the image/video clips provided.

Thank you for this referral. If the clinical or image interpretation does not parallel your findings or if I can be of any further assistance please contact me.

Andrea Nicastro, MPH, DVM, Diplomate DACVIM (Small Animal Internal Medicine)
info@SonoPath.com