



**PATIENT PRESENTING CLINICAL SIGNS**

Riley Lehr History: R/C AUS last scan 2/10/21. Previous history of sand in the bladder, non-obstructive nephroliths, slight pyelectasia left kidney and low-grade pancreatitis  
Abnormal PE/Chem/CBC/UA Results: Had cystotomy April 2021 Stone sand composition Struvite, Ca oxalate, and Ammonium Acid Urate. Odd mix. Rescan AUS

**SPECIES**

Canine

**ULTRASONOGRAPHIC EXAMINATION OF THE ABDOMEN**

**BREED**

*Urinary System*

Shih Tzu

The urinary bladder is mostly contracted. The wall is of appropriate thickness for the level of repletion. Hyperechoic to mineralized foci are observed within the ventroapical aspect. A moderate amount of mineralized sand +/- tiny calculi are observed within the lumen. The sand appears to extend somewhat into the proximal urethra, although the urethra does not appear obstructed. The region of the trigone is difficult to assess due to the shadowing from the mineralized sand, however no obvious abnormalities are observed in this region.

**SEX**

Male, neutered

**AGE**

6 Yrs. 2 months

The prostate is normal in size (0.94 cm in width) and shape. Parenchyma is homogenous. The prostatic urethra appears normal without evidence of dilation or obstruction.

**WEIGHT**

11.47 kg

The left kidney is normal size (5.60 cm in length); normal shape and architecture with smooth peripheral margins. There is a normal 1:3 cortex to medulla ratio with normal corticomedullary distinction. Several small nephroliths are visualized. Trace pyelectasia is present. There is no evidence of infarcts or hydroureter. Renal vasculature is normal.

**INTERPRETED BY**

Andrea Nicastro, DVM,  
Diplomate ACVIM  
(Small Animal Internal  
Medicine)

The right kidney is normal size (5.61 cm in length); normal shape and architecture with smooth peripheral margins. There is a normal 1:3 cortex to medulla ratio with mild loss of corticomedullary distinction. Several small nephroliths are visualized. Trace pyelectasia is present. There is no evidence of infarcts or hydroureter. Renal vasculature is normal.

*Adrenal Glands*

**IMAGING PERFORMED BY**

Dr. Brian Barnes

The left adrenal gland is normal size (0.33 cm at cranial pole) (0.52 cm at caudal pole) (1.96 cm in length); normal shape; homogenous parenchyma. The glandular echogenicity and detail are unremarkable. Capsule, cortex, and medullary definition are normal. The phrenicoabdominal vein and surrounding vasculature are normal.

**HOSPITAL NAME**

Westview VH

The right adrenal gland is normal size (0.34 cm at cranial pole) (0.31 cm at caudal pole) (2.17 cm in length); normal shape; homogenous parenchyma. The glandular echogenicity and detail are unremarkable. Capsule, cortex, and medullary definition are normal. The phrenicoabdominal vein and surrounding vasculature are normal.

*Spleen*

**REFERRING VET**

Dr. Brian Barnes

The spleen is normal in size (1.35 cm in width at the level of the hilus) with a normal capsular contour. There is appropriate echogenicity and echotexture. No focal lesions are observed. Splenic vasculature is normal.

*Liver*

**INVOICE**

12278

The liver is subjectively prominent in size with swollen curvilinear peripheral contours. The parenchyma is isoechoic relative to the spleen and exhibits mild heterogeneity. No distinct focal lesions are observed. Hepatic vasculature and biliary tracts are of normal volume with no evidence of

**DATE**

10/4/21



**PATIENT**

Riley Lehr

congestion. The gall bladder lumen is moderately distended. The wall is thin and smooth. A moderate amount of gravity-dependent echogenic debris is observed within the lumen. The cystic and common bile ducts are normal/not seen.

**SPECIES**

Canine

**Gastrointestinal**

The gastric lumen is mildly distended. The gastric wall and pylorus are normal in thickness with a normal layering pattern. The pyloric outflow tract is patent. The small intestinal lumen is segmentally dilated with chyme. The small intestinal wall thickness is normal with a normal layering pattern and appropriate mural detail. The cecum is visible but no pathology is seen. The colonic wall is normal. No obstructive disease is noted.

**BREED**

Shih Tzu

**Pancreas**

**SEX**

Male, neutered

The right limb of the pancreas is visible with normal curvilinear peripheral contours. The parenchyma is largely isoechoic relative to surrounding omental fat and slightly mottled in appearance. The pancreatic duct is visible but not overtly dilated. There is no evidence of peripancreatic inflammation or effusion.

**AGE**

6 Yrs. 2 months

**Free Abdomen**

The peritoneal cavity is normal. There is no evidence of inflammation or effusion. The abdominal lymph nodes are normal/not visible.

**WEIGHT**

11.47 kg

**ULTRASONOGRAPHIC FINDINGS**

**Primary Findings:**

- Urinary bladder sand with tiny calculi within the bladder lumen and proximal urethra
- Bilateral nephrolithiasis with trace pyelectasia

**Secondary Findings:**

- The diffuse hepatic changes are non-specific and could be consistent with vacuolar hepatopathy, regenerative nodular hyperplasia, and/or age-related remodeling. Inflammatory and infiltrative disease are considered less likely.
- The pancreatic changes are most consistent with age-related parenchymal remodeling, potentially secondary to a prior inflammatory episode, early fibrosis or chronic pancreatitis.

**INTERPRETED BY**

Andrea Nicastro, DVM,  
Diplomate ACVIM  
(Small Animal Internal  
Medicine)

**IMAGING PERFORMED BY**

Dr. Brian Barnes

**HOSPITAL NAME**

Westview VH

**INTERPRETATION OF THE FINDINGS & FURTHER RECOMMENDATIONS**

- Consider abdominal radiographs to assess for discreet urinary calculi.
- A cystotomy with stone removal, analysis and culture is recommended. Alternatively, medical dissolution of the stones can be considered with a prescription renal diet and broad-spectrum antibiotic therapy. If there is no improvement in stone size after 4 weeks of therapy, a cystotomy should be reconsidered. If the stone size is reduced, continue therapy until complete dissolution has been achieved.
- Three-view thoracic radiographs are recommended prior to anesthesia to assess cardiopulmonary status.

**REFERRING VET**

Dr. Brian Barnes

**INVOICE**

12278

**DATE**

10/4/21



**PATIENT**

Riley Lehr

**SPECIES**

Canine

**BREED**

Shih Tzu

**SEX**

Male, neutered

**AGE**

6 Yrs. 2 months

**WEIGHT**

11.47 kg

**INTERPRETED BY**

Andrea Nicastro, DVM,  
Diplomate ACVIM  
(Small Animal Internal  
Medicine)

**IMAGING PERFORMED BY**

Dr. Brian Barnes

**HOSPITAL NAME**

Westview VH

**REFERRING VET**

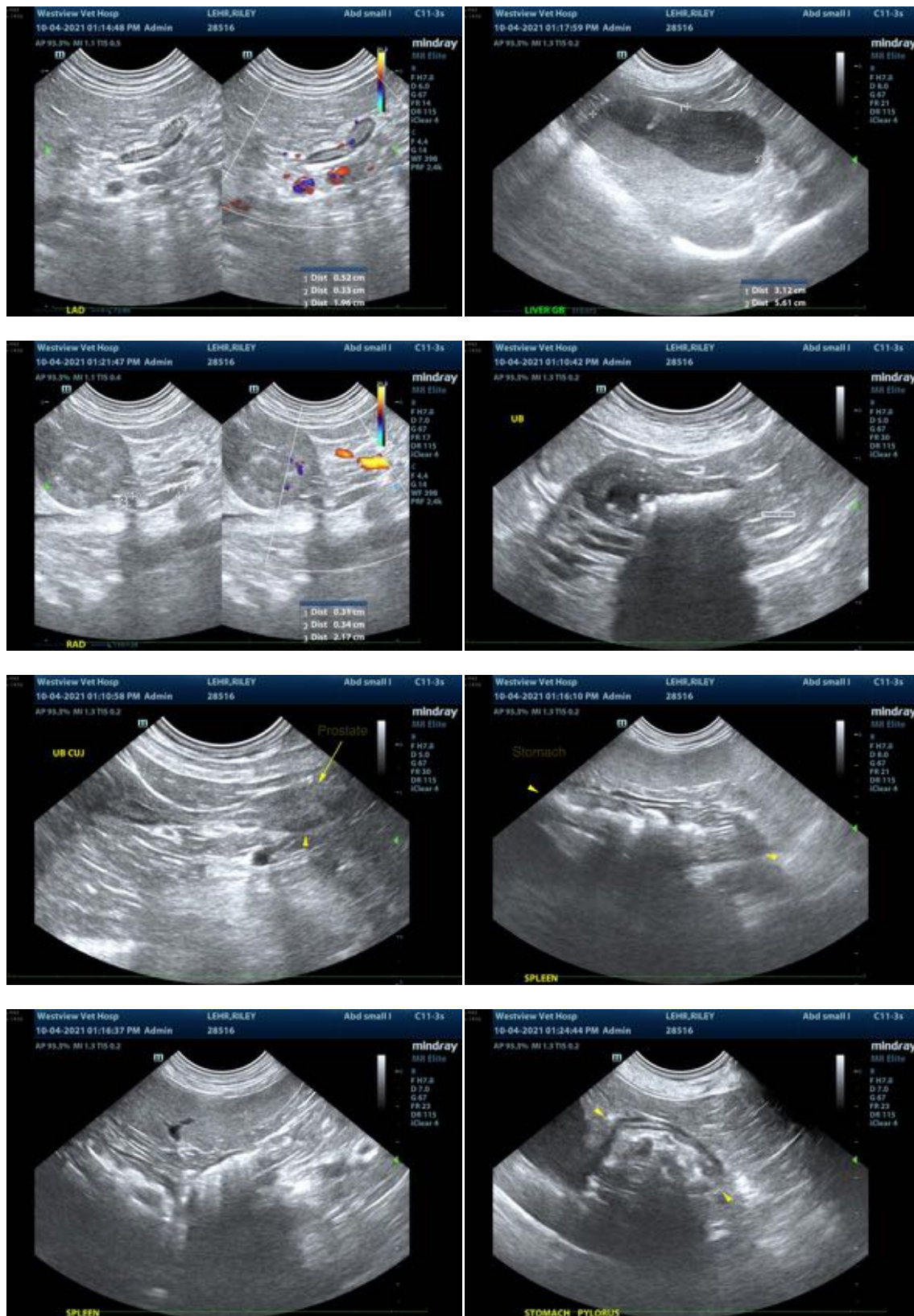
Dr. Brian Barnes

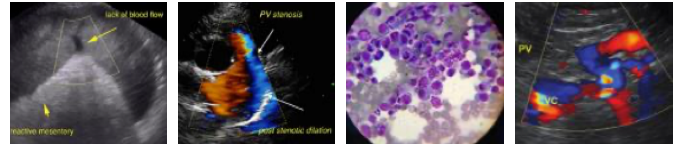
**INVOICE**

12278

**DATE**

10/4/21





**PATIENT**

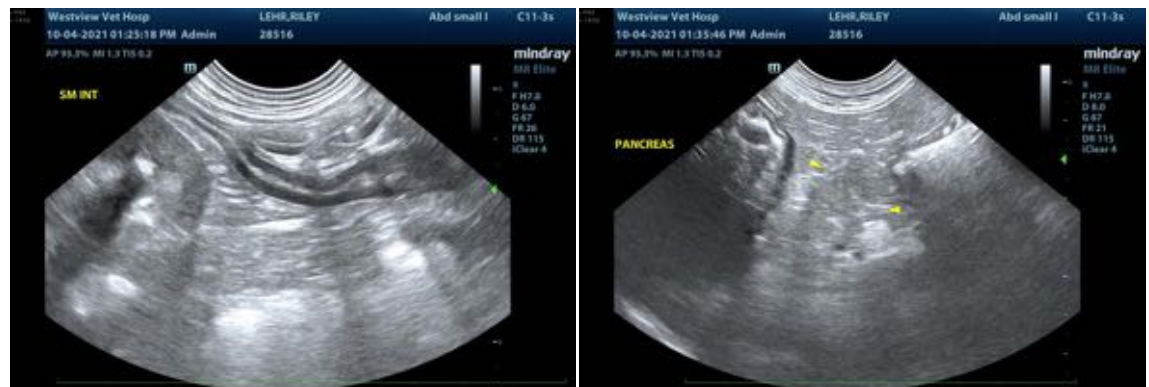
Riley Lehr

**SPECIES**

Canine

**BREED**

Shih Tzu



**SEX**

Male, neutered

**AGE**

6 Yrs. 2 months

**WEIGHT**

11.47 kg

The information and recommendations provided are based on the images presented by the referring veterinarian. No evaluation can be communicated regarding pathology that was not visible in the image/video clips provided.

Thank you for this referral. If the clinical or image interpretation does not parallel your findings or if I can be of any further assistance please contact me.

Andrea Nicastro, DVM, Diplomate ACVIM (*Small Animal Internal Medicine*)

Andrea.nicastro@sonopath.com

**INTERPRETED BY**

Andrea Nicastro, DVM,  
Diplomate ACVIM  
(*Small Animal Internal  
Medicine*)

**IMAGING  
PERFORMED BY**

Dr. Brian Barnes

**HOSPITAL NAME**

Westview VH

**REFERRING VET**

Dr. Brian Barnes

**INVOICE**

12278

**DATE**

10/4/21