

**DATE PRESENTING CLINICAL SIGNS**

10/4/21 History: Chronic weight loss, intermittent vomiting, pyrexia.

PATIENT Current Medications: Onsior, Mirataz, Cerenia.

Lyra Knudsen Lab Results: Elevated SDMA. Slightly low BUN. ALP is 114. tBili is 0.6. Normal T4. Normal hematocrit. White count is low with a mild neutropenia and lymphopenia.

SPECIES Radiographs: Not provided by the veterinarian.

Feline Date of Previous IntraPet Ultrasound: No previous IntraPet scans.

BREED Sedation: Gabapentin 100mg PO administered prior to scan.

Domestic Shorthair Stat Report: not requested

SEX ULTRASONOGRAPHIC EXAMINATION OF THE ABDOMEN

Female Spayed

AGE *Urinary System*
The urinary bladder, trigone, and pelvic urethra are normal in thickness and the mucosal surface is smooth. The bladder is moderately distended. A small amount of suspended echogenic debris is observed within the lumen. No masses, inflammatory changes or calculi are observed. Ureteral papillae and visualized portion of the proximal urethra, visible to a depth of 2 cm, are normal.

WEIGHT The left kidney is normal size (4.43 cm in length); normal shape and architecture with smooth peripheral margins. There is a normal 1:3 cortex to medulla ratio with minimal to mild loss of corticomedullary distinction. There is no evidence of pyelectasia, nephroliths, infarcts or hydroureter. Renal vasculature is normal.

INTERPRETED BY

Andrea Nicastro, DVM,
Diplomate ACVIM
(Small Animal Internal
Medicine)

The right kidney is normal size (5.14 cm in length); normal shape and architecture with smooth peripheral margins. There is a normal 1:3 cortex to medulla ratio with minimal to mild loss of corticomedullary distinction. There is no evidence of pyelectasia, nephroliths, infarcts or hydroureter. Renal vasculature is normal.

HOSPITAL NAME

Eastern Animal
Hospital

Adrenal Glands
The region of the adrenal glands is evaluated. No obvious pathology is observed.

REFERRING VET

Dr. Sole

Spleen
The spleen is normal in size (0.96 cm in width at the level of the hilus) with a normal capsular contour. There is appropriate echogenicity and echotexture. No focal lesions are observed. Splenic vasculature is normal.

INVOICE

11953kk

Liver
The liver is subjectively enlarged with swollen peripheral contours. The parenchyma is isoechoic relative to the spleen. The intrahepatic biliary ducts are diffusely dilated, and several intrahepatic biliary stones are visualized. Hepatic vasculature is of normal volume with no evidence of congestion. The gall bladder is distended. A bilobed confirmation is suspected. The wall is mildly thickened (up to 0.17 cm), hyperechoic, and irregular. Some echogenic debris is observed within the lumen. The cystic and common bile ducts are severely dilated and tortuous. The common bile duct wall is thickened (up to 0.29 cm). The common bile duct measures up to 2.91 cm in diameter in one region. Echogenic to mineralized debris +/- small choledocoliths are observed within the lumen. A complete luminal obstruction is difficult to determine due to the dilated/tortuous nature of the common bile duct.

Gastrointestinal

The gastric wall is normal in thickness with a normal layering pattern. The gastric lumen is not distended. One to two small intestinal bowel loops are moderately to severely fluid distended and hypomotile with borderline thickened walls. The remaining small intestinal loops are normal in thickness with a normal layering pattern and are not dilated. The colonic wall is normal.

Pancreas

A portion of the pancreas is difficult to visualize due to the hepatobiliary pathology. In the visualized portion, the parenchyma is slightly mottled in appearance.

Free Abdomen

Trace free fluid is observed. A few, prominent, mesenteric lymph nodes are visualized. The largest measures 2.05 cm in length. Surrounding mesentery is hyperechoic.

ULTRASONOGRAPHIC FINDINGS

Primary Findings:

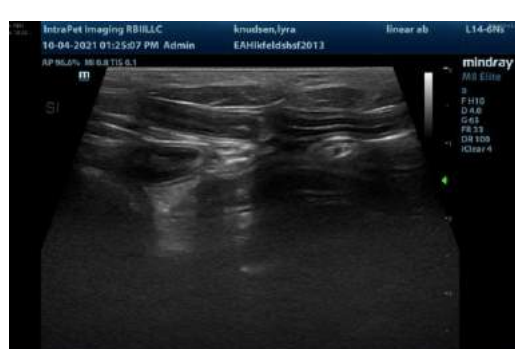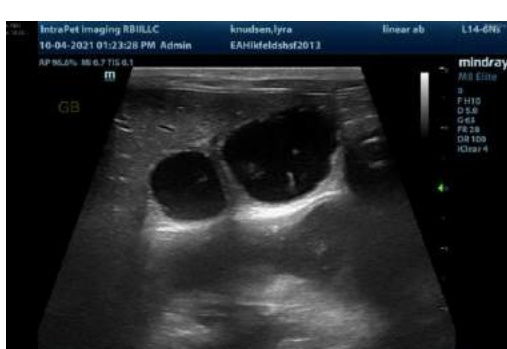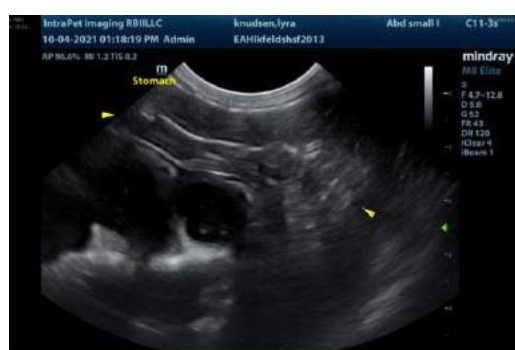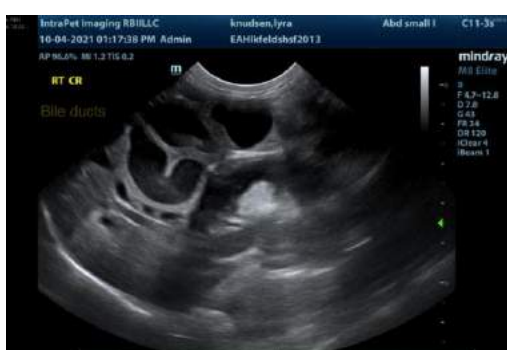
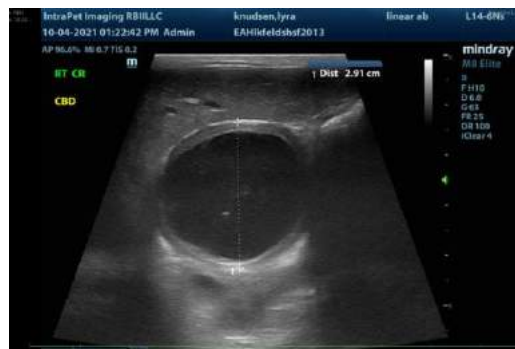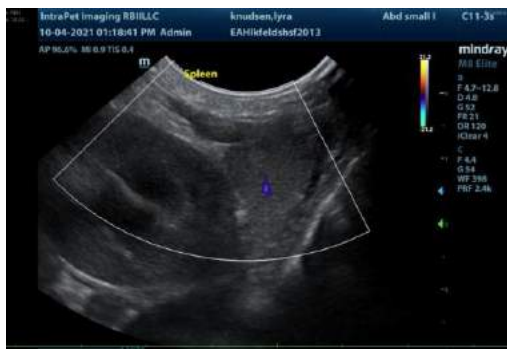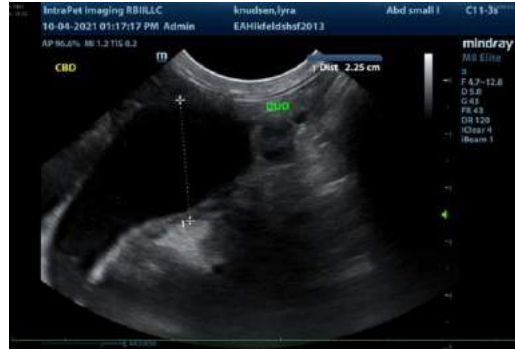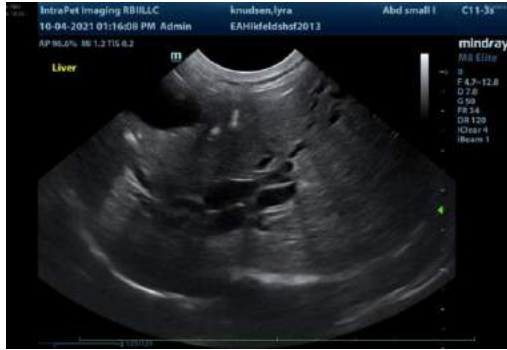- The hepatic changes are most consistent with cholangiohepatitis with intrahepatic biliary stones +/- concurrent pathology (i.e., hepatic lipidosis or infiltrative neoplasia).
- The severe dilation of the cystic and common bile ducts may represent partial obstruction, which is likely chronic in nature. Cholangitis with mineralized debris +/- distinct choledocoliths. Gall bladder changes consistent with cholecystitis.
- The prominent abdominal lymph nodes are most consistent with reactive lymphadenitis or lymphoid hyperplasia. Neoplastic infiltration is considered less likely.
- The trace free fluid is likely secondary to hepatobiliary pathology.
- The pancreatic changes may be secondary to inflammatory disease +/- concurrent remodeling/fibrosis.
- The segmental small intestinal dilation without obvious evidence of a foreign body could be consistent with focal ileus. However, a partial foreign body cannot be completely excluded.

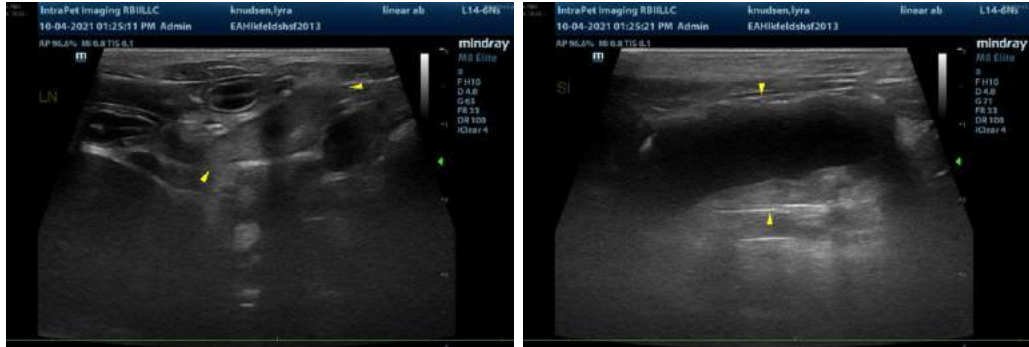Secondary Findings:

- Bilateral, age-related renal pathology.

INTERPRETATION OF THE FINDINGS & FURTHER RECOMMENDATIONS

1. If a conservative approach is desired, consider empirical medical treatment for cholangiohepatitis/cholangitis/cholecystitis with broad-spectrum antibiotic therapy, Denamarin, and supportive care. Nutritional support is strongly recommended (i.e., via temporary feeding tube) to help prevent/treat hepatic lipidosis.
2. If the patient's clinical signs do not improve within 3-5 days, consider repeat abdominal imaging +/- an abdominal exploratory to assess bile duct patency and to evaluate for a possible intestinal foreign body. Three-view thoracic radiographs are recommended prior to any anesthetic event.





The information and recommendations provided are based on the images presented by the referring veterinarian. No evaluation can be communicated regarding pathology that was not visible in the image/video clips provided.

Thank you for this referral. If the clinical or image interpretation does not parallel your findings or if I can be of any further assistance, please contact me.

Andrea Nicastro, DVM, Diplomate ACVIM (*Small Animal Internal Medicine*)
Andrea.nicastro@sonopath.com