

**DATE PRESENTING CLINICAL SIGNS**

10/4/2021

History: vomiting, anorexia, and weight loss.

**PATIENT**

Bella Rode

Current Medications: Not provided by the veterinarian.

Lab Results: Not provided by the veterinarian.

Radiographs: rads - displaced SI - ventrally, caudally, increased ST density - cranial abd.

Date of Previous IntraPet Ultrasound: No previous IntraPet scans.

Sedation: not needed

Stat Report: not requested / declined

**SPECIES**

Canine

**BREED**

Labrador retriever

**SEX**

Female, spayed

**AGE**

10/15/2012

**WEIGHT**

65.1 lbs.

**INTERPRETED BY**

Andrea Nicastro, DVM,  
 Diplomate ACVIM  
 (Small Animal Internal  
 Medicine)

**HOSPITAL NAME**

Eastern AH

**REFERRING VET**

Dr. Kaufman

**INVOICE**

12279

**ULTRASONOGRAPHIC EXAMINATION OF THE ABDOMEN****Urinary System**

The urinary bladder, trigone, and pelvic urethra are normal in thickness and the mucosal surface is smooth.

The bladder lumen is moderately distended with mostly anechoic urine. No masses, inflammatory changes or calculi are observed. Ureteral papillae and visualized portion of the proximal urethra, visible to a depth of 2 cm, are normal.

The left kidney is normal size (6.65 cm in length); normal shape and architecture with smooth peripheral margins. There is a normal 1:3 cortex to medulla ratio with normal corticomedullary distinction. There is no evidence of pyelectasia, nephroliths, infarcts or hydroureter. Renal vasculature is normal.

The right kidney is normal size (5.94 cm in length); normal shape and architecture with smooth peripheral margins. There is a normal 1:3 cortex to medulla ratio with minimal loss of corticomedullary distinction. There is no evidence of pyelectasia, nephroliths, infarcts or hydroureter. Renal vasculature is normal.

**Adrenal Glands**

The left adrenal gland is normal size (0.68 cm at cranial pole) (0.70 cm at caudal pole) (2.65 cm in length); normal shape; homogenous parenchyma. The glandular echogenicity and detail are unremarkable. Capsule, cortex, and medullary definition are normal. The phrenicoabdominal vein and surrounding vasculature are normal.

The right adrenal gland is normal size (0.59 cm at cranial pole) (0.63 cm at caudal pole) (2.61 cm in length); normal shape; homogenous parenchyma. The glandular echogenicity and detail are unremarkable. Capsule, cortex, and medullary definition are normal. The phrenicoabdominal vein and surrounding vasculature are normal.

**Spleen**

The spleen is normal in size (1.95 cm in width at the level of the hilus) with a normal capsular contour. There is appropriate echogenicity and echotexture. No focal lesions are observed. Splenic vasculature is normal.

**Liver**

The liver is subjectively normal in size with normal curvilinear peripheral contours. The parenchyma is hypoechoic relative to the spleen and slightly mottled in appearance. No distinct focal lesions are observed. Vascular and biliary tracts are of normal volume with no evidence of congestion. The gall bladder lumen is moderately distended. The wall is thin and smooth. Luminal contents are anechoic. The cystic and common bile ducts are normal/not seen.

**Gastrointestinal**

The gastric wall and pylorus are normal in thickness with a normal layering pattern. The gastric lumen is not distended. The small intestinal lumen is not dilated. The duodenal and jejunal walls are mildly thickened with a normal layering pattern and appropriate mural detail. There is disruption in the normal 1:3 muscularis: mucosal ratio and thickening of the submucosal layer in most segments. An 8.98 x 5.73 cm irregular mass

effect is observed at the ileocecal colic junction. The wall within this region is severely thickened and irregular with the loss of the normal layering pattern. Surrounding mesentery is hyperechoic and adhered to the serosal surface. The remaining colonic wall is normal.

### ***Pancreas***

The region of the pancreas is isoechoic relative to surrounding omental fat. No obvious parenchymal abnormalities are observed. There is no evidence of regional inflammation or effusion.

### ***Free Abdomen***

The mesentery throughout the abdomen is hyperechoic. Trace free fluid is observed. Several enlarged, irregular hypoechoic lymph nodes are adhered to the mass at the ileocecal colic junction. Other enlarged lymph nodes are also seen within the abdomen.

## **ULTRASONOGRAPHIC FINDINGS**

### **Primary Findings:**

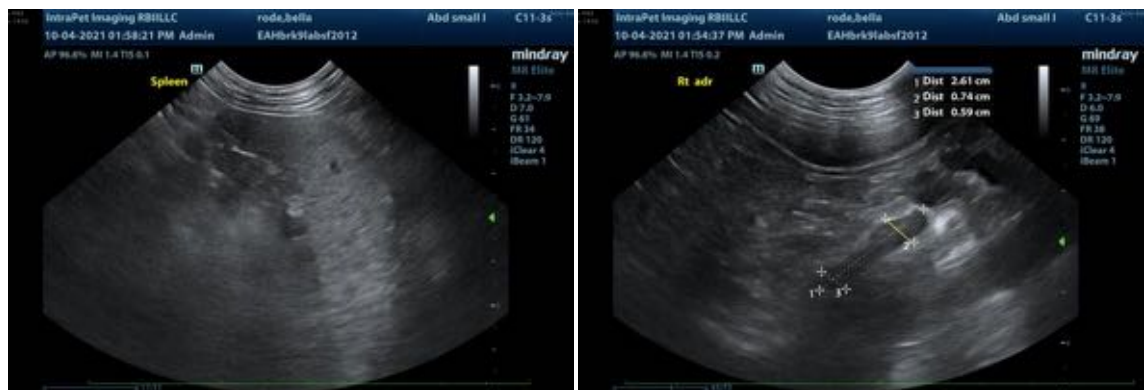- Mass effect at the ileocecal colic junction. Neoplasia (i.e., lymphoma, adenocarcinoma) is considered likely with a low possibility of a severe inflammatory process. Regional peritonitis is present. The adjacent lymphadenopathy could be consistent with infiltrative neoplasia, reactive lymphadenitis or lymphoid hyperplasia. A neoplastic process is favored.

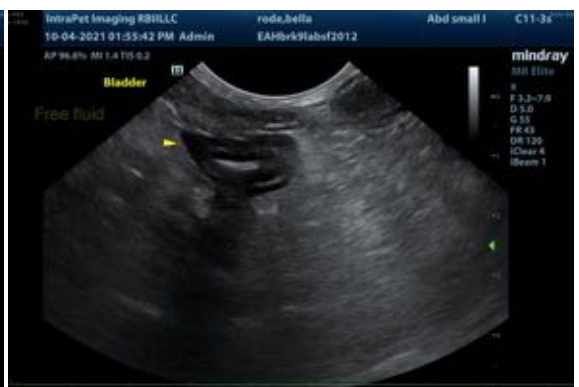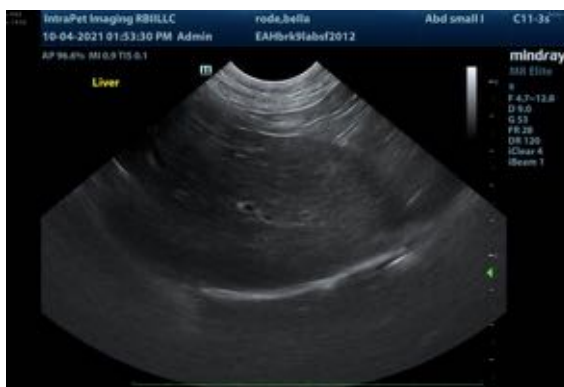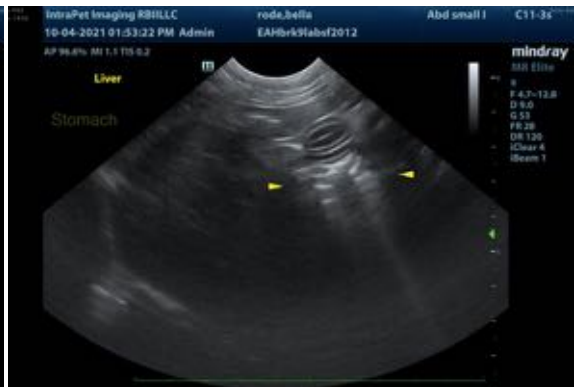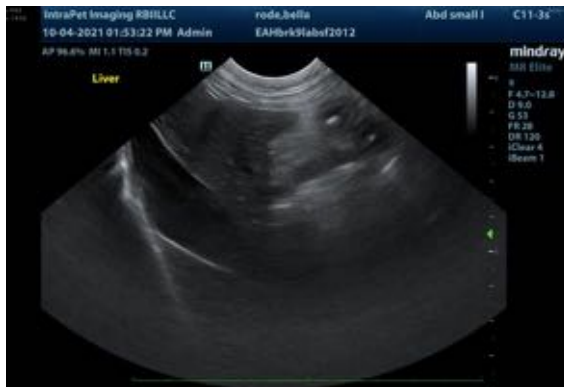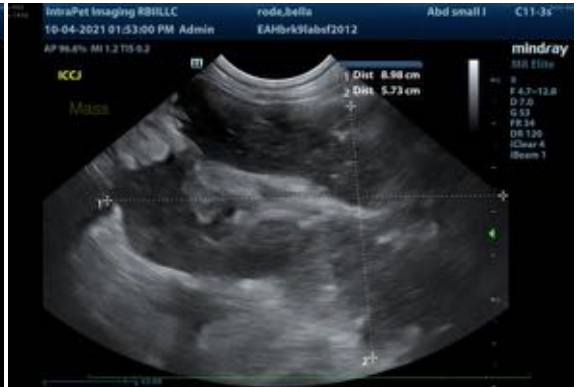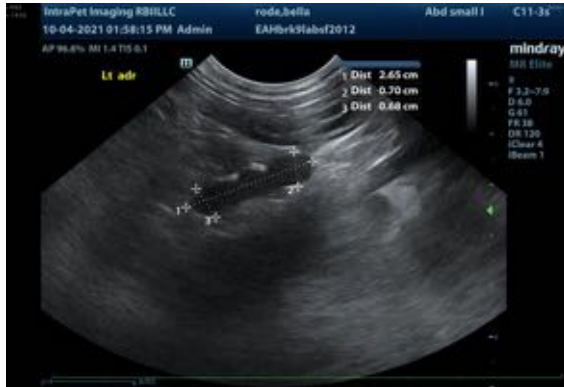### **Secondary Findings:**

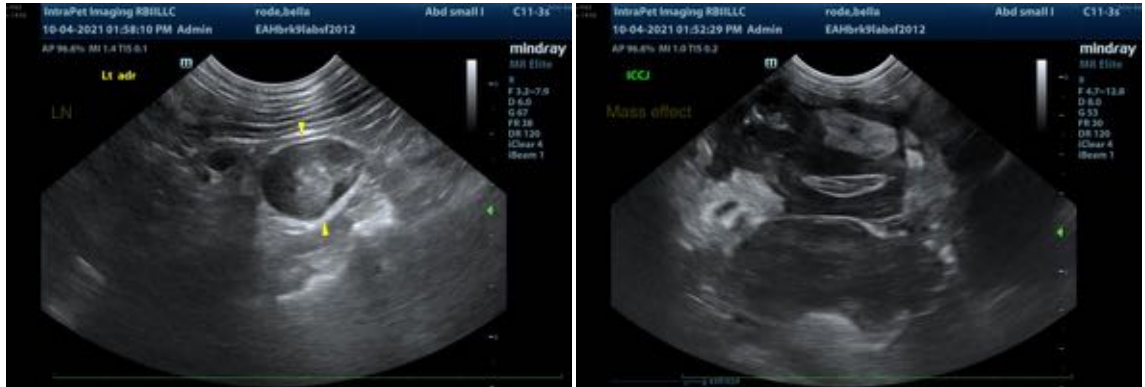
- Minor age-related renal and hepatic pathology.

## **INTERPRETATION OF THE FINDINGS & FURTHER RECOMMENDATIONS**

- Three-view thoracic radiographs are recommended to assess for pulmonary metastases.
- A fine needle aspirate of the mass at the ileocecal colic junction is recommended (if clotting status is normal). A 25-gauge needle should be used. If cytologic evaluation is inconclusive, surgical biopsies may be necessary to get a definitive diagnosis. If surgery is pursued, consider referral to a board-certified veterinary surgeon.







The information and recommendations provided are based on the images presented by the referring veterinarian. No evaluation can be communicated regarding pathology that was not visible in the image/video clips provided.

Thank you for this referral. If the clinical or image interpretation does not parallel your findings or if I can be of any further assistance please contact me.

Andrea Nicastro, DVM, Diplomate ACVIM (*Small Animal Internal Medicine*)  
Andrea.nicastro@sonopath.com