



**PATIENT**

Scout McAllister

**PRESENTING CLINICAL SIGNS**

History: No clinical signs.  
Abnormal PE/Chem/CBC/UA Results: Borderline low red blood cell count and decreased hemoglobin. Hematocrit borderline low for several months- 34.2, non-regenerative.

**SPECIES**

Canine

**ULTRASONOGRAPHIC EXAMINATION OF THE ABDOMEN**

**BREED**

Bichon mix

*Urinary System*

The urinary bladder wall is normal in thickness and the mucosal surface is smooth. The bladder lumen is moderately distended with mostly anechoic urine. No masses, inflammatory changes or calculi are observed. Ureteral papillae and visualized portion of the proximal urethra, visible to a depth of 2 cm, are normal.

**SEX**

Male, neutered

The prostate is normal in size (0.93 cm in width) and shape. Parenchyma is homogenous. The prostatic urethra appears normal without evidence of dilation or obstruction.

**AGE**

12 Yrs.

The left kidney is normal size (5.28 cm in length); normal shape and architecture with smooth peripheral margins. There is a normal 1:3 cortex to medulla ratio with normal corticomedullary distinction. There is no evidence of pyelectasia, nephroliths, infarcts or hydroureter.

**WEIGHT**

24.4 lbs.

The right kidney is normal size (5.48 cm in length); normal shape and architecture with smooth peripheral margins. There is a normal 1:3 cortex to medulla ratio with normal corticomedullary distinction. There is no evidence of pyelectasia, nephroliths, infarcts or hydroureter.

**INTERPRETED BY**

Andrea Nicastro, DVM,  
Diplomate ACVIM  
(*Small Animal Internal  
Medicine*)

*Adrenal Glands*

The left adrenal gland is normal size (0.49 cm at cranial pole) (0.54 cm at caudal pole); normal shape; homogenous parenchyma. The glandular echogenicity and detail are unremarkable. Capsule, cortex, and medullary definition are normal. The phrenicoabdominal vein and surrounding vasculature are normal.

The right adrenal gland is normal size (0.47 cm at cranial pole) (0.53 cm at caudal pole); normal shape; homogenous parenchyma. The glandular echogenicity and detail are unremarkable. Capsule, cortex, and medullary definition are normal. The phrenicoabdominal vein and surrounding vasculature are normal.

**IMAGING PERFORMED BY**

Amy Mayhew

*Spleen*

The spleen is subjectively prominent in size with irregular peripheral contours. Numerous heterogeneous nodules/masses are observed throughout the organ, some of which are cavitated. The largest masses are at the cranial aspect (1.87 cm) and mid-spleen (2.17 cm). The cranial mass has a large cavitated region. Many of the lesions cause capsular expansion. Splenic vasculature appears normal with no evidence of thrombosis.

**HOSPITAL NAME**

SVS Imaging Michigan

**REFERRING VET**

Rochester VH

*Liver*

The liver is prominent in size with slightly swollen peripheral contours. The parenchyma is isoechoic relative to the spleen. Numerous hypoechoic to anechoic nodules are observed throughout the organ. Vascular and biliary tracts are of normal volume with no evidence of congestion. The gall bladder lumen is moderately distended. The wall is thin and smooth. A moderate amount of aggregated, hyperechoic

**INVOICE**

14164

**DATE**

10/31/22



**PATIENT**

Scout McAllister

mostly gravity-dependent debris/sludge is observed within the lumen. The cystic and common bile ducts are normal/not seen.

***Gastrointestinal***

**SPECIES**

Canine

The gastric lumen is moderately distended with ingesta. The gastric wall and pylorus are normal in thickness with a normal layering pattern. The pyloric outflow tract is patent. The small intestinal lumen is segmentally dilated with gas. The small intestinal wall thickness is normal with a normal layering pattern and appropriate mural detail. Discreet masses are not identified. The colonic wall is normal. No obstructive disease is noted.

**BREED**

Bichon mix

***Pancreas***

**SEX**

Male, neutered

The region of the pancreas is isoechoic relative to surrounding omental fat. No obvious parenchymal abnormalities are observed. There is no evidence of regional inflammation or effusion.

***Free Abdomen***

**AGE**

12 Yrs.

There is no evidence of free fluid. A medial iliac lymph node is visualized measuring 1.13 cm in length. The node is normal in shape and echogenicity.

**WEIGHT**

24.4 lbs.

**ULTRASONOGRAPHIC FINDINGS**

- The splenic nodules/masses are most consistent with infiltrative neoplasia. Top differentials include round cell neoplasia and sarcoma.
- The diffuse hepatic nodules are concerning for metastatic disease with a lower possibility of a multifocal inflammatory process.

**INTERPRETED BY**

Andrea Nicastro, DVM,  
Diplomate ACVIM  
(*Small Animal Internal  
Medicine*)

**INTERPRETATION OF THE FINDINGS & FURTHER RECOMMENDATIONS**

- Consider fine needle aspirates of the spleen, if clotting status is appropriate. 25 gauge needles should be used. Care should be taken to avoid cavitated lesions and the patient should be monitored sonographically for 5-10 minutes post-aspiration to assess for iatrogenic hemorrhage. If cytology results are inconclusive, surgical biopsies of the liver and spleen may be necessary to get a definitive diagnosis.
- Three-view thoracic radiographs are recommended to assess for pulmonary metastatic disease.

**IMAGING  
PERFORMED BY**

Amy Mayhew

**HOSPITAL NAME**

SVS Imaging Michigan

**REFERRING VET**

Rochester VH

**INVOICE**

14164

**DATE**

10/31/22



**PATIENT**

Scout McAllister

**SPECIES**

Canine

**BREED**

Bichon mix

**SEX**

Male, neutered

**AGE**

12 Yrs.

**WEIGHT**

24.4 lbs.

**INTERPRETED BY**

Andrea Nicastro, DVM,  
Diplomate ACVIM  
(Small Animal Internal  
Medicine)

**IMAGING  
PERFORMED BY**

Amy Mayhew

**HOSPITAL NAME**

SVS Imaging Michigan

**REFERRING VET**

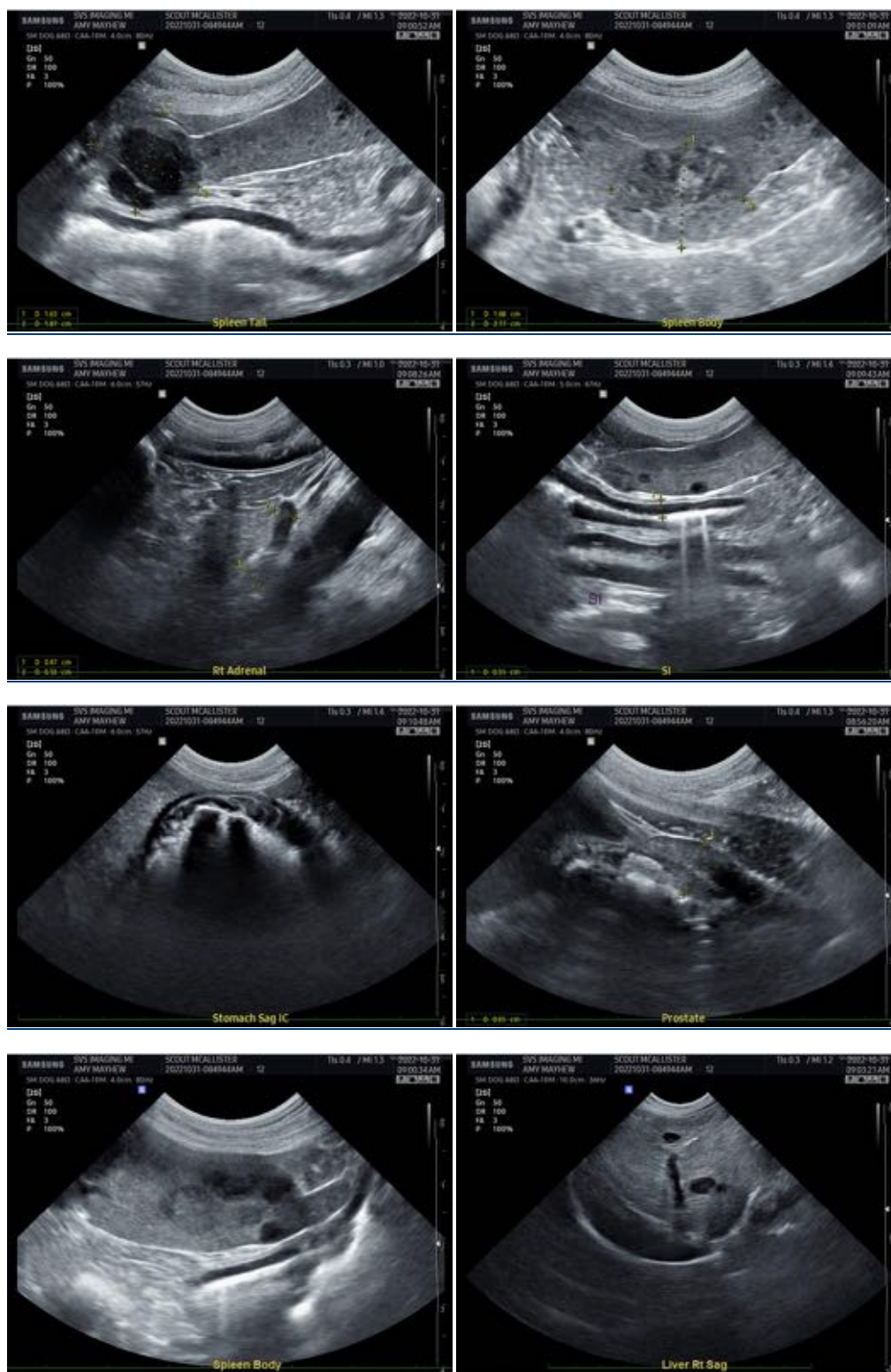
Rochester VH

**INVOICE**

14164

**DATE**

10/31/22





**PATIENT**

Scout McAllister

**SPECIES**

Canine

**BREED**

Bichon mix

**SEX**

Male, neutered

**AGE**

12 Yrs.

**WEIGHT**

24.4 lbs.

**INTERPRETED BY**

Andrea Nicastro, DVM,  
Diplomate ACVIM  
(*Small Animal Internal  
Medicine*)

**IMAGING  
PERFORMED BY**

Amy Mayhew

**HOSPITAL NAME**

SVS Imaging Michigan

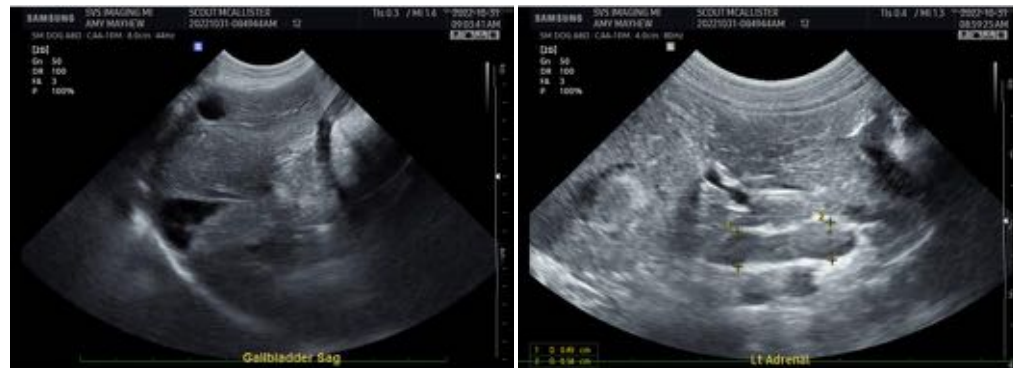
**REFERRING VET**

Rochester VH

**INVOICE**

14164

**DATE**  
10/31/22



The information and recommendations provided are based on the images presented by the referring veterinarian/sonographer. No evaluation can be communicated regarding pathology that was not visible in the image/video clips provided.

Thank you for this referral. If the clinical or image interpretation does not parallel your findings or if I can be of any further assistance please contact me.

Andrea Nicastro, MPH, DVM, Diplomate DACVIM (Small Animal Internal Medicine)  
info@SonoPath.com