

**DATE**

10/3/22

PATIENT

Raven Campbell

SPECIES

Canine

BREED

Beagle mix

SEX

Female, spayed

AGE

10/1/2011

WEIGHT

38.2. lbs.

INTERPRETED BY

Andrea Nicastro, DVM,
Diplomate ACVIM
(*Small Animal Internal
Medicine*)

HOSPITAL NAME

Animal Emergency
Hospital

REFERRING VET

Dr. Kalwa

INVOICE

14043

PRESENTING CLINICAL SIGNS

Vomiting - Diarrhea - Polydipsia ATO in room: - Wed ate fine - Thursday night eating less- walking, diarrhea, gave Imodium. Started vomiting overnight- yellow foam/ grass - Friday- not eating, watery diarrhea - drinking a lot then will vomit white foam - Normally sleeps all day and is up at night Hx: - Arthritis: Tramadol, Carprofen, gabapentin - amlodipine? - Allergies (seasonal): Apoquel (O states she can have chicken) - Fleas - Elevated liver values since she was a puppy- elevated but stable - Pancreatitis once last year or earlier this ear - Broken tail No hx of CKD or heart murmur No weight loss. New puppy in house- purchased few weeks ago- when puppy came in had diarrhea- had abx, probiotics, fecal- fecal negative- but diarrhea resolved 2 weeks ago.

Current Medications: None listed.

Lab Results: USG 1.042, 3+ proteinuria, BUN 31, normal creat, ALP 1378, Blood pressure 200-220 systolic. Radiographs: Very overweight- very enlarged/rounded liver, kidney stones.

Date of Previous IntraPet Ultrasound: No previous.

Sedation: Not required to complete full diagnostic ultrasound.

Stat Report: Not requested.

Imaging Performed By: Andi Parkinson, BS, RDMS.

ULTRASONOGRAPHIC EXAMINATION OF THE ABDOMEN**Urinary System**

The urinary bladder wall is normal in thickness and the mucosal surface is smooth. The bladder lumen is moderately distended with anechoic urine. No masses, inflammatory changes or calculi are observed. Ureteral papillae and visualized portion of the proximal urethra, visible to a depth of 2 cm, are normal.

The left kidney is normal size (5.80 cm in length) with a slightly irregular shape. The cortex is diffusely thickened and irregular. There is poor corticomedullary distinction. Several small cortical cysts are seen. Mild to moderate pyelectasia is present (0.29 cm in the longitudinal plane). There is no evidence of hydronephrosis.

The right kidney is normal size (5.84 cm in length) with a slightly irregular shape. The cortex is diffusely thickened and irregular. There is poor corticomedullary distinction. Several small cortical cysts are seen. Non-obstructive nephroliths are observed throughout the kidney. There is no evidence of hydronephrosis.

Adrenal Glands

The left adrenal gland is mildly enlarged (0.66 cm at cranial pole) (0.73 cm at caudal pole) (2.32 cm in length); normal shape; homogenous parenchyma. The glandular echogenicity and detail are unremarkable. Capsule, cortex, and medullary definition are normal. The phrenicoabdominal vein and surrounding vasculature are normal.

The right adrenal gland is normal size (0.80 cm at cranial pole) (0.68 cm at caudal pole) (2.47 cm in length); normal shape; homogenous parenchyma. The glandular echogenicity and detail are unremarkable. Capsule, cortex, and medullary definition are normal. The phrenicoabdominal vein and surrounding vasculature are normal.

Spleen

The spleen is normal in size (1.09 cm in width at the level of the hilus) with a normal capsular contour. There is appropriate echogenicity and echotexture. No focal lesions are observed. Splenic vasculature is normal.

Liver

The liver is subjectively enlarged with slightly swollen peripheral contours. The parenchyma is isoechoic relative to the spleen and diffusely homogeneous in appearance. No distinct focal lesions are observed. Vascular and biliary tracts are of normal volume with no evidence of congestion. The gall bladder

lumen is moderately distended. The wall is mildly to moderately thickened (up to 0.31 cm) and slightly irregular. A scant amount of echogenic debris is adhered to the luminal surface. The cystic and common bile ducts are normal/not seen.

Gastrointestinal

The stomach and intestine are free of stasis and exhibit normal peristaltic activity. The gastric lumen is not distended. The gastric wall and pylorus are normal in thickness with a normal layering pattern. The pyloric outflow tract is patent. The small intestinal lumen is not dilated. The small intestinal wall thickness is normal with a normal layering pattern and appropriate mural detail. Discreet masses are not identified. The colonic wall is normal. No obstructive disease is noted.

Pancreas

The pancreas is normal in size with normal peripheral contours. The pancreatic duct is normal. The base and limbs of the pancreas are isoechoic to surrounding omental fat. No focal lesions are observed. There is no evidence of peripancreatic inflammation or effusion.

Free Abdomen

There is no evidence of free fluid. The abdominal lymph nodes are normal/not visible.

Other

A brief echocardiogram reveals no obvious evidence of pericardial effusion.

ULTRASONOGRAPHIC FINDINGS

Primary Findings:

- An obvious cause for the patient's gastrointestinal signs is not identified in this study. Considerations include dietary indiscretion, infectious/parasitic disease, low-grade pancreatitis, underlying metabolic issue, other.

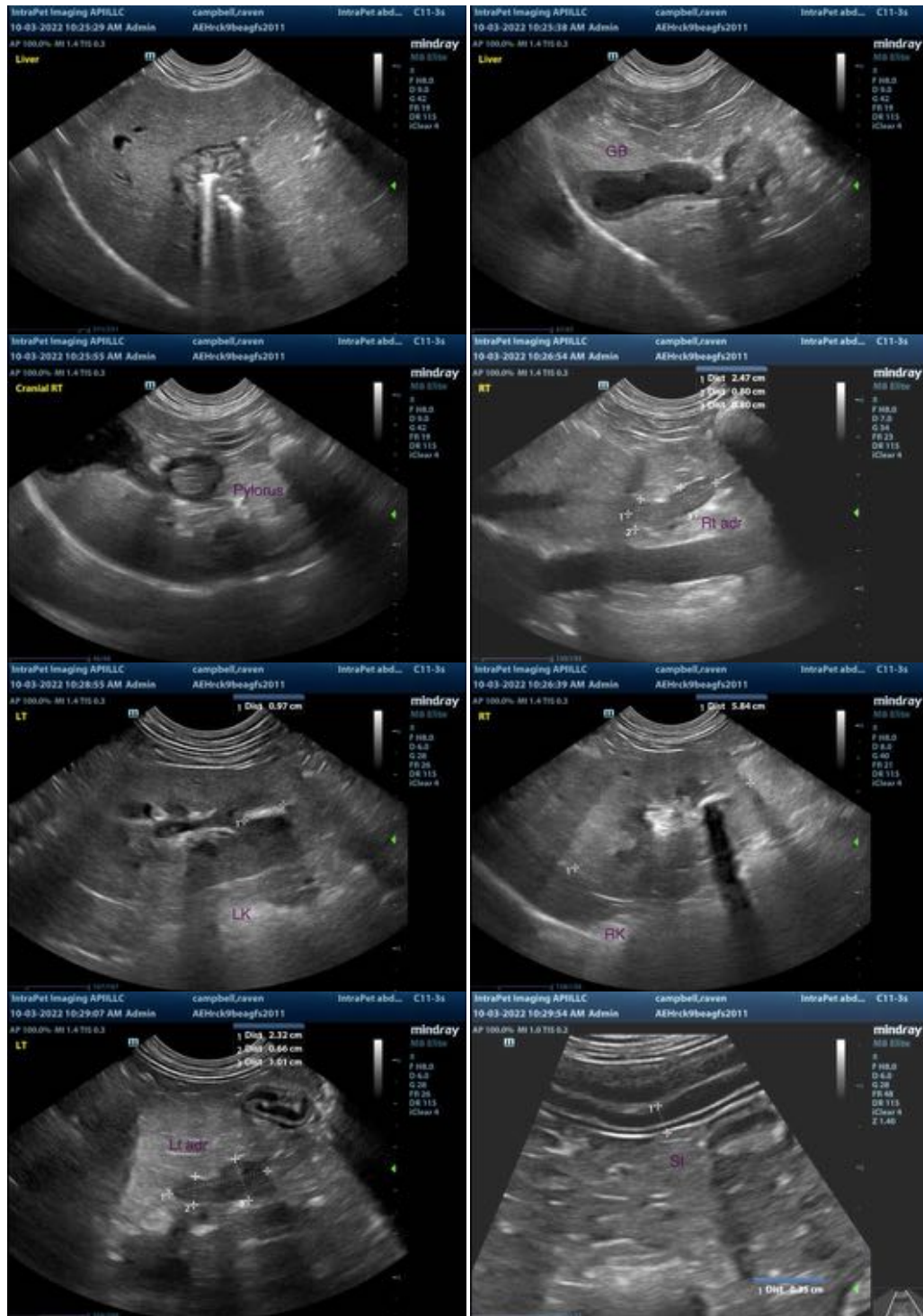
Secondary Findings:

- Bilateral, degenerative renal changes with non-obstructive nephrolithiasis and left pyelectasia.
- The diffuse hepatic changes are non-specific and could be consistent with vacuolar hepatopathy, regenerative nodular hyperplasia, and/or age-related remodeling. Inflammatory and infiltrative disease are considered less likely.
- The gallbladder wall changes are consistent with cholecystitis +/- concurrent age-related benign age-related hyperplasia.
- Mild left adrenomegaly. This may be a normal variant for this patient or may represent early hyperplastic change.

INTERPRETATION OF THE FINDINGS & FURTHER RECOMMENDATIONS

- Regarding the gastrointestinal changes, a fecal evaluation for ova and Giardia is recommended along with supportive care for acute gastroenteritis. Also consider prophylactic deworming with Fenbendazole. If the patient's clinical signs do not improve with medical management, a more advanced GI workup may be warranted.
- Regarding the renal changes, consider a urine culture and sensitivity to assess for occult infection.

Also consider a UPC if proteinuria is persistent in the absence of hematuria and infection.



The information and recommendations provided are based on the images presented by the referring veterinarian. No evaluation can be communicated regarding pathology that was not visible in the image/video

clips provided.

Thank you for this referral. If the clinical or image interpretation does not parallel your findings or if I can be of any further assistance please contact me.

Andrea Nicastro, MPH, DVM, Diplomate DACVIM (Small Animal Internal Medicine)
info@SonoPath.com