

**DATE PRESENTING CLINICAL SIGNS**

10.3.2022 Ate entire bag of dog food and ½ container of corned beef along with some of the plastic container.

PATIENT

Lelah Schenker

Current Medications: None.
 Date of Previous IntraPet Ultrasound: No previous.
 Sedation: Not required to complete full diagnostic ultrasound.
 Stat Report: Requested by DVM.
 Imaging Performed By: Andi Parkinson, RDMS.

SPECIES

Canine

BREED

Rottweiler

SEX

Spayed Female

AGE

11/22/2017

WEIGHT

91lbs

INTERPRETED BY

Andrea Nicastro, DMV,
 Diplomate DACVIM
 (Small Animal
 Internal Medicine)

HOSPITAL NAME

Edgewood VH

REFERRING VET

Dr. Wright

INVOICE

11766

ULTRASONOGRAPHIC EXAMINATION OF THE ABDOMEN**Urinary System**

The **urinary bladder** wall is normal in thickness and the mucosal surface is smooth. The bladder lumen is mildly distended with anechoic urine. No masses, inflammatory changes or calculi are observed. Ureteral papillae and visualized portion of the proximal urethra, visible to a depth of 2 cm, are normal.

The **left kidney** is normal size (7.75 cm in length); normal shape and architecture with smooth peripheral margins. There is a normal 1:3 cortex to medulla ratio with normal corticomedullary distinction. There is no evidence of pyelectasia, nephroliths, infarcts or hydronephrosis.

The **right kidney** is normal size (8.04 cm in length); normal shape and architecture with smooth peripheral margins. There is a normal 1:3 cortex to medulla ratio with normal corticomedullary distinction. There is no evidence of pyelectasia, nephroliths, infarcts or hydronephrosis.

Adrenal Glands

The **left adrenal gland** is normal size (0.45 cm at cranial pole) (0.61 cm at caudal pole) (2.98 cm in length); normal shape; homogenous parenchyma. The glandular echogenicity and detail are unremarkable. Capsule, cortex, and medullary definition are normal. The phrenicoabdominal vein and surrounding vasculature are normal.

The **right adrenal gland** is normal size (0.55 cm at cranial pole) (0.70 cm at caudal pole) (3.41 cm in length); normal shape; homogenous parenchyma. The glandular echogenicity and detail are unremarkable. Capsule, cortex, and medullary definition are normal. The phrenicoabdominal vein and surrounding vasculature are normal.

Spleen

The **spleen** is normal in size (1.88 cm in width at the level of the hilus) with a normal capsular contour. There is appropriate echogenicity and echotexture. No focal lesions are observed. Splenic vasculature is normal.

Liver

The **liver** is subjectively normal in size with normal contours and structure. There is appropriate echogenicity and echotexture. No overt structural evidence of inflammatory, infiltrative, or regenerative pathology is evident. Vascular and biliary tracts are of normal volume with no evidence of congestion. No pathological hepatic lymphadenopathy observed.

The **gall bladder** lumen is moderately distended. The wall is thin and smooth. Luminal contents are anechoic. The cystic and common bile ducts are normal/not seen.

Gastrointestinal

The **gastric lumen** is mildly gas-distended. The gastric wall is normal in thickness with a normal layering pattern. The pyloric outflow tract appears patent. The small intestinal lumen is minimally fluid and gas-

distended. The small intestinal wall is normal in thickness with a normal layering pattern and appropriate mural detail. Discreet masses are not identified. The colonic wall is normal. The colonic lumen contains shadowing fecal material. There is no obvious evidence of an obstructive pattern.

Pancreas

The region of the **pancreas** is isoechoic relative to surrounding omental fat. No obvious parenchymal abnormalities are observed. There is no evidence of regional inflammation or effusion.

Free Abdomen

The **peritoneal cavity** is normal. There is no evidence of inflammation or effusion. The abdominal **lymph nodes** are normal/not visible.

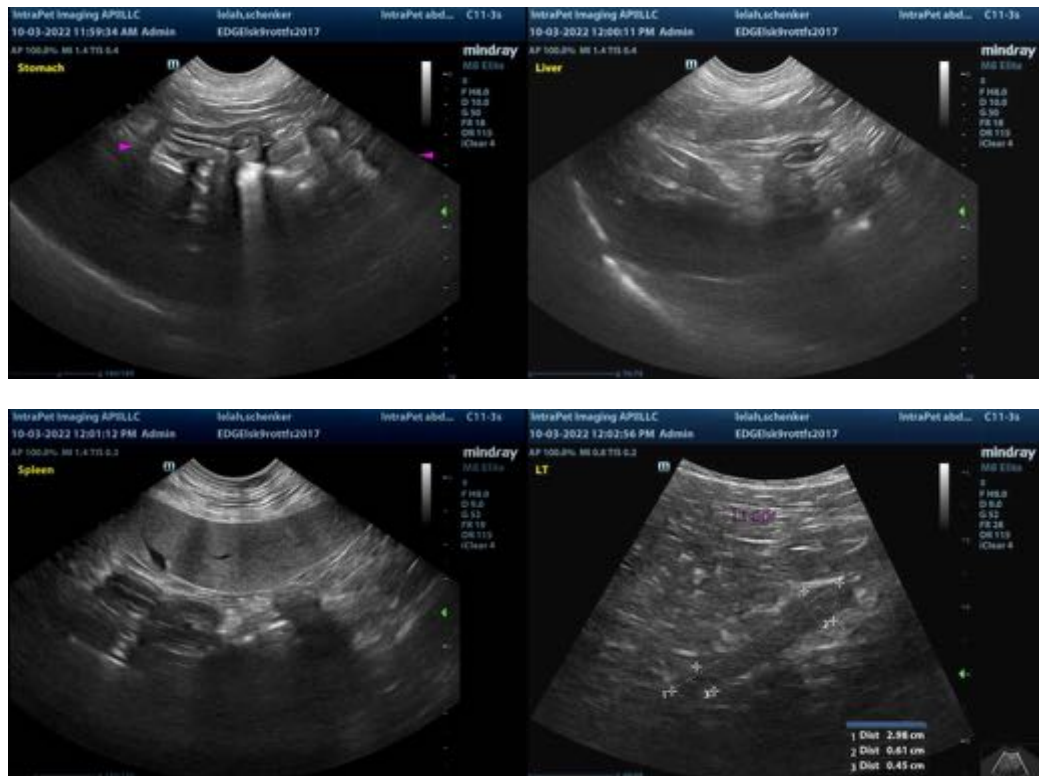
ULTRASONOGRAPHIC FINDINGS

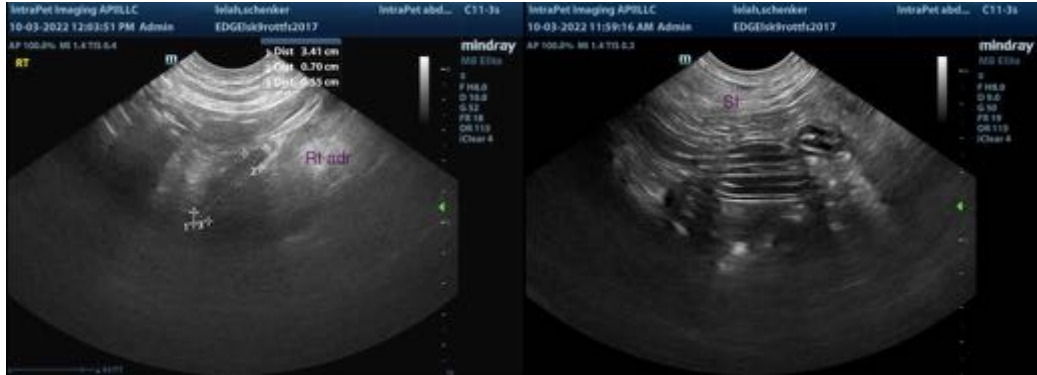
Primary Findings

- Unremarkable abdomen. There is no obvious evidence of a foreign body/obstruction. However, a partial obstruction cannot be completely excluded.

INTERPRETATION OF THE FINDINGS & FURTHER RECOMMENDATIONS

Supportive care for acute gastroenteritis is recommended, as needed. If the patient's clinical signs do not begin to improve with 24-48 hours of medical management, repeat abdominal imaging +/- a more advance GI work-up may be warranted.





The information and recommendations provided are based on the images presented by the referring veterinarian/sonographer. No evaluation can be communicated regarding pathology that was not visible in the image/video clips provided.

Thank you for this referral. If the clinical or image interpretation does not parallel your findings or if I can be of any further assistance, please contact me.

Andrea Nicastro, MPH, DVM, Diplomate DACVIM (Small Animal Internal Medicine)
info@SonoPath.com