

**DATE PRESENTING CLINICAL SIGNS**

10/29/21 History: Chronic vomiting - recently hospitalized with high WBC, vomiting and diarrhea

PATIENT Current Medications: Amoxi 250mg BID 7d, Metronidazole 250mg BID 7d, Cerenia, Prilosec, gastro food, Proviable.

Oso Gills

Lab Results: WBC 36,000, returned to normal after 6 days, chem normal other than low chloride (vomiting), UA normal.

SPECIES

Canine

Radiographs: suspicious thickening of duodenum/proximal intestines?

BREED

Shih Tzu

Date of Previous IntraPet Ultrasound: No previous IntraPet scans.

Sedation: Not needed.

SEX

Male Neutered

Stat Report: Not requested.

ULTRASONOGRAPHIC EXAMINATION OF THE ABDOMEN**AGE**

9/5/11

Urinary System

The urinary bladder, trigone, and pelvic urethra are normal in thickness and the mucosal surface is smooth. The bladder lumen is moderately distended with anechoic urine. No masses, inflammatory changes or calculi are observed. Ureteral papillae and visualized portion of the proximal urethra, visible to a depth of 2 cm, are normal.

WEIGHT

23.1 lbs.

The prostate is normal in size (0.92 cm in width) and shape. Parenchyma is homogenous. The prostatic urethra appears normal without evidence of dilation or obstruction.

INTERPRETED BY

Andrea Nicastro, DVM,
Diplomate ACVIM
(Small Animal Internal
Medicine)

The left kidney is normal size (4.68 cm in length); normal shape and architecture with smooth peripheral margins. There is a normal 1:3 cortex to medulla ratio with minimal loss of corticomedullary distinction. A 0.61 cm focus of mineralization is observed in the cortex at the cranial pole. There is no evidence of pyelectasia, nephroliths, infarcts or hydroureter. Renal vasculature is normal.

HOSPITAL NAME

Hickory Veterinary
Hospital

The right kidney is normal size (4.47 cm in length); normal shape and architecture with smooth peripheral margins. There is a normal 1:3 cortex to medulla ratio with minimal loss of corticomedullary distinction. There is no evidence of pyelectasia, nephroliths, infarcts or hydroureter. Renal vasculature is normal.

REFERRING VET

Dr. Snyder

Adrenal Glands

The left adrenal gland is normal size (0.71 cm at cranial pole) (0.66 cm at caudal pole) (1.70 cm in length) with a normal shape and smooth peripheral contours. A 0.61 x 0.55 cm hyperechoic nodule is observed at the cranial pole. Glandular echogenicity and detail at the caudal pole are normal. The phrenicoabdominal vein and surrounding vasculature are normal.

INVOICE

11996kk

The right adrenal gland is normal size (0.76 cm at cranial pole) (0.68 cm at caudal pole) (2.97 cm in length); normal shape; homogenous parenchyma. The glandular echogenicity and detail are unremarkable. Capsule, cortex, and medullary definition are normal. The phrenicoabdominal vein and surrounding vasculature are normal.

Spleen

The spleen is normal in size (1.29 cm in width at the level of the hilus) with a normal capsular contour. There is appropriate echogenicity and echotexture. No focal lesions are observed. Splenic vasculature is normal.

Liver

The liver is subjectively normal in size with normal curvilinear peripheral contours. The parenchyma is hypoechoic relative to the spleen with minor changes consistent with age-related remodeling. No focal lesions are observed. Hepatic vasculature and biliary tracts are of normal volume with no evidence of congestion. The gall bladder lumen is moderately distended. The wall is thin and smooth. A few small, polypoid like lesions are arising from the luminal surface. Luminal contents are mostly anechoic. The cystic and common bile ducts are normal/not seen.

Gastrointestinal

The gastric lumen is mildly distended with fluid and gas. The gastric wall and pylorus are normal in thickness with a normal layering pattern. The pyloric outflow tract is patent. The small intestinal lumen is segmentally dilated with gas and chyme (mild). The small intestinal wall thickness is normal with a normal layering pattern and appropriate mural detail. Discreet masses are not identified. The colonic wall is normal. No obstructive disease is noted.

Pancreas

The region of the pancreas is isoechoic relative to surrounding omental fat. No obvious parenchymal abnormalities are observed. There is no evidence of regional inflammation or effusion.

Free Abdomen

The peritoneal cavity is normal. There is no evidence of inflammation or effusion. The abdominal lymph nodes are normal/not visible.

ULTRASONOGRAPHIC FINDINGS

Primary Findings:

- Mild gastric ileus.

**An obvious cause for the patient's clinical signs is not identified in the study. Differentials include primary microscopic gastrointestinal disease (i.e., food allergy, inflammatory bowel disease, infectious/parasitic), low-grade pancreatitis, underlying metabolic issue, and other.

Secondary Findings:

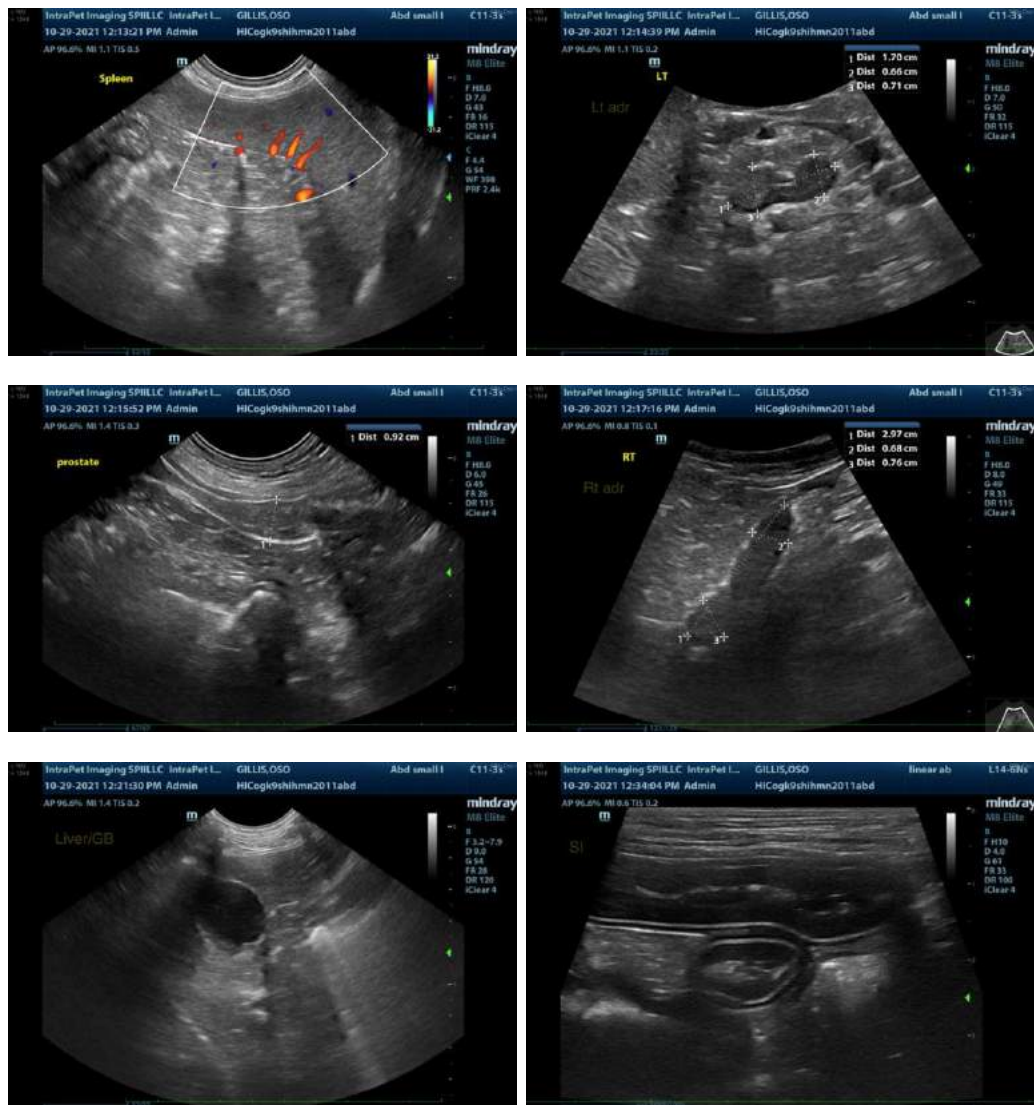
- Minor, age-related renal changes with left nephrolithiasis.
- The left adrenal nodule trends towards the benign (i.e., a focus of nodular hyperplasia) with a lower possibility of emerging neoplasia.
- The hepatic changes are consistent with age-related parenchymal remodeling and are not considered clinically significant at this time.

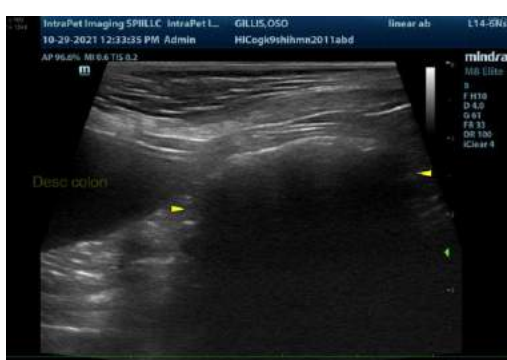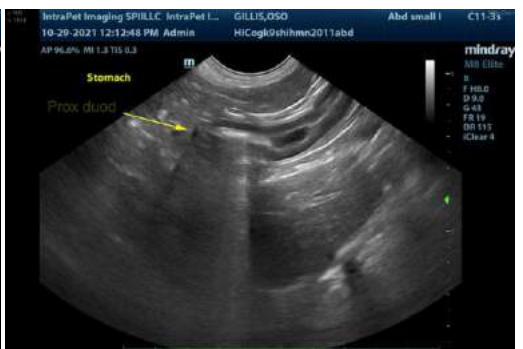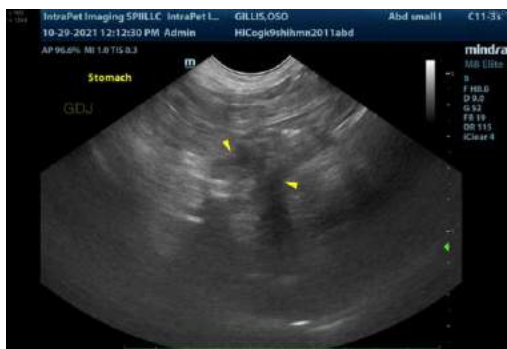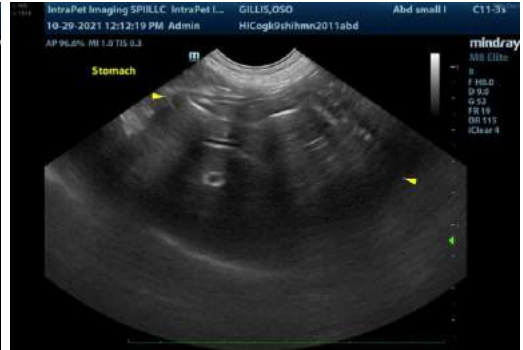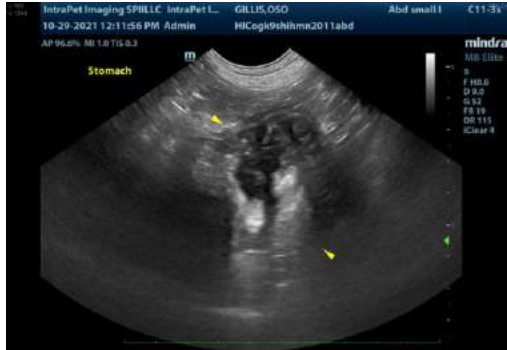INTERPRETATION OF THE FINDINGS & FURTHER RECOMMENDATIONS

The following diagnostics/treatment recommendations can be considered:

1. Serum cobalamin, folate, PLI and TLI
2. A fecal evaluation for ova/Giardia
3. Prophylactic deworming with Fenbendazole at 50 mg/kg once a day for 5 days is recommended. Repeat above protocol in 3 weeks.

4. A 6-week limited antigen diet trial to assess for food allergies.
5. Consider a 4-week course of Tylosin at 15-20 mg/kg by mouth every 12 hours as empirical treatment for small intestinal bacterial overgrowth.
6. A resting cortisol level to screen for hypoadrenocorticism. If resting cortisol level is < 2.0 mcg/dL, an ACTH stimulation test is recommended.
7. Depending on the results of the above diagnostics/therapeutics, endoscopic or surgical gastrointestinal biopsies may be warranted.
8. Three-view thoracic radiographs should be performed prior to any anesthetic event.





The information and recommendations provided are based on the images presented by the referring veterinarian. No evaluation can be communicated regarding pathology that was not visible in the image/video clips provided.

Thank you for this referral. If the clinical or image interpretation does not parallel your findings or if I can be of any further assistance, please contact me.

Andrea Nicastro, DVM, Diplomate ACVIM (*Small Animal Internal Medicine*)
Andrea.nicastro@sonopath.com