



PATIENT

Toby Piccolo

SPECIES

Canine

BREED

Miniature Schnauzer

SEX

Neutered Male

AGE

8 Years

WEIGHT

15.7 Pounds

INTERPRETED BY

Andrea Nicastro, DMV,
Diplomate DACVIM
(Small Animal
Internal Medicine)

**IMAGING
PERFORMED BY**

Kelly Vazquez

HOSPITAL NAME

North Jersey AH

REFERRING VET

Dr. Nancy Shaw

INVOICE

14043

DATE

10/28/21

PRESENTING CLINICAL SIGNS

History: Painful back end; hematuria. Current meds: Clavamox.
Abnormal PE/Chem/CBC/UA Results: USG: 1.036. - hematurria.

ULTRASONOGRAPHIC EXAMINATION OF THE ABDOMEN

Urinary System

The urinary bladder is moderately distended. The wall in the region of the apex is mildly thickened (up to 0.26 cm) with a smooth mucosal surface. As the wall extends toward the urinary bladder neck, it becomes progressively thickened (up to 0.57 cm), irregular and heterogeneous with foci of mineralization. This thickening and irregularity extends into the proximal urethra. Within the bladder lumen, a moderate amount of suspended echogenic debris is observed as well as a small amount of gravity dependent mineralized sand +/- tiny calculi.

The prostate is enlarged (1.85 cm in width) with a slightly irregular shape. The parenchyma is heterogeneous with foci of mineralization throughout the gland. A few cystic lesions are also seen. The mesentery surrounding the prostate is hyperechoic. The prostatic urethra is not overtly dilated. The post-prostatic urethral wall is subjectively thickened.

The left kidney presented normal size (3.87 cm in length); with a normal shape, smooth peripheral margins and normal internal architecture. There is minimal loss of corticomedullary distinction. Several hyperechoic shadowing diverticular foci are observed. There is no evidence of pyelectasia, infarcts or hydronephrosis. Renal vasculature is normal.

The right kidney presented normal size (4.05 cm in length); normal shape and architecture with smooth peripheral margins. There is a normal 1:3 cortex to medulla ratio with minimal to mild loss of corticomedullary distinction. There is no evidence of pyelectasia, nephroliths, infarcts or hydronephrosis. Renal vasculature is normal.

Adrenal Glands

The left adrenal gland is normal size (0.64 cm at cranial pole) (0.52 cm at caudal pole) (1.53 cm in length); normal shape; homogenous parenchyma. The glandular echogenicity and detail are unremarkable. Capsule, cortex, and medullary definition are normal. The phrenicoabdominal vein and surrounding vasculature are normal.

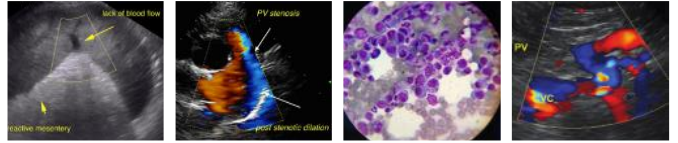
The right adrenal gland is mildly enlarged (1.05 cm at cranial pole) (0.83 cm at caudal pole) (1.33 cm in length); normal shape; homogenous parenchyma. The glandular echogenicity and detail are unremarkable. Capsule, cortex, and medullary definition are normal. The phrenicoabdominal vein and surrounding vasculature are normal.

Spleen

The spleen is normal in size (1.00 cm at the level of the hilus) with a normal capsular contour. There is appropriate echogenicity and echotexture. No focal lesions are observed. Splenic vasculature is normal.

Liver

The liver is subjectively normal in size with normal contours and structure. There is appropriate echogenicity and echotexture. No overt structural evidence of inflammatory, infiltrative or



PATIENT

Toby Piccolo

regenerative pathology is evident. Vascular and biliary tracts are of normal volume with no evidence of congestion. No pathological hepatic lymphadenopathy observed.

SPECIES

Canine

The gall bladder is of normal contours and contains some gravity dependent echogenic debris. The wall is normal in thickness. No choleliths are observed. The cystic and common bile ducts are normal/not seen.

BREED

Miniature Schnauzer

Gastrointestinal

The stomach and intestine are free of stasis and exhibit normal peristaltic activity. The gastric lumen is mildly distended with ingesta. The gastric wall and pylorus are normal in thickness with a normal layering pattern. The small intestinal lumen is not dilated. The small intestinal wall thickness is normal with a normal layering pattern and appropriate mural detail. Discreet masses are not identified. The colonic wall is normal. No obstructive or overt infiltrative disease is noted.

SEX

Neutered Male

Pancreas

The region of the pancreas is isoechoic relative to surrounding omental fat. No obvious parenchymal abnormalities are observed. There is no evidence of regional inflammation or effusion.

AGE

8 Years

Free Abdomen

There is no evidence of free fluid. 1-2 prominent to enlarged caudal abdominal lymph nodes are visualized, the largest measuring 1.81 cm x 0.67 cm).

WEIGHT

15.7 Pounds

ULTRASONOGRAPHIC FINDINGS

Primary Findings

- Prostatic mass effect with suspected extension into the proximal urethra and urinary bladder neck, neoplasia (i.e., prostatic adenocarcinoma, transitional cell carcinoma) is considered likely with a low possibility of a severe inflammatory process. Regional retroperitonitis is present.
- The prominent caudal abdominal lymph nodes may represent metastatic disease, reactive lymphadenitis or lymphoid hyperplasia.

INTERPRETED BY

Andrea Nicastro, DMV,
Diplomate DACVIM
(Small Animal
Internal Medicine)

**IMAGING
PERFORMED BY**

Kelly Vazquez

Secondary Findings

- Bilateral age-related renal changes with left dystrophic mineralization

HOSPITAL NAME

North Jersey AH

INTERPRETATION OF THE FINDINGS & FURTHER RECOMMENDATIONS

Three-view thoracic radiographs are also recommended to assess for pulmonary metastatic disease.

REFERRING VET

Dr. Nancy Shaw

A urine BRAF test is recommended to further assess for lower urinary tract neoplasia. If results are inconclusive or if an alternative test is desired, consider traumatic urethral catheterization with submission of the cells for cytology. If neoplasia is confirmed, and an aggressive approach is desired, consider consultation with a board-certified oncologist. If palliative care is recommended, consider the following protocol:

INVOICE

14043

DATE

10/28/21

1. Piroxicam at 0.3 mg/kg PO every 24 hours (may need to be compounded in smaller patients)



PATIENT

Toby Piccolo

2. Misoprostol (stomach protectant) at 2 mcg/kg PO every 12 hours

SPECIES

Canine

3. Baseline renal values should be performed then repeated every 4 weeks to monitor for nephrotoxicity

BREED

Miniature Schnauzer

***It should be noted that if prostatic adenocarcinoma is present, piroxicam is unlikely to be effective in reducing clinical signs.

SEX

Neutered Male

AGE

8 Years

WEIGHT

15.7 Pounds

INTERPRETED BY

Andrea Nicastro, DMV,
Diplomate DACVIM
(Small Animal
Internal Medicine)

IMAGING PERFORMED BY

Kelly Vazquez

HOSPITAL NAME

North Jersey AH

REFERRING VET

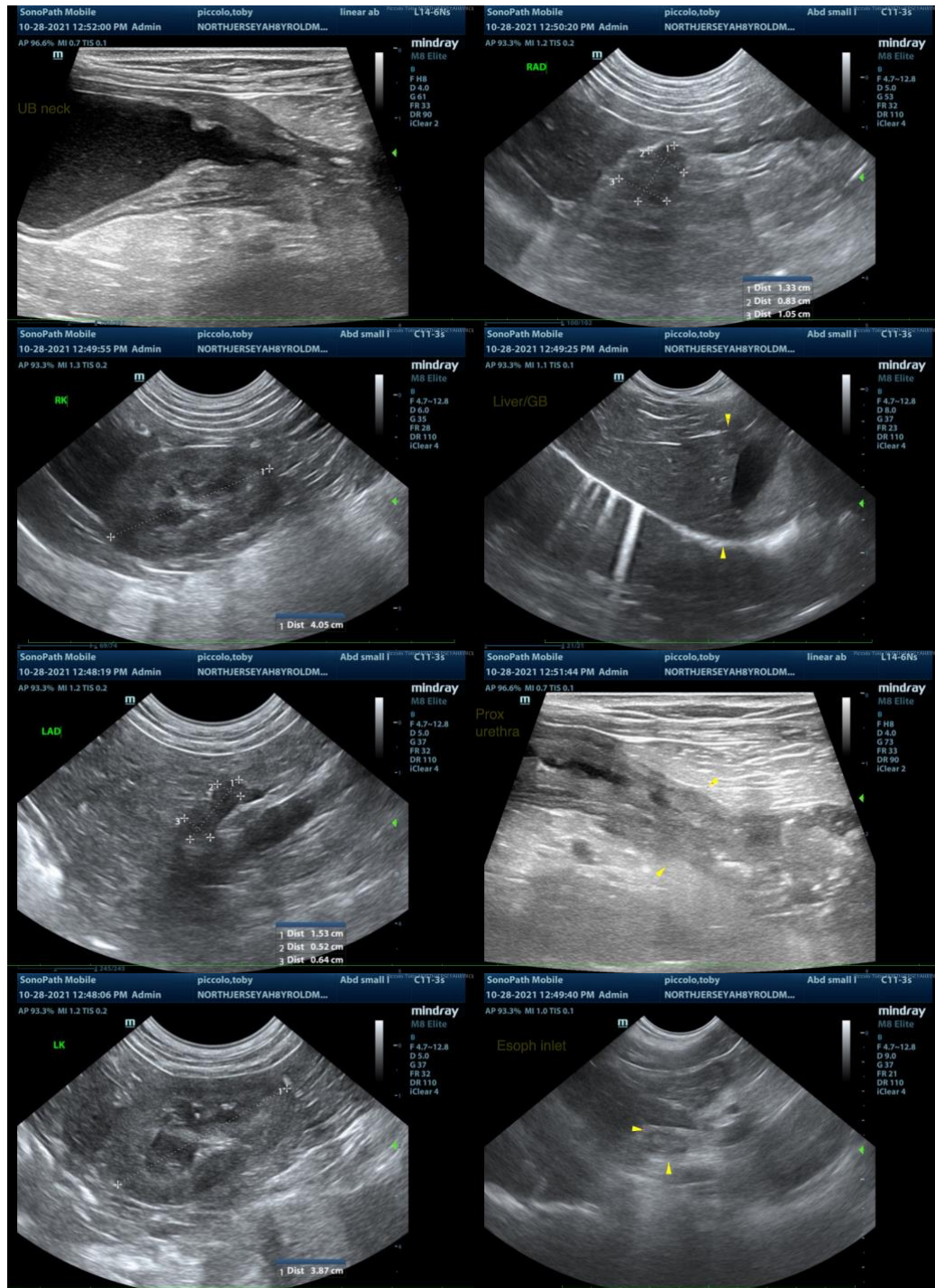
Dr. Nancy Shaw

INVOICE

14043

DATE

10/28/21





PATIENT

Toby Piccolo

SPECIES

Canine

BREED

Miniature Schnauzer

SEX

Neutered Male

AGE

8 Years

WEIGHT

15.7 Pounds

INTERPRETED BY

Andrea Nicastro, DMV,
Diplomate DACVIM
(Small Animal
Internal Medicine)

**IMAGING
PERFORMED BY**

Kelly Vazquez

HOSPITAL NAME

North Jersey AH

REFERRING VET

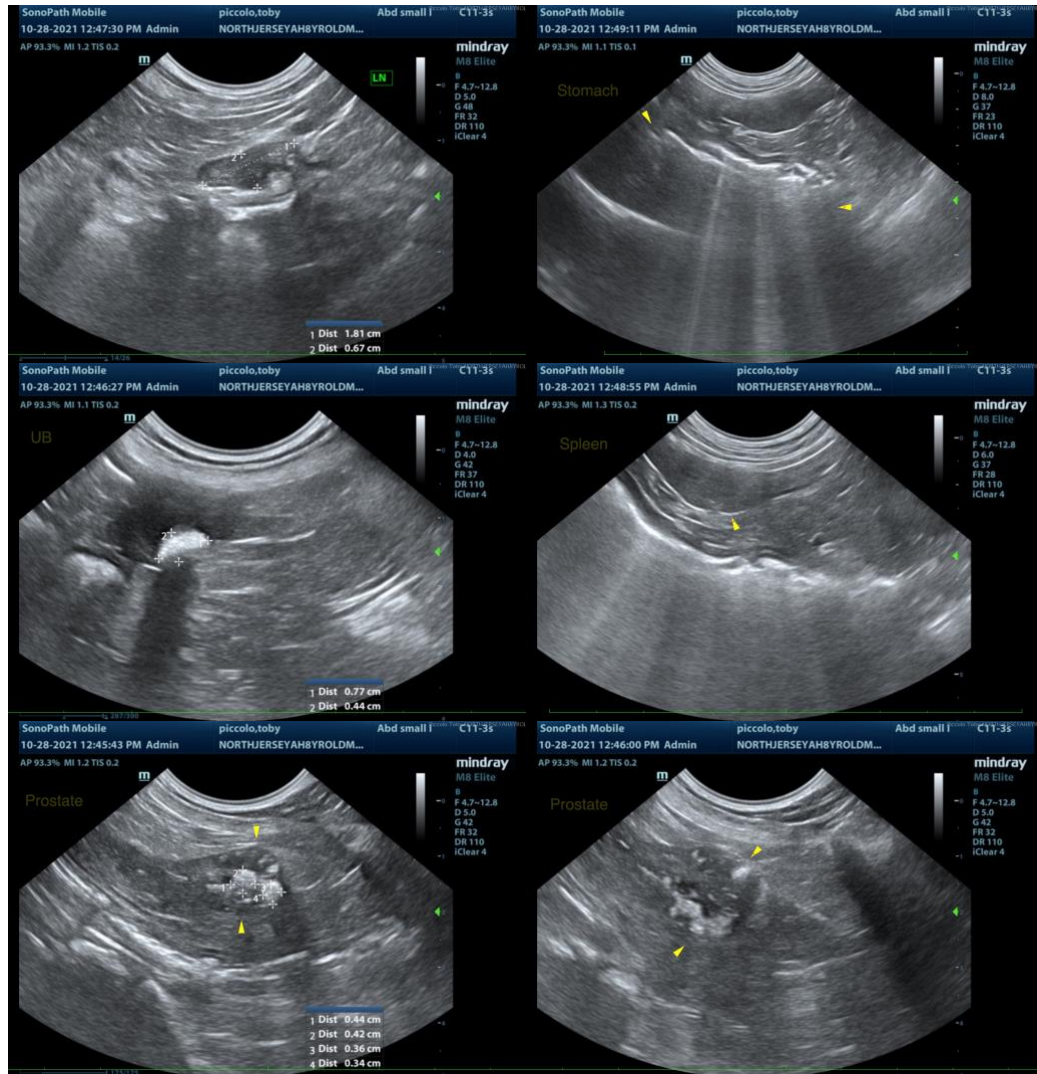
Dr. Nancy Shaw

INVOICE

14043

DATE

10/28/21



The information and recommendations provided are based on the images presented by the referring veterinarian. No evaluation can be communicated regarding pathology that was not visible in the image/video clips provided.

Thank you for this referral. If the clinical or image interpretation does not parallel your findings or if I can be of any further assistance please contact me.

Andrea Nicastro, DVM, Diplomate DACVIM (Small Animal Internal Medicine)
info@SonoPath.com