

**DATE PRESENTING CLINICAL SIGNS**

10/28/21

PATIENT

Karly Shaw

History: Diarrhea, 3 weeks, soft to watery, normal to increased frequency. Good appetite, no vomiting, acting well. Fecal exam 10/11 no parasites seen. CBC/superchem 10/26 wnl, O&P none seen, giardia negative. Metronidazole 250 mg bid 10/11-10/18, Fortiflora. Improved but signs recurred. Panacur 6 gm daily x 5 days started 10/25. Metronidazole 250 mg bid 10/28 restarted.

SPECIES

Canine

Current Medications: Metronidazole 250 mg bid 10/11-10/18, restart 10/28; Fortiflora; Panacur 6 gm daily x 5 days 10/25-10/29; Bland diet.

Lab Results: Fecal exam 10/11 no parasites seen. CBC/superchem 10/26 wnl, O&P none seen, giardia negative.

BREED

Labrador Retriever

Radiographs: gas in stomach, feces in intestine, spleen appears irregular.

Date of Previous IntraPet Ultrasound:

Sedation: IV sedative utilized for AUS

Stat Report: not requested

SEX

Spayed Female

ULTRASONOGRAPHIC EXAMINATION OF THE ABDOMEN**AGE**

4/1/2010

WEIGHT

60.4 Pounds

Urinary System

The urinary bladder, trigone, and pelvic urethra are normal in thickness and the mucosal surface is smooth. The bladder lumen is mildly distended with anechoic urine. No masses, inflammatory changes or calculi are observed. Ureteral papillae and visualized portion of the proximal urethra, visible to a depth of 2 cm, are normal.

INTERPRETED BY

Andrea Nicastro, DMV,
Diplomate DACVIM
(Small Animal
Internal Medicine)

The left kidney presented normal size (6.46 cm in length); normal shape and architecture with smooth peripheral margins. There is a normal 1:3 cortex to medulla ratio with normal corticomedullary distinction. There is no evidence of pyelectasia, nephroliths, infarcts or hydronephrosis. Renal vasculature is normal.

The right kidney presented normal size (6.22 cm in length); normal shape and architecture with smooth peripheral margins. There is a normal 1:3 cortex to medulla ratio with normal corticomedullary distinction. There is no evidence of pyelectasia, nephroliths, infarcts or hydronephrosis. Renal vasculature is normal.

HOSPITAL NAME

Jacksonville VC

REFERRING VET

Dr. Burk

Adrenal Glands

The left adrenal gland is normal size (0.93 cm at cranial pole) (0.63 cm at caudal pole) (2.85 cm in length); normal shape; homogenous parenchyma. The glandular echogenicity and detail are unremarkable. Capsule, cortex, and medullary definition are normal. The phrenicoabdominal vein and surrounding vasculature are normal.

INVOICE

14040

The right adrenal gland is normal size (0.67 cm at cranial pole) (0.76 cm at caudal pole) (2.75 cm in length); normal shape; homogenous parenchyma. The glandular echogenicity and detail are unremarkable. Capsule, cortex, and medullary definition are normal. The phrenicoabdominal vein and surrounding vasculature are normal.

Spleen

The spleen is subjectively normal in size (1.72 cm at the level of the hilus) with a scalloped medial contour. The parenchyma is diffusely mottled. A 2.10 cm hypoechoic nodule/area is observed near the hilus. In addition, several ill-defined hyperechoic nodules/areas are present. Splenic vasculature is normal with no evidence of thrombosis.

Liver

The liver is subjectively normal in size with normal contours and structure. There is appropriate echogenicity and echotexture. No overt structural evidence of inflammatory, infiltrative or regenerative pathology is evident. Vascular and biliary tracts are of normal volume with no evidence of congestion. No pathological hepatic lymphadenopathy observed.

The gall bladder is of normal contours and contains some gravity dependent echogenic debris. The wall is normal in thickness. No choleliths are observed. The cystic and common bile ducts are normal/not seen.

Gastrointestinal

The stomach and intestine are free of stasis and exhibit normal peristaltic activity. The gastric lumen is not distended. The gastric wall and pylorus are normal in thickness with a normal layering pattern. The small intestinal lumen is not dilated. The small intestinal wall thickness is normal with a normal layering pattern and appropriate mural detail. A >6.0 cm segment of descending colon (at the level of the bladder apex when mildly distended) is severely thickened with a mass effect. The wall in this region is thickened up to 1.23 cm with a complete loss of the normal layering pattern. The mesentery effacing the serosal surface is hyperechoic. There is no obvious evidence of an obstructive pattern.

Pancreas

The region of the pancreas is isoechoic relative to surrounding omental fat. No obvious parenchymal abnormalities are observed. There is no evidence of regional inflammation or effusion.

Free Abdomen

There is no evidence of free fluid. The abdominal lymph nodes are normal/not visible.

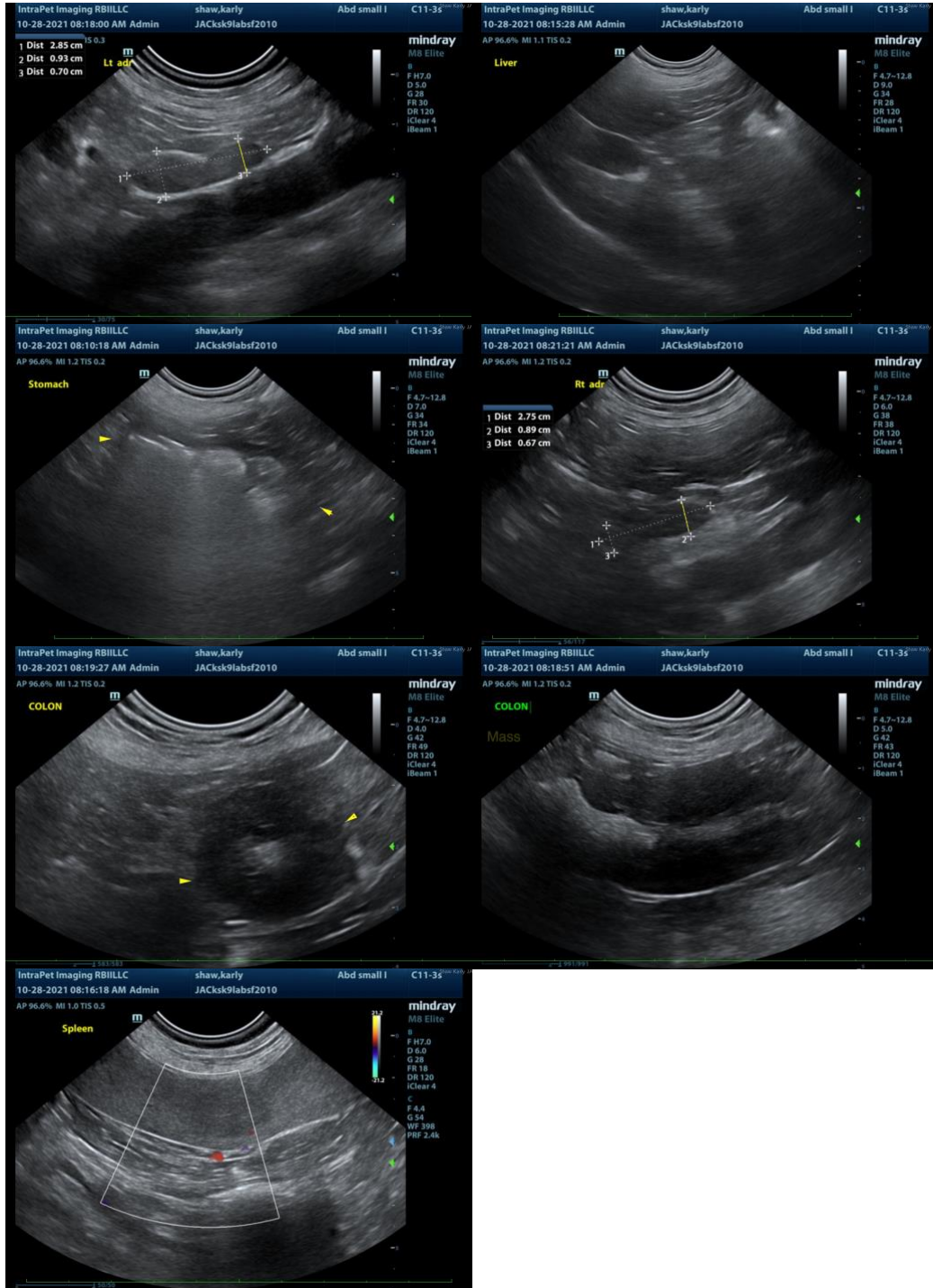
ULTRASONOGRAPHIC FINDINGS

Primary Findings

- Descending colonic wall mass. Neoplasia (i.e., adenocarcinoma, lymphoma) is considered likely with a low possibility of a severe inflammatory process (i.e., pyogranulomatous). Regional peritonitis is present.
- The splenic parenchymal changes could be consistent with infiltrative neoplasia, extramedullary hematopoiesis, lymphoid hyperplasia or splenitis.

INTERPRETATION OF THE FINDINGS & FURTHER RECOMMENDATIONS

- Three-view thoracic radiographs are recommended to assess for pulmonary metastases.
- If accessible, a fine needle aspirate of the colonic wall mass is recommended (if clotting status is normal). A 25-gauge needle should be used. Also consider a fine needle aspirate of the spleen. If cytology results are inconclusive, consider endoscopic or surgical colonic wall biopsies.



The information and recommendations provided are based on the images presented by the referring veterinarian. No evaluation can be communicated regarding pathology that was not visible in the image/video clips provided.

Thank you for this referral. If the clinical or image interpretation does not parallel your findings or if I can be of any further assistance please contact me.

Andrea Nicastro, DVM, Diplomate DACVIM (Small Animal Internal Medicine)
info@SonoPath.com