



PATIENT

Sophie Bozeman

SPECIES

Canine

BREED

Rat terrier mix

SEX

Female

AGE

15 Yrs.

WEIGHT

11.5 lbs.

INTERPRETED BY

Andrea Nicastro, DVM,
Diplomate ACVIM
(*Small Animal Internal
Medicine*)

**IMAGING
PERFORMED BY**

Dr. Lynette Reyes

HOSPITAL NAME

Chain of Lakes Animal
Clinic

REFERRING VET

Dr. Lynette Reyes

INVOICE

12432

DATE

10/27/21

PRESENTING CLINICAL SIGNS

History: Pet presented for dental cleaning and cyst removal. On PE noticed some blood-tinged discharge from her vulva, owner stated that pet was in heat 3 weeks ago. Radiographs were taken and pyometra is highly suspected, but there is also a soft tissue rounded mass in the right caudal dorsal abdomen. Owner prefers to confirm that there is nothing else besides pyometra since pet is geriatric. Thoracic rads were unremarkable
Abnormal PE/Chem/CBC/UA Results: From 10/07 Glob: 3.7 Plt: 419 To send BW to lab today

ULTRASONOGRAPHIC EXAMINATION OF THE ABDOMEN

Urinary System

The urinary bladder, trigone, and pelvic urethra are normal in thickness and the mucosal surface is smooth. The bladder lumen is moderately distended. A small amount of suspended echogenic debris is observed within the lumen. No masses, inflammatory changes or calculi are observed. Ureteral papillae and visualized portion of the proximal urethra, visible to a depth of 2 cm, are normal.

The left kidney is normal size (3.08 cm in length); normal shape and architecture with smooth peripheral margins. There is a normal 1:3 cortex to medulla ratio with minimal to mild loss of corticomedullary distinction. There is no evidence of pyelectasia, nephroliths, infarcts or hydroureter.

The right kidney is normal size (4.03 cm in length); normal shape and architecture with smooth peripheral margins. There is a normal 1:3 cortex to medulla ratio with minimal to mild loss of corticomedullary distinction. There is no evidence of pyelectasia, nephroliths, infarcts or hydroureter.

Adrenal Glands

The adrenal glands are not definitively visualized.

Spleen

The spleen is normal in size (0.70 cm in width at the level of the hilus) with a normal capsular contour. There is appropriate echogenicity and echotexture. No focal lesions are observed. Splenic vasculature is normal.

Liver

The liver is subjectively normal in size with normal curvilinear peripheral contours. The parenchyma is hypochoic relative to the spleen and has minor changes consistent with age-related remodeling. The parenchyma in the region of the gallbladder neck is difficult to evaluate due to imaging artifact. No distinct focal lesions are observed in other areas of the liver. Vascular and biliary tracts are of normal volume with no evidence of congestion. The gallbladder is of normal contours and contains some dependent echogenic debris. The wall is normal in thickness. No choleliths are observed. The cystic and common bile ducts are normal.

Gastrointestinal

The stomach and intestine are free of stasis and exhibit normal peristaltic activity. The gastric lumen is not distended. The gastric wall and pylorus are normal in thickness with a normal layering pattern. The pyloric outflow tract is patent. The small intestinal lumen is not dilated. The small intestinal wall thickness is normal with a normal layering pattern and appropriate mural detail. Discreet masses are not identified. The colonic wall is normal. No obstructive disease is noted.



PATIENT

Pancreas

Sophie Bozeman

The region of the pancreas is isoechoic relative to surrounding omental fat. No obvious parenchymal abnormalities are observed. There is no evidence of regional inflammation or effusion.

SPECIES

Free Abdomen

Canine

A 4.88 x 4.82 cm heterogeneous mass is observed in the mid to caudal abdomen. No free fluid is observed.

BREED

Rat terrier mix

Other

The uterine body and one uterine horn are visible and appear moderately dilated with echogenic fluid. The uterine body measures 0.85 cm in diameter. The uterine horn measures 0.94 cm in diameter.

SEX

Female

ULTRASONOGRAPHIC FINDINGS

Primary Findings:

- Mid to caudal abdominal mass, the origin of which is unclear. It may be arising from mesentery, lymph node, bowel, other. Neoplasia is considered likely with a lower possibility of benign pathology (i.e., inflammatory focus, granuloma).
- The uterine changes are most concerning for pyometra, although mucometra and hydrometra cannot be completely excluded.

Secondary Findings:

- Minor age-related renal pathology.

INTERPRETATION OF THE FINDINGS & FURTHER RECOMMENDATIONS

- Three-view thoracic radiographs are recommended to assess for pulmonary metastases.
- If an aggressive approach is desired, consider an abdominal exploratory with ovariohysterectomy and abdominal mass removal with submission for histopathology. If a more conservative approach is desired, consider a fine needle aspirate of the mass (if clotting status is appropriate). A 25-gauge needle should be used. Cytology should be submitted for stat results so that a decision can be made about an ovariohysterectomy ASAP.

INTERPRETED BY

Andrea Nicastro, DVM,
Diplomate ACVIM
(*Small Animal Internal
Medicine*)

**IMAGING
PERFORMED BY**

Dr. Lynette Reyes

HOSPITAL NAME

Chain of Lakes Animal
Clinic

REFERRING VET

Dr. Lynette Reyes

INVOICE

12432

DATE

10/27/21



PATIENT

Sophie Bozeman

SPECIES

Canine

BREED

Rat terrier mix

SEX

Female

AGE

15 Yrs.

WEIGHT

11.5 lbs.

INTERPRETED BY

Andrea Nicastro, DVM,
Diplomate ACVIM
(*Small Animal Internal
Medicine*)

**IMAGING
PERFORMED BY**

Dr. Lynette Reyes

HOSPITAL NAME

Chain of Lakes Animal
Clinic

REFERRING VET

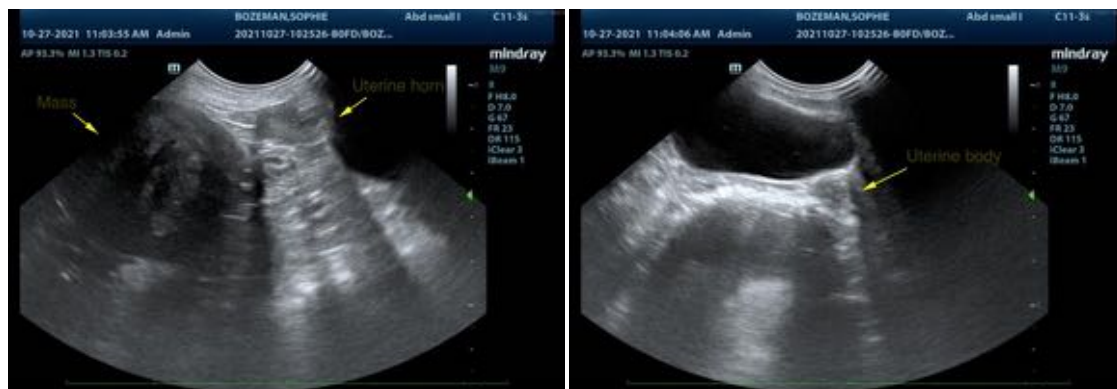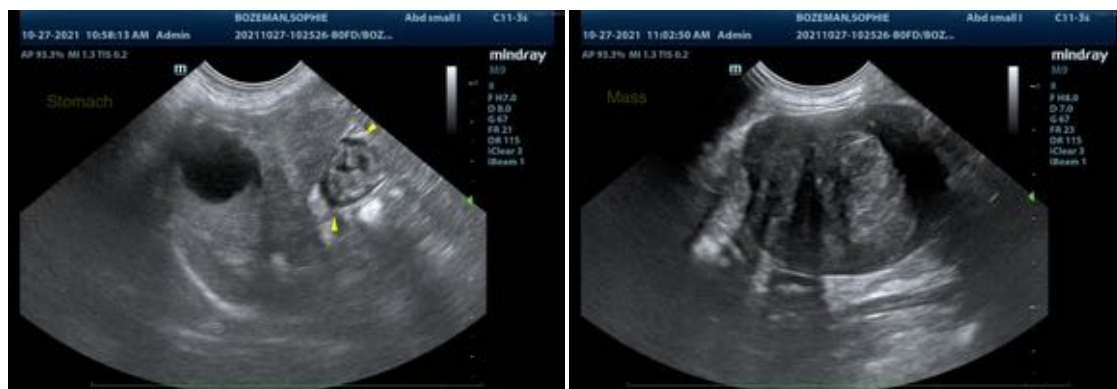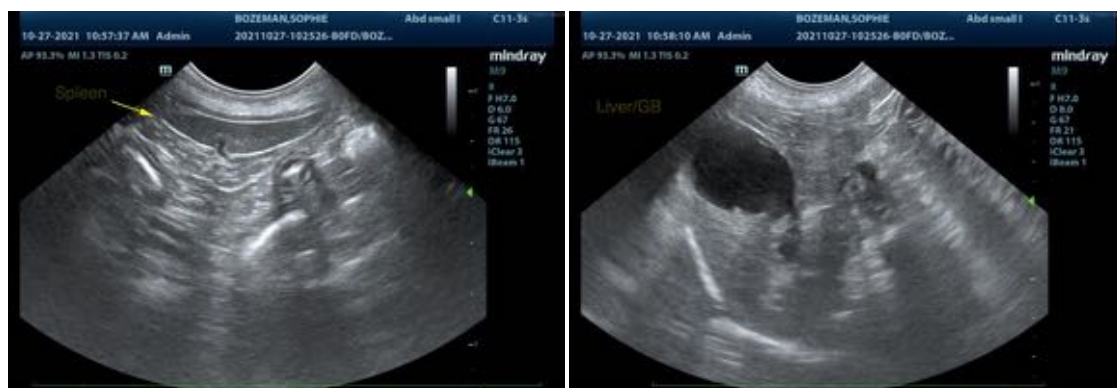
Dr. Lynette Reyes

INVOICE

12432

DATE

10/27/21



The information and recommendations provided are based on the images presented by the referring veterinarian. No evaluation can be communicated regarding pathology that was not visible in the image/video clips provided.

Thank you for this referral. If the clinical or image interpretation does not parallel your findings or if I can be of any further assistance please contact me.

Andrea Nicastro, DVM, Diplomate ACVIM (*Small Animal Internal Medicine*)

Andrea.nicastro@sonopath.com