

**DATE**

10.26.2022

PATIENT

Odie Papa

SPECIES

Canine

BREED

Cairn Terrier

SEX

Neutered Male

AGE

7/15/2006

WEIGHT

19.5lbs

INTERPRETED BY

Andrea Nicastro, DMV,
 Diplomate DACVIM
 (Small Animal
 Internal Medicine)

HOSPITAL NAME

Clarksville Pet Vet

REFERRING VET

Dr. Martof

INVOICE

11894

PRESENTING CLINICAL SIGNS

Dog presented for collapsing episode at ER over one month ago. High liver values were noted. Chest rads were taken. Dog was started on Denamarin and gabapentin (for possible pain). eating and drinking normally per o. Recheck liver values one month after starting Denamarin- show improvements in ALT. Alk phos basically same at 1400 and GGT increased to 129. also has heart murmur 3/6. anemia improving - hct 34%

Current Medications: Denamarin, gabapentin 100mg- 1 bid-tid

Lab Results: GGT 129. u/a: sg 1030 and +3 protein

Date of Previous IntraPet Ultrasound: No previous.

Sedation: Not required to complete full diagnostic ultrasound.

Stat Report: Not requested.

Imaging Performed By: Andi Parkinson, BS, RDMS.

ULTRASONOGRAPHIC EXAMINATION OF THE ABDOMEN**Urinary System**

The **urinary bladder** wall is normal in thickness and the mucosal surface is smooth. The bladder lumen is moderately distended with mostly anechoic urine. No masses, inflammatory changes or calculi are observed. Ureteral papillae and visualized portion of the proximal urethra, visible to a depth of 1-2 cm, are normal.

The **prostate** is normal in size (0.80 cm in width) and shape. Parenchyma is homogenous. The prostatic urethra appears normal without evidence of dilation or obstruction.

The **left kidney** is normal size (4.08 cm in length); with a slightly irregular shape. There is a normal 1:3 cortex to medulla ratio with moderate loss of corticomedullary distinction. A 1.78 cm cortical cyst is observed at the caudal pole. The cyst causes capsular expansion. Several nonobstructive nephroliths are visualized. There is no evidence of pyelectasia, infarcts or hydronephrosis.

The **right kidney** is normal size (4.89 cm in length); with a normal shape, smooth peripheral margins, and normal internal architecture. There is mild to moderate loss of corticomedullary distinction. Several hyperechoic shadowing diverticular foci are observed. There is no evidence of pyelectasia, infarcts or hydronephrosis.

Adrenal Glands

The **left adrenal gland** is mildly enlarged (0.52 cm at cranial pole) (0.65 cm at caudal pole) (2.02 cm in length); normal shape; homogenous parenchyma. The glandular echogenicity and detail are unremarkable. Capsule, cortex, and medullary definition are normal. The phrenicoabdominal vein and surrounding vasculature are normal.

The **right adrenal gland** is mildly enlarged (0.73 cm at cranial pole) (0.77 cm at caudal pole) (1.84 cm in length); normal shape; homogenous parenchyma. The glandular echogenicity and detail are unremarkable. Capsule, cortex, and medullary definition are normal. The phrenicoabdominal vein and surrounding vasculature are normal.

Spleen

The **spleen** is normal in size (1.03 cm in width at the level of the hilus) with a normal capsular contour. There is appropriate echogenicity and echotexture. No focal lesions are observed. Splenic vasculature is normal.

Liver

The **liver** is enlarged with irregular peripheral contours. An approximately 7.00 cm isoechoic to mildly hyperechoic mass is observed on the left side. The mass causes capsular expansion. On the right side, an approximately 7.00 cm cystic lesion is present. Within the cystic fluid, a small amount of suspended echogenic debris is observed. The remaining hepatic parenchyma is isoechoic relative to the spleen and is homogenous in appearance. Hepatic vasculature and intrahepatic biliary tracts are of normal volume with no evidence of congestion.

The **gall bladder** lumen is moderately distended. The wall is thin and smooth. A moderate amount of aggregated, echogenic, partially dependent debris/sludge is observed within the lumen. The cystic and common bile ducts are normal/not seen.

Gastrointestinal

The **gastric lumen** is mildly distended with shadowing ingesta. The gastric wall and pylorus are normal in thickness with a normal layering pattern. The small intestinal lumen is not dilated. The small intestinal wall thickness is normal with a normal layering pattern and appropriate mural detail. Discreet masses are not identified. The colonic wall is normal. There is no evidence of an obstructive pattern.

Pancreas

The region of the **pancreas** is isoechoic relative to surrounding omental fat. No obvious parenchymal abnormalities are observed. There is no evidence of regional inflammation or effusion.

Free Abdomen

The **peritoneal cavity** is normal. There is no evidence of inflammation or effusion. The abdominal **lymph nodes** are normal/not visible.

ULTRASONOGRAPHIC FINDINGS

Primary Findings

- Large, left hepatic mass. Differentials include adenoma, adenocarcinoma, round cell tumor, focus of vacuolar hepatopathy, other. The right cystic hepatic lesions trends toward the benign (i.e., cyst). However, abscessation or a tumor with a large necrotic area cannot be excluded.

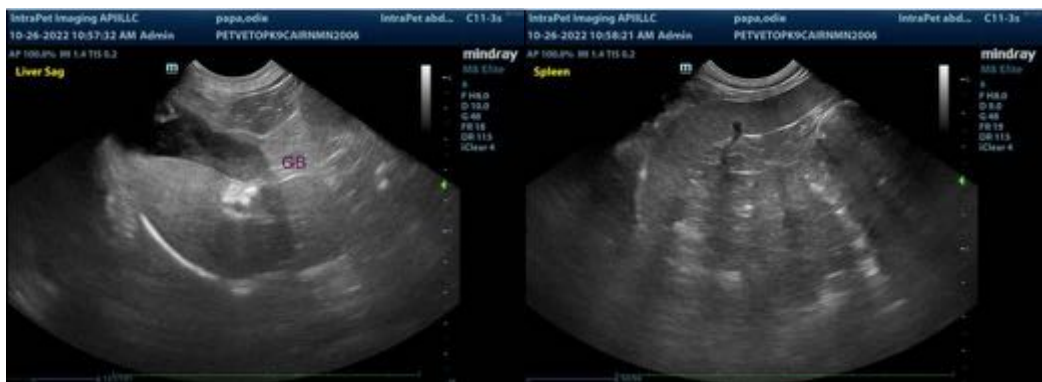
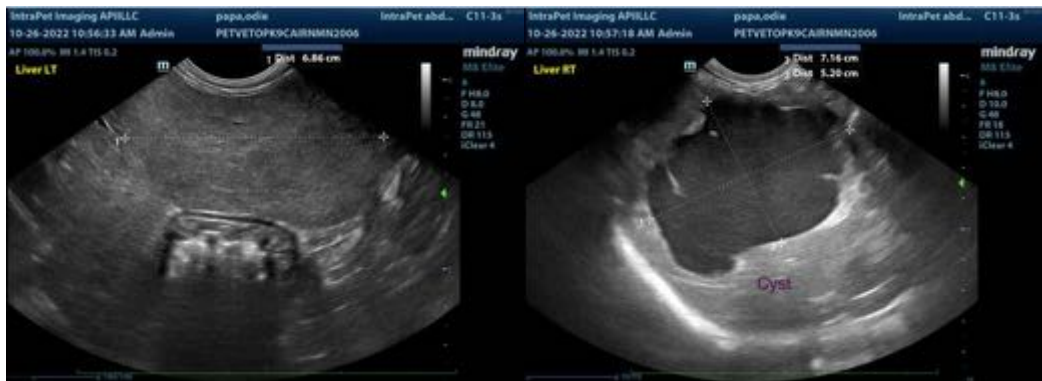
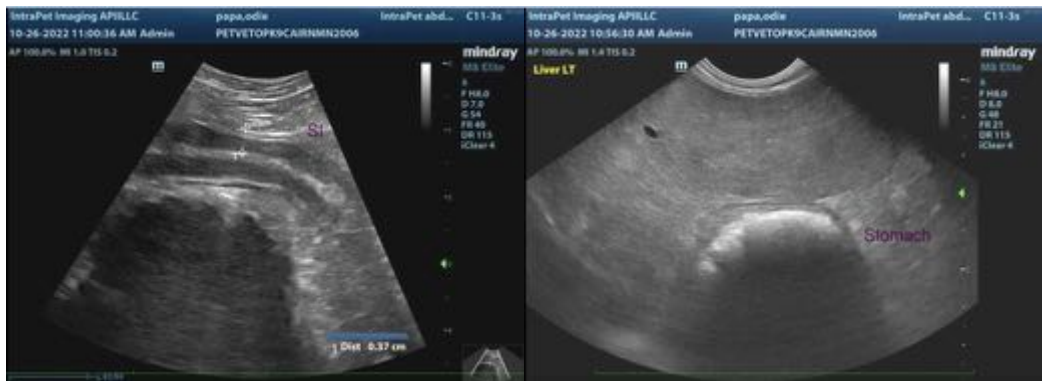Secondary Findings

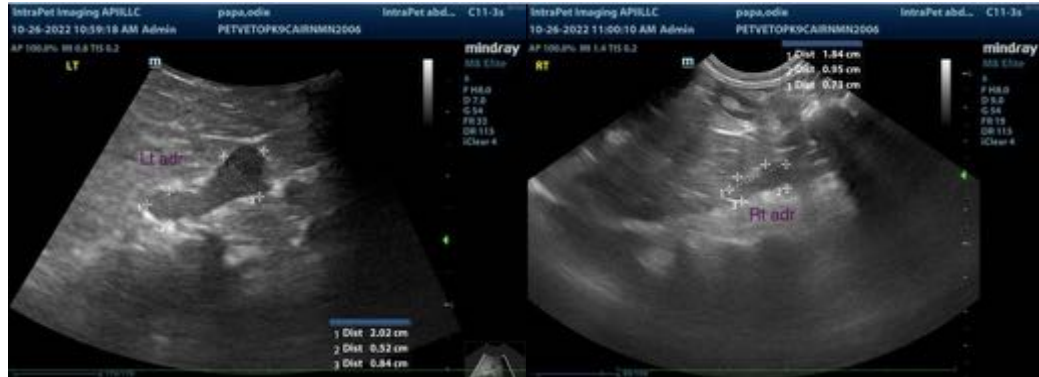- Bilateral degenerative renal changes with nonobstructive nephrocalcinosis and a left cortical cyst.
- The mild bilateral adrenomegaly may be a normal variant for this patient or may represent early hyperplastic change.
- The shadowing material within the gastric lumen may represent normal ingesta and/or foreign material. It appears nonobstructive at this time.
- The gall bladder sludge may be secondary to cholestasis, fasting or early mucocele formation.

INTERPRETATION OF THE FINDINGS & FURTHER RECOMMENDATIONS

Three-view thoracic radiographs are recommended to assess for pulmonary metastases.

Consider a fine-needle aspirate of the left hepatic mass if clotting status is appropriate. A 25-gauge needle should be used. If cytology results are inconclusive, and an aggressive approach is desired, consider surgical removal with submission for histopathology.





The information and recommendations provided are based on the images presented by the referring veterinarian/sonographer. No evaluation can be communicated regarding pathology that was not visible in the image/video clips provided.

Thank you for this referral. If the clinical or image interpretation does not parallel your findings or if I can be of any further assistance, please contact me.

Andrea Nicastro, MPH, DVM, Diplomate DACVIM (Small Animal Internal Medicine)
info@SonoPath.com