



PATIENT PRESENTING CLINICAL SIGNS

Rosie Schira
 History: Elevated liver enzymes, scheduled for skin mass removal and dental cleaning. In February we had ruled out Cushing's, but the ALT and ALP has risen more. Option of performing the surgery anyway +/- ultrasound, or ultrasound before surgery. Owner opted for ultrasound before surgery.

SPECIES

Canine

Abnormal PE/Chem/CBC/UA Results: CBC-normal Chemistry-ALT-203, was 139 ALP-917, was 460 February 2022. Cortisol - Baseline 3.8 µg/dL Cortisol - 4 hr Post Dex <0.5 µg/dL Cortisol - 8 hr Post Dex 0.8 µg/dL

BREED

Dachshund

ULTRASONOGRAPHIC EXAMINATION OF THE ABDOMEN

SEX

Spayed Female

Urinary System

The **urinary bladder** wall is normal in thickness and the mucosal surface is smooth. The bladder lumen is moderately distended with anechoic urine. No masses, inflammatory changes or calculi are observed. The region of the trigone and the visible portion of the proximal urethra are normal.

AGE

13 years

The **left kidney** is normal size (4.78 cm in length); normal shape and architecture with smooth peripheral margins. There is a normal 1:3 cortex to medulla ratio with mild to moderate loss of corticomedullary distinction. Trace pyelectasia is present. There is no evidence of nephroliths, infarcts or hydroureter. Renal vasculature is normal.

WEIGHT

23.2 lbs

The **right kidney** is normal size (5.06 cm in length); normal shape and architecture with smooth peripheral margins. There is a normal 1:3 cortex to medulla ratio with mild to moderate loss of corticomedullary distinction. Trace pyelectasia is present. There is no evidence of nephroliths, infarcts or hydroureter. Renal vasculature is normal.

INTERPRETED BY

Andrea Nicastro,
 DVM, Diplomate
 ACVIM (Small Animal
 Internal Medicine)

Adrenal Glands

The **left adrenal gland** is mildly enlarged (0.58 cm at cranial pole) (0.85 cm at caudal pole); normal shape; homogenous parenchyma. The glandular echogenicity and detail are unremarkable. Capsule, cortex, and medullary definition are normal. The phrenicoabdominal vein and surrounding vasculature are normal.

The **right adrenal gland** is normal in size (0.65 cm at cranial pole) (0.66 cm at caudal pole); normal shape; homogenous parenchyma. The glandular echogenicity and detail are unremarkable. Capsule, cortex, and medullary definition are normal. The phrenicoabdominal vein and surrounding vasculature are normal.

IMAGING PERFORMED BY

Chaley Hunt, LVT

Spleen

The **spleen** is normal in size (1.51 cm in width at the level of the hilus) with a normal capsular contour. There is appropriate echogenicity and echotexture. Several, small, irregular hyperechoic nodule are observed throughout the organ. Splenic vasculature is normal.

HOSPITAL NAME

Columbia AC

Liver

The **liver** is subjectively prominent in size with relatively normal curvilinear peripheral contours. The parenchyma is isoechoic relative to the spleen and mildly heterogenous in appearance, with several hyperechoic nodules/areas, the largest measuring 1.40 cm in diameter on the left side. This lesion causes slight capsular expansion. Hepatic vasculature and intrahepatic biliary tracts are of normal volume with no evidence of congestion.

REFERRING VET

Dr. Michelle Engel

INVOICE

11896

The **gall bladder** lumen is moderately distended. The wall is normal in thickness. Several polypoid-like lesions are observed along the luminal surface. A small amount of echogenic debris/sludge is observed within the lumen, some of which is adhered to the mucosal surface, and some of which is gravity dependent. The cystic and common bile ducts are normal/not seen.

DATE

10.26.22

Gastrointestinal

The **stomach and intestine** are free of stasis and exhibit normal peristaltic activity. The gastric lumen is not distended. The gastric wall and pylorus are normal in thickness with a normal layering pattern. The pyloric outflow tract is patent. The small intestinal lumen is not dilated. The small intestinal wall thickness is normal with a normal layering pattern and appropriate mural detail. Discreet masses are not identified. The colonic wall is normal. There is no evidence of an obstructive pattern.

Pancreas

The region of the **pancreas** is isoechoic relative to surrounding omental fat. No obvious parenchymal abnormalities are observed. There is no evidence of regional inflammation or effusion.

Free Abdomen

The **peritoneal cavity** is normal. There is no evidence of inflammation or effusion. The abdominal **lymph nodes** are normal/not visible.

ULTRASONOGRAPHIC FINDINGS

Primary Findings

- The diffuse hepatic changes are non-specific and could be consistent with vacuolar hepatopathy, regenerative nodular hyperplasia, and/or age-related remodeling. Inflammatory and infiltrative disease are considered less likely. The hyperechoic hepatic nodules/areas trends toward the benign (i.e., myelolipomas/lypogranulomas) with a lower possibility of emerging neoplasia. However, because the left hepatic nodule causes mild capsular expansion, additional evaluation/monitoring is recommended.

Secondary Findings

- The hyperechoic splenic nodules likely represent a benign process (i.e., myelolipomas).
- The mild left adrenomegaly may represent early hyperplastic change or may be a normal variant for this patient.
- Bilateral, chronic, age-related renal changes with trace pyelectasia

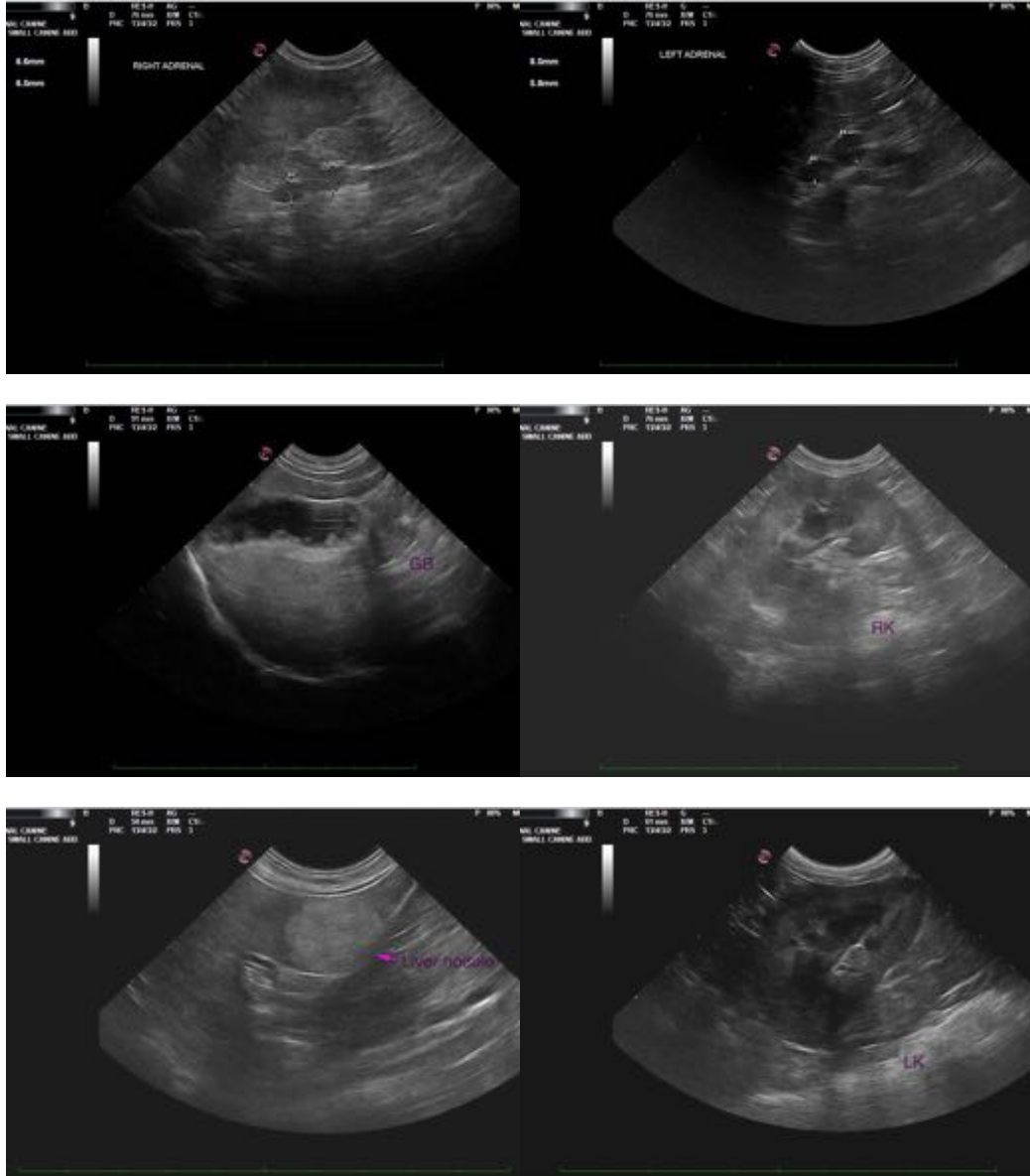
INTERPRETATION OF THE FINDINGS & FURTHER RECOMMENDATIONS

Serial monitoring (i.e, every 3-4 months) of the patient's liver values is recommended. If values continue to increase, a repeat abdomen ultrasound +/- a more advanced hepatic work-up (i.e., tissue sampling) may be warranted.

If the patient is exhibiting clinical signs of Cushing's Disease, and is isosthenuric, consider repeat testing (i.e., low-dose dexamethasone suppression test), as the previous results were inconclusive.

If the patient is to undergo anesthesia, benzodiazepine should be avoided, and opioids used judiciously.

Consider a fine-needle aspirate of the left hepatic nodule if clotting status is appropriate. A 25-gauge needle should be used.



The information and recommendations provided are based on the images presented by the referring veterinarian/sonographer. No evaluation can be communicated regarding pathology that was not visible in the image/video clips provided.

Thank you for this referral. If the clinical or image interpretation does not parallel your findings or if I can be of any further assistance, please contact me.

Andrea Nicastro, MPH, DVM, Diplomate DACVIM (Small Animal Internal Medicine)
info@SonoPath.com

