

PATIENT

Pepper Joseph

PRESENTING CLINICAL SIGNS

Recheck prev u/s showed over distended stomach with chyme delayed outflow gastric pattern , dog is doing well.

SPECIES

Canine

ULTRASONOGRAPHIC EXAMINATION OF THE ABDOMEN

**This study was limited. There is a potential for pathology in organs that were not visualized.

BREED

Pit mix

Gastrointestinal Tract

The stomach is moderately distended with ingesta and a few small hyperechoic shadowing structures. The gastric wall is normal in thickness with a normal layering pattern and appropriate mural detail.

SEX

Female spayed

Other

AGE

8 Yrs.

The visible portion of the portion of the liver is subjectively normal in size with normal curvilinear peripheral contours and homogeneous parenchyma. No focal lesions are observed. Hepatic vasculature and intrahepatic biliary tracts are of normal volume with no evidence of congestion. The gallbladder is of normal contours and contains some dependent echogenic debris. The wall is normal in thickness. No choleliths are observed. The cystic and common bile ducts are normal.

WEIGHT

46 lbs.

ULTRASONOGRAPHIC FINDINGS

INTERPRETED BY

Andrea Nicastro, DVM,
Diplomate ACVIM
(*Small Animal Internal
Medicine*)

- The presence of ingesta in the gastric lumen despite fasting is suggestive of delayed gastric emptying. There is no obvious evidence of an obstruction. However, a small pyloric obstruction cannot be completely excluded. In the absence of vomiting, however, a foreign body is considered unlikely.

INTERPRETATION OF THE FINDINGS & FURTHER RECOMMENDATIONS

- Consider obtaining additional sonographic images of the pyloric region (SDEP 13 and 14).
- If the patient is clinically doing well, continued supportive care for gastroenteritis is recommended as needed. However, if vomiting persists or recurs, additional diagnostics (i.e., barium study, upper GI endoscopy or abdominal CT scan) may be warranted to further evaluate the pyloric outflow tract.

IMAGING PERFORMED BY

Jenn

HOSPITAL NAME

Rockaway

REFERRING VET

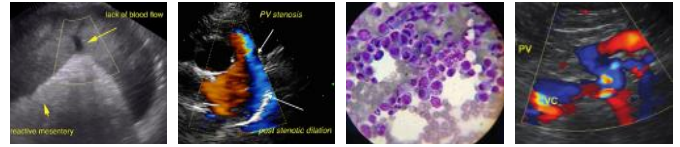
Dr. Maniar

INVOICE

14156

DATE

10/26/22



PATIENT

Pepper Joseph

SPECIES

Canine

BREED

Pit mix

SEX

Female spayed

AGE

8 Yrs.

WEIGHT

46 lbs.

INTERPRETED BY

Andrea Nicastro, DVM,
Diplomate ACVIM
(Small Animal Internal
Medicine)

**IMAGING
PERFORMED BY**

Jenn

HOSPITAL NAME

Rockaway

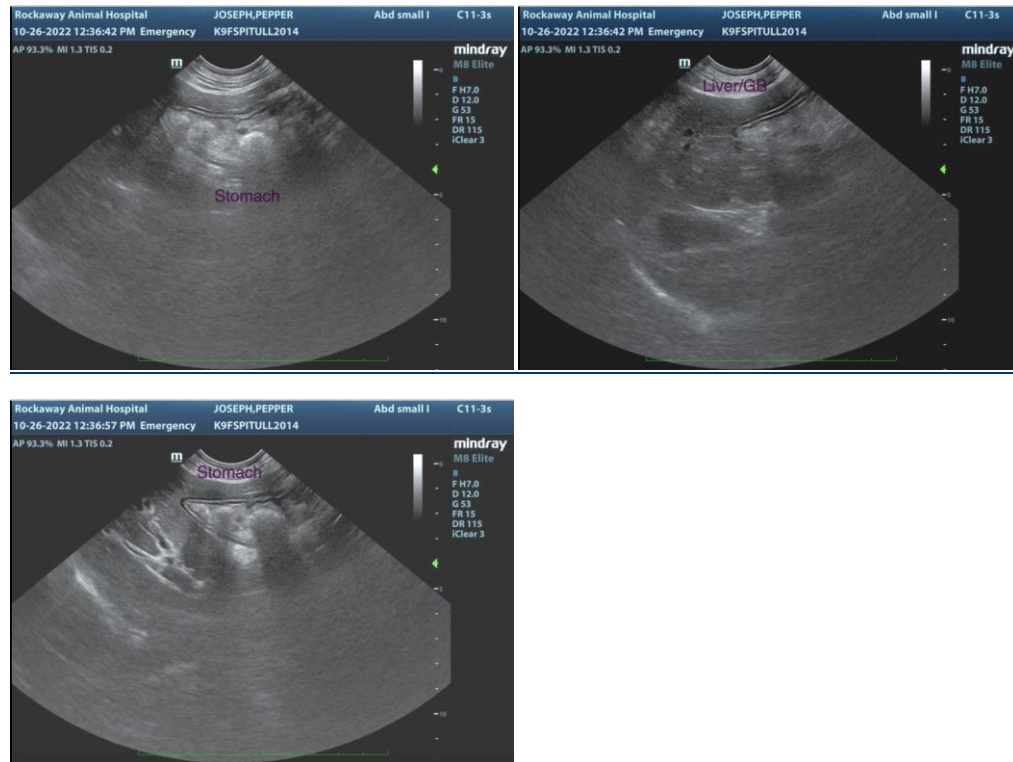REFERRING VET

Dr. Maniar

INVOICE

14156

DATE
10/26/22



The information and recommendations provided are based on the images presented by the referring veterinarian/sonographer. No evaluation can be communicated regarding pathology that was not visible in the image/video clips provided.

Thank you for this referral. If the clinical or image interpretation does not parallel your findings or if I can be of any further assistance please contact me.

Andrea Nicastro, MPH, DVM, Diplomate DACVIM (Small Animal Internal Medicine)
info@SonoPath.com