

**DATE PRESENTING CLINICAL SIGNS**

10/24/22

Recheck US; liver values still elevated; Vaccines 10/12/22- BARH, weight stable; appears healthy for age. O has no concerns (except urination in house occas, did have hx of UTI last spring).

PATIENT

Jodi Pazourek

Current Medications: Liver Diet, Sentinel, Bravecto

Lab Results: ALT- 444, SAP- 351, AST- 91

Date of Previous IntraPet Ultrasound: 4/11/22. See attached.

Sedation: Not required to complete full diagnostic ultrasound.

Stat Report: Not requested.

SPECIES

Canine

Imaging Performed By: Stephanie Warga RDCS, RVT.

BREED

Dachshund

ULTRASONOGRAPHIC EXAMINATION OF THE ABDOMEN**Urinary System**

The urinary bladder wall is normal in thickness and the mucosal surface is smooth. The bladder lumen is moderately distended with mostly anechoic urine. No masses, inflammatory changes or calculi are observed. The region of the trigone is normal.

SEX

Female, spayed

The left kidney is normal size (5.52 cm in length); normal shape and architecture with smooth peripheral margins. The cortex is hyperechoic. There is a normal 1:3 cortex to medulla ratio with mild loss of corticomedullary distinction. There is no evidence of pyelectasia, nephroliths, infarcts or hydroureter. Renal vasculature is normal.

AGE

10/22/2010

The right kidney is normal size (4.64 cm in length); normal shape and architecture with smooth peripheral margins. The cortex is hyperechoic. There is a normal 1:3 cortex to medulla ratio with mild loss of corticomedullary distinction. There is no evidence of pyelectasia, nephroliths, infarcts or hydroureter. Renal vasculature is normal.

WEIGHT

18.1 lbs.

INTERPRETED BY

Andrea Nicastro, DVM,
Diplomate ACVIM
(Small Animal Internal
Medicine)

Adrenal Glands

The left adrenal gland is normal size (0.43 cm at cranial pole) (0.53 cm at caudal pole) (2.70 cm in length); normal shape; homogenous parenchyma. The glandular echogenicity and detail are unremarkable. Capsule, cortex, and medullary definition are normal. The phrenicoabdominal vein and surrounding vasculature are normal.

HOSPITAL NAME

Essex Middle River VC

The right adrenal gland is normal size (0.54 cm at cranial pole) (0.55 cm at caudal pole) (2.34 cm in length); normal shape; homogenous parenchyma. The glandular echogenicity and detail are unremarkable. Capsule, cortex, and medullary definition are normal. The phrenicoabdominal vein and surrounding vasculature are normal.

REFERRING VET

Dr. Hicks

Spleen

The spleen is normal in size (1.31 cm in width at the level of the hilus) with a normal capsular contour. There is appropriate echogenicity and echotexture. At least one small ill-defined myelolipomas are observed in the region of the hilus. Splenic vasculature is normal.

INVOICE

14129

Liver

The liver is prominent to enlarged with swollen peripheral contours. The parenchyma is isoechoic relative to the spleen and exhibits subtle heterogeneity. On the left side, a 2.88 x 1.87 cm hypoechoic nodule/area is visualized at the caudal aspect. The lesion causes slight capsular expansion. Vascular and biliary tracts are of normal volume with no evidence of congestion. The portal vein: caudal vena cava ratio is approximately 1:1. The gall bladder lumen is moderately distended. The wall is thin and smooth. A small amount of aggregated, echogenic partially dependent to suspended sludge is observed within the lumen. The cystic and common bile ducts are normal/not seen.

Gastrointestinal

The gastric lumen is not distended. The gastric wall and pylorus are normal in thickness with a normal layering pattern. The pyloric outflow tract is patent. The small intestinal lumen is not dilated. The small intestinal wall is normal to borderline thickened (up to 0.41 cm) with retention of the normal layering pattern. There is evidence of mucosal speckling and striations in several segments. Discreet masses are not identified. The colonic wall is normal. No obstructive disease is noted.

Pancreas

The right limb of the pancreas is visible with normal curvilinear peripheral contours. The parenchyma is largely isoechoic relative to surrounding omental fat and slightly mottled in appearance. The pancreatic duct is visible but not overtly dilated. There is no evidence of peripancreatic inflammation or effusion.

Free Abdomen

The peritoneal cavity is normal. There is no evidence of inflammation or effusion. The abdominal lymph nodes are normal/not visible.

Other

A uterine stump is visible measuring 0.43 cm in width. No obvious pathology is seen.

An area of reactive mesentery is observed within the mid-abdominal region. There is no obvious evidence of free fluid.

ULTRASONOGRAPHIC FINDINGS

Primary Findings:

- Non-specific diffuse hepatopathy with a left caudal nodule. Changes are similar to the previous sonogram. Differentials include inflammatory hepatopathy (i.e., chronic hepatitis, bacterial cholangiohepatitis), hepatotoxicosis (i.e., copper), reactive hepatopathy, other +/- concurrent benign age-related change (i.e., regenerative nodular hyperplasia and/or vacuolar hepatopathy).
- Gallbladder debris- non-mucocele.

Secondary Findings:

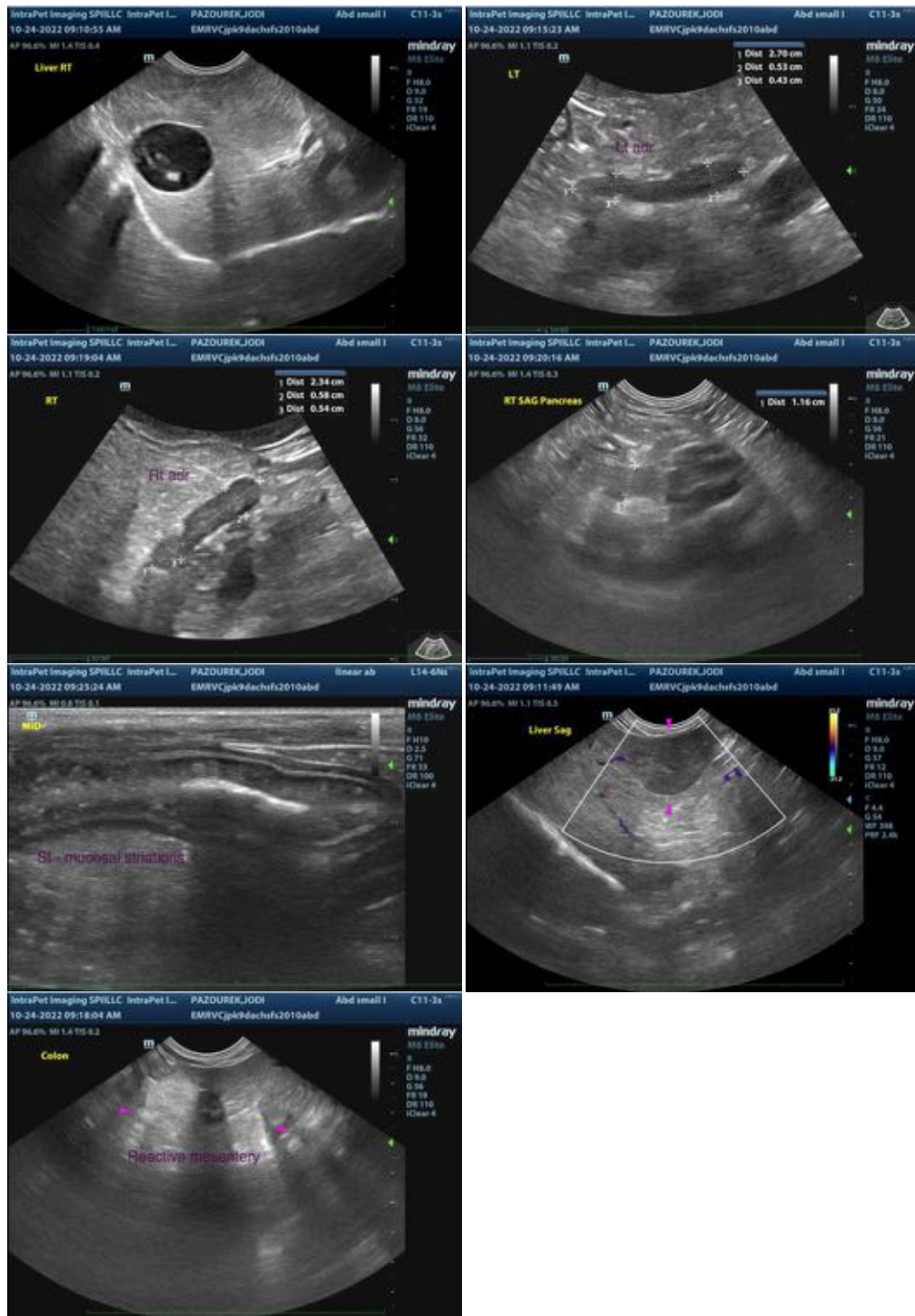
- Bilateral, chronic age-related renal changes.
- Age-related pancreatic remodeling. Changes are similar to the previous sonogram.
- Bowel pattern consistent with a chronic enteropathy (i.e., lymphangiectasia, inflammatory bowel disease, other). Changes are similar to the previous sonogram.
- The reactive mesentery in the mid-abdominal region is likely secondary to underlying bowel pathology. Changes are similar to the previous sonogram.
- Gallbladder debris, non-mucocele. Changes are similar to the previous sonogram.

INTERPRETATION OF THE FINDINGS & FURTHER RECOMMENDATIONS

- To further investigate the hepatic pathology, consider hepatic tissue sampling (i.e., fine needle aspirate or surgical biopsies). Biopsies would be ideal in that samples from multiple lobes can be obtained and the nodule can be removed and submitted for histopathology. If biopsies are pursued, aerobic and anaerobic bile cultures should be performed as well as copper quantitation. If hepatic

tissue sampling is not pursued at this time, consider hepatic antioxidants with serial monitoring (i.e., every 3 months) of the patient's liver values to assess for progression.

- If the patient develops gastrointestinal signs, further workup should be considered.



The information and recommendations provided are based on the images presented by the referring veterinarian. No evaluation can be communicated regarding pathology that was not visible in the image/video clips provided.

Thank you for this referral. If the clinical or image interpretation does not parallel your findings or if I can be of any further assistance please contact me.

Andrea Nicastro, MPH, DVM, Diplomate DACVIM (Small Animal Internal Medicine)
info@SonoPath.com