



PATIENT PRESENTING CLINICAL SIGNS

Ella Bucci History: Owner has concerns that Ella is very thin. Has a poor appetite even though lots of energy. Fecal negative. No meds. All blood and urinalysis tests have been normal, no obvious cause of lean body condition. Has also tried different diets.

SPECIES

Canine

Abnormal PE/Chem/CBC/UA Results: TLI 46.2 (5-35).

ULTRASONOGRAPHIC EXAMINATION OF THE ABDOMEN

BREED

Doodle

Urinary System

The **urinary bladder** wall is normal in thickness and the mucosal surface is smooth. The bladder lumen is mildly distended with anechoic urine. No masses, inflammatory changes or calculi are observed. The region of the trigone is normal.

SEX

Spayed Female

The **left kidney** is normal size (5.35 cm in length); normal shape and architecture with smooth peripheral margins. There is a normal 1:3 cortex to medulla ratio with normal corticomedullary distinction. A hyperechoic medullary band is observed adjacent to corticomedullary junction. There is no evidence of pyelectasia, nephroliths, infarcts or hydroureter. Renal vasculature is normal.

AGE

3 years

The **right kidney** is normal size (5.97 cm in length); normal shape and architecture with smooth peripheral margins. There is a normal 1:3 cortex to medulla ratio with normal corticomedullary distinction. A hyperechoic medullary band is observed adjacent to corticomedullary junction. There is no evidence of pyelectasia, nephroliths, infarcts or hydroureter. Renal vasculature is normal.

WEIGHT

19.1 kg

Adrenal Glands

The **left adrenal gland** is normal size (0.44 cm at cranial pole) (0.42 cm at caudal pole) (2.15 cm in length); normal shape; homogenous parenchyma. The glandular echogenicity and detail are unremarkable. Capsule, cortex, and medullary definition are normal. The phrenicoabdominal vein and surrounding vasculature are normal.

INTERPRETED BY

Andrea Nicastro, DVM,
Diplomate ACVIM
(Small Animal Internal
Medicine)

The **right adrenal gland** is normal size (0.91 cm at cranial pole) (0.68 cm at caudal pole) (2.04 cm in length); normal shape; homogenous parenchyma. The glandular echogenicity and detail are unremarkable. Capsule, cortex, and medullary definition are normal. The phrenicoabdominal vein and surrounding vasculature are normal.

IMAGING PERFORMED BY

Crystal Hill

Spleen

The **spleen** is normal in size (1.77 cm in width at the level of the hilus) with a normal capsular contour. There is appropriate echogenicity and echotexture. No focal lesions are observed. Splenic vasculature is normal.

HOSPITAL NAME

Hillview VC

Liver

The **liver** is subjectively normal in size with normal contours and structure. There is appropriate echogenicity and echotexture. No overt structural evidence of inflammatory, infiltrative, or regenerative pathology is evident. Vascular and biliary tracts are of normal volume with no evidence of congestion. No pathological hepatic lymphadenopathy observed.

REFERRING VET

Dr. Stevenson

The **gall bladder** lumen is moderately distended. The wall is thin and smooth. Luminal contents are anechoic. The cystic and common bile ducts are normal/not seen.

INVOICE

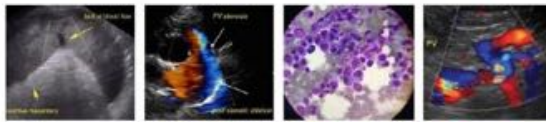
11862

Gastrointestinal

The **gastric lumen** is not distended. The gastric wall is normal in thickness with a normal layering pattern. The small intestinal lumen is not dilated with chyme. The small intestinal wall thickness is normal with a normal layering pattern and appropriate mural detail. Discreet masses are not identified. The colonic wall is normal. There is no evidence of an obstructive pattern.

DATE

10.20.22



PATIENT

Ella Bucci

Pancreas

The region of the **pancreas** is isoechoic relative to surrounding omental fat. No obvious parenchymal abnormalities are observed. There is no evidence of regional inflammation or effusion.

SPECIES

Canine

Free Abdomen

The **peritoneal cavity** is normal. There is no evidence of inflammation or effusion. The abdominal **lymph nodes** are normal/not visible.

ULTRASONOGRAPHIC FINDINGS

BREED

Doodle

Primary Findings

- The medullary band seen in both kidneys may be a normal variant for this patient or may represent subclinical renal disease.

SEX

Spayed Female

*An obvious cause for the patient's hyporexia and weight loss is not identified in this study. Considerations include maldigestion/malabsorption, occult neoplasia, underlying metabolic issue, orthopedic or neurologic disease, other.

AGE

3 years

INTERPRETATION OF THE FINDINGS & FURTHER RECOMMENDATIONS

Three-view thoracic radiographs are recommended to assess for occult disease in the chest.

WEIGHT

19.1 kg

Other diagnostic considerations include the following:

- A malabsorption GI panel including serum cobalamin and folate, TLI and PLI (send to Texas A&M) is recommended.
- Consider a resting cortisol level to screen for hypoadrenocorticism.
- Thorough neurologic and orthopedic evaluations are recommended to assess for nonmetabolic causes for the patient's clinical signs.
- Depending on the results of the above diagnostics, GI biopsies (i.e., endoscopic, or surgical) may be necessary to get a definitive diagnosis.

INTERPRETED BY

Andrea Nicastro, DVM,
Diplomate ACVIM
(Small Animal Internal
Medicine)

IMAGING PERFORMED BY

Crystal Hill

HOSPITAL NAME

Hillview VC

REFERRING VET

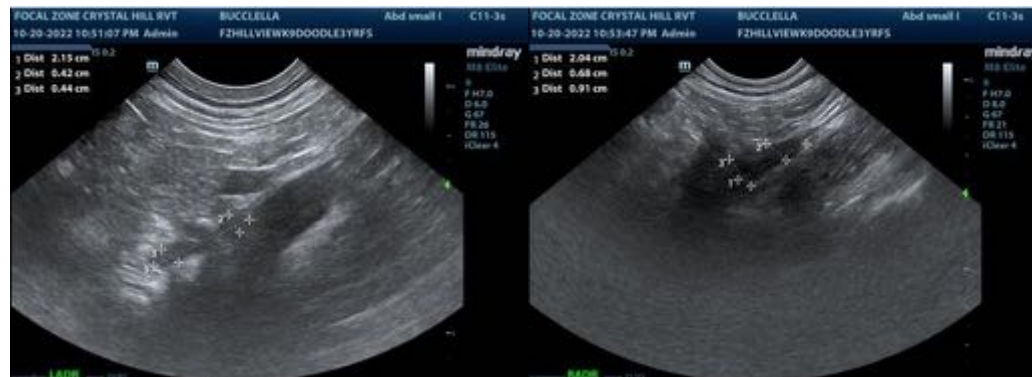Dr. Stevenson

INVOICE

11862

DATE

10.20.22





PATIENT

Ella Bucci

SPECIES

Canine

BREED

Doodle

SEX

Spayed Female

AGE

3 years

WEIGHT

19.1 kg

INTERPRETED BY

Andrea Nicastro, DVM,
Diplomate ACVIM
(Small Animal Internal
Medicine)

**IMAGING
PERFORMED BY**

Crystal Hill

HOSPITAL NAME

Hillview VC

REFERRING VET

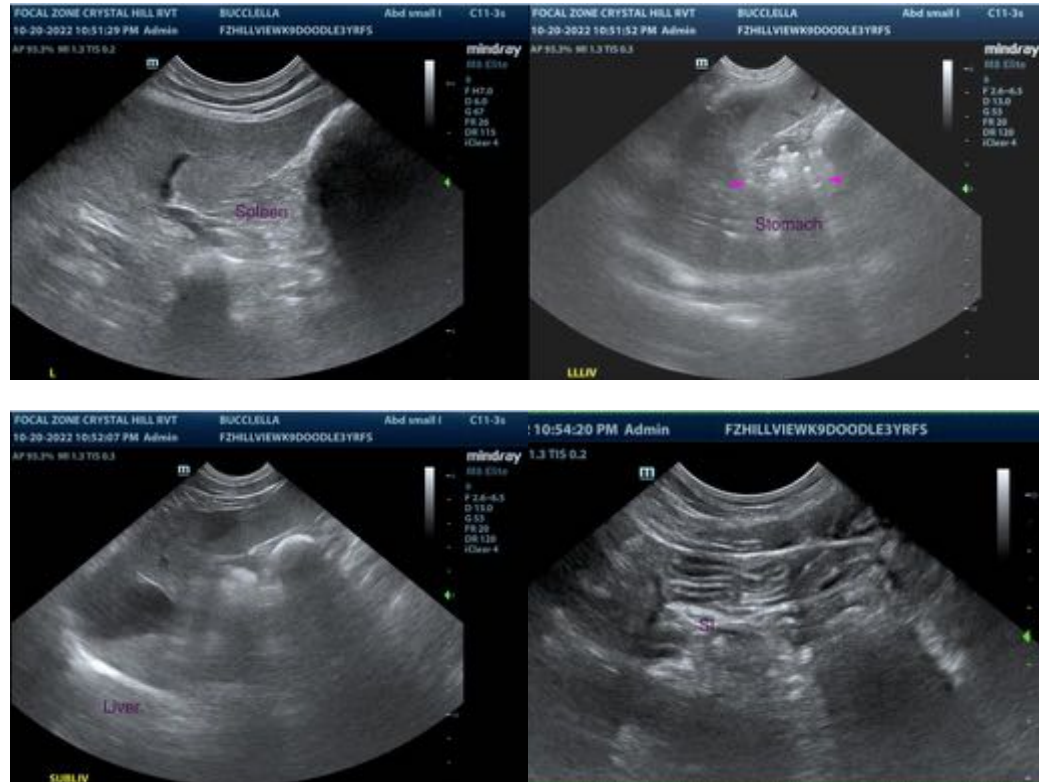
Dr. Stevenson

INVOICE

11862

DATE

10.20.22



The information and recommendations provided are based on the images presented by the referring veterinarian/sonographer. No evaluation can be communicated regarding pathology that was not visible in the image/video clips provided.

Thank you for this referral. If the clinical or image interpretation does not parallel your findings or if I can be of any further assistance, please contact me.

Andrea Nicastro, MPH, DVM, Diplomate DACVIM (Small Animal Internal Medicine)
info@SonoPath.com