

**DATE PRESENTING CLINICAL SIGNS**

10/20/21 History: Lethargy, spinal pain, urinary symptoms.

PATIENT

Oliver Urso

Current Medications: Deramaxx 25mg PO sid, Gabapentin 150mg PO bid, Clavamox 250mg PO bid.

Date of Previous IntraPet Ultrasound: No previous

Sedation: declined

Stat Report: not requested / declined

SPECIES

Canine

BREED

Beagle Mix

SEX

Neutered Male

AGE

2011

WEIGHT

35.5 Pounds

INTERPRETED BY

Andrea Nicastro, DMV,
 Diplomate DACVIM
 (Small Animal
 Internal Medicine)

HOSPITAL NAME

Claws N Paws AH

REFERRING VET

Dr. Singh

INVOICE

13908

ULTRASONOGRAPHIC EXAMINATION OF THE ABDOMEN**Urinary System**

The urinary bladder, trigone, and pelvic urethra are normal in thickness and the mucosal surface is smooth. The bladder lumen is moderately distended with anechoic urine. No masses, inflammatory changes or calculi are observed. Ureteral papillae and visualized portion of the proximal urethra, visible to a depth of 2 cm, are normal.

The prostate is normal in size (0.91 cm in width) and shape. Parenchyma is homogenous. The prostatic urethra appears normal without evidence of dilation or obstruction.

The left kidney presented normal size (6.32 cm in length); normal shape and architecture with smooth peripheral contours. The cortex is slightly heterogeneous in appearance with a few small cortical cysts. There is a normal 1:3 cortex to medulla ratio with mild loss of corticomedullary distinction. Hyperechoic shadowing diverticular foci are visualized. Mild pyelectasia is present, 0.46 cm in the longitudinal plane. There is no evidence of infarcts or hydronephrosis. Renal vasculature is normal.

The right kidney presented normal size (5.68 cm in length); normal shape and architecture with smooth peripheral contours. The cortex is slightly heterogeneous in appearance with a few small cortical cysts. There is a normal 1:3 cortex to medulla ratio with mild loss of corticomedullary distinction. Hyperechoic shadowing diverticular foci are visualized. There is no evidence of pyelectasia, infarcts or hydronephrosis. Renal vasculature is normal.

Adrenal Glands

The left adrenal gland is normal size (0.59 cm at cranial pole) (0.67 cm at caudal pole) (2.28 cm in length); normal shape; homogenous parenchyma. The glandular echogenicity and detail are unremarkable. Capsule, cortex, and medullary definition are normal. The phrenicoabdominal vein and surrounding vasculature are normal.

The right adrenal gland is normal size (0.86 cm at cranial pole) (0.70 cm at caudal pole) (2.65 cm in length); normal shape; homogenous parenchyma. The glandular echogenicity and detail are unremarkable. Capsule, cortex, and medullary definition are normal. The phrenicoabdominal vein and surrounding vasculature are normal.

Spleen

The spleen is subjectively normal in size slightly irregular peripheral contours. The parenchyma is diffusely mottled in appearance. A 2.83 cm swelling is observed at the cranial aspect. In addition, a 1.29 cm x 1.22 cm irregular hypoechoic to heterogeneous nodule is observed cranial to the hilus. A 1.62 cm x 0.87 cm hypoechoic to slightly heterogeneous nodule is also observed caudal to the hilus. Splenic vasculature

appears normal with no evidence of thrombosis.

Liver

The liver is subjectively normal in size with normal curvilinear peripheral contours. The parenchyma is hypoechoic relative to the spleen and diffusely mottled in appearance. No distinct focal lesions are observed.

Hepatic vasculature and intrahepatic biliary tracts are of normal volume with no evidence of congestion.

The gall bladder lumen is moderately distended. The wall is thin and smooth. A small to moderate amount of partially dependent aggregated echogenic debris is observed within the lumen. The cystic and common bile ducts are normal.

Gastrointestinal

The stomach and intestine are free of stasis and exhibit normal peristaltic activity. The gastric lumen is not distended. The gastric wall and pylorus are normal in thickness with a normal layering pattern. The small intestinal lumen is not dilated. The small intestinal wall thickness is normal with a normal layering pattern and appropriate mural detail. Discreet masses are not identified. The ileocecal junction and colonic wall are normal. There is no evidence of an obstructive pattern.

Pancreas

The right limb of the pancreas is visible with normal curvilinear peripheral contours. The parenchyma is largely hyperechoic relative to surrounding omental fat and slightly mottled in appearance. The pancreatic duct is visible but not overtly dilated. There is no evidence of peripancreatic inflammation or effusion.

Free Abdomen

There is no evidence of free fluid. 2-3 prominent to enlarged hypoechoic lymph nodes are observed at the aortic trifurcation, the largest measuring 1.95 cm x 1.41 cm. Several enlarged, irregular hypoechoic mesenteric lymph nodes are also seen. Surrounding mesentery is hyperechoic.

Other

A brief echocardiogram reveals no evidence of pericardial effusion or obvious right atrial/auricular mass.

ULTRASONOGRAPHIC FINDINGS

Primary Findings

- The abdominal lymphadenopathy is concerning for infiltrative neoplasia (i.e., round cell tumor). However, reactive lymphadenitis or lymphoid hyperplasia cannot be completely excluded.
- The splenic nodules could be consistent with neoplastic lesions. Alternatively, benign pathology (i.e., foci of extramedullary hematopoiesis or lymphoid hyperplasia) may be present.
- Non-specific diffuse hepatopathy, differentials include benign pathology (i.e., regenerative nodular hyperplasia, vacuolar hepatopathy, age-related remodeling). Alternatively, inflammatory disease or infiltrative neoplasia may be present.

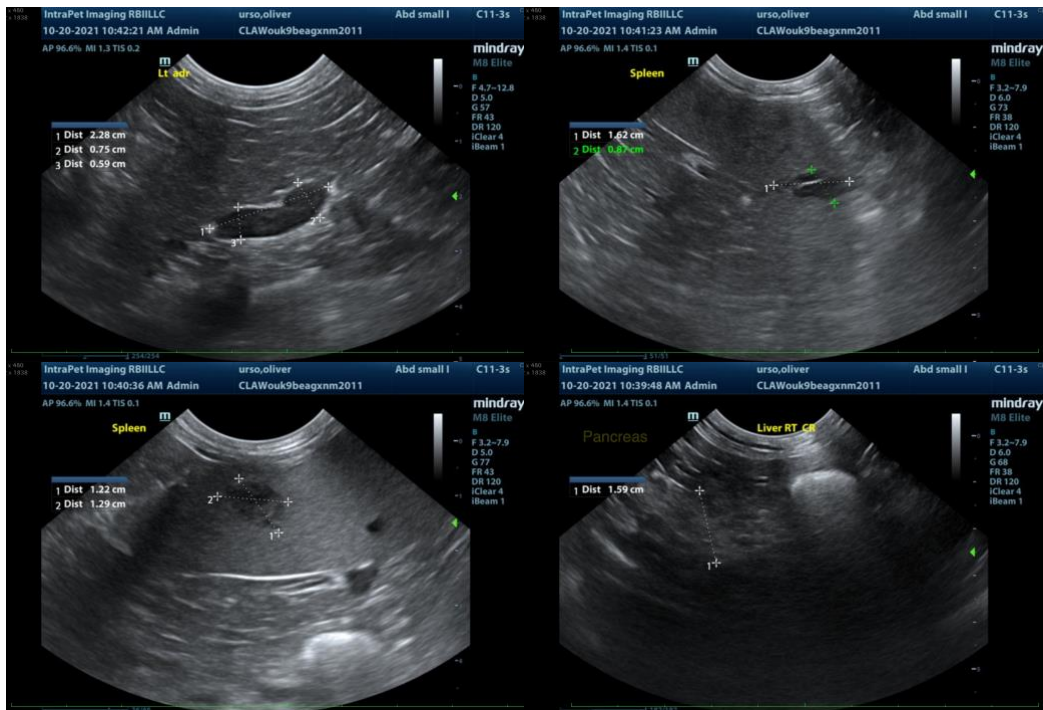
Secondary Findings

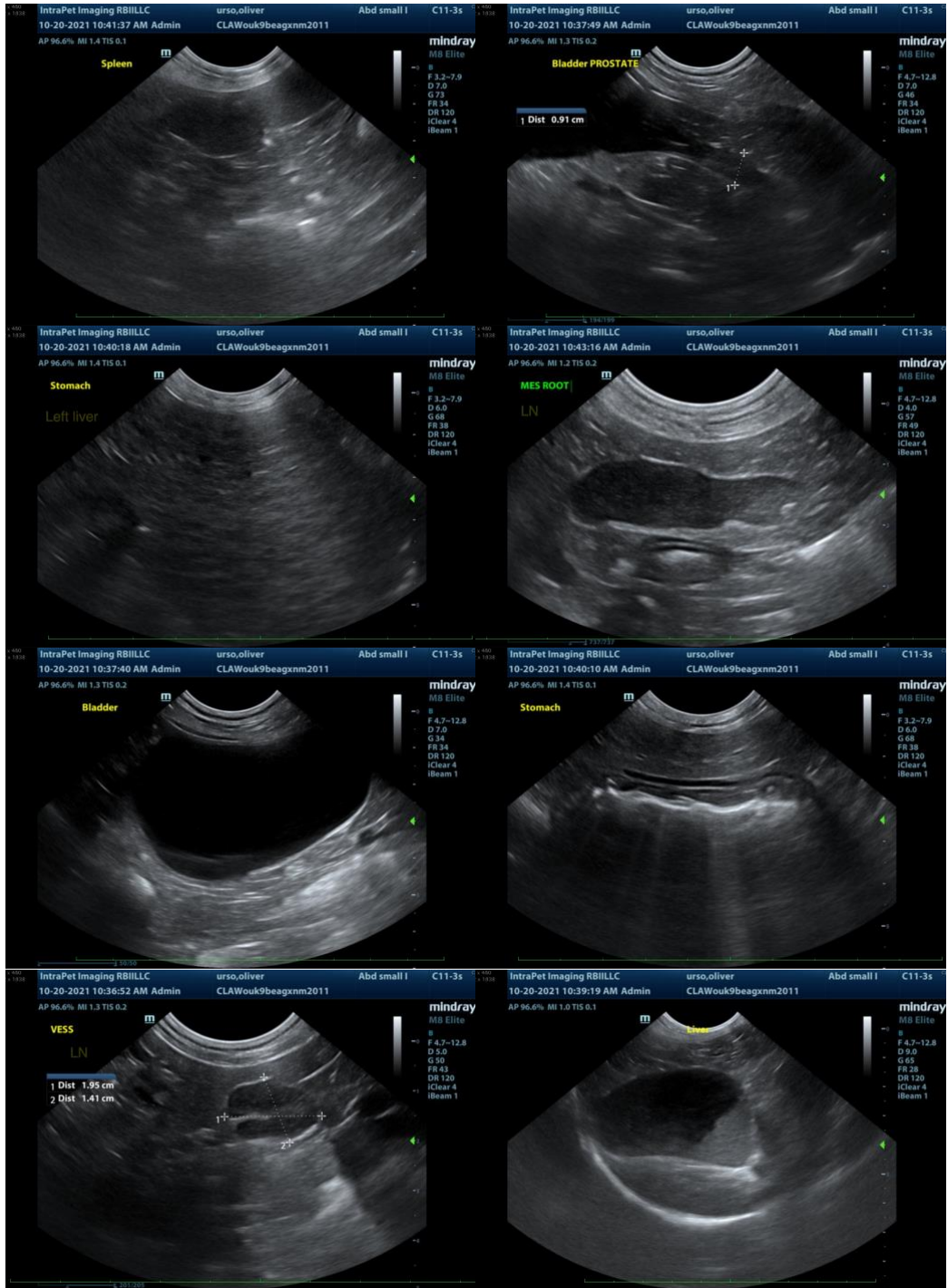
- Gallbladder debris, non-mucocele

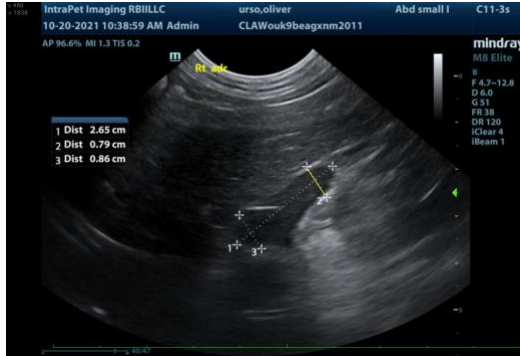
- The pancreatic changes are most consistent with age-related parenchymal remodeling, potentially secondary to a prior inflammatory episode, early fibrosis or chronic pancreatitis.
- Bilateral age-related renal changes with dystrophic mineralization and right pyelectasia

INTERPRETATION OF THE FINDINGS & FURTHER RECOMMENDATIONS

- Fine needle aspirates of the enlarged mesenteric lymph nodes, splenic nodules, +/- liver are recommended if clotting status is normal. A 25-gauge needles should be used. If cytologic evaluations are inconclusive, surgical biopsies may be necessary to get a definitive diagnosis.
- Three view thoracic radiographs are recommended to assess for pulmonary metastatic disease.
- Baseline lab work including a CBC/Chemistry panel, urinalysis and T4 is recommended if not already performed.
- Given the urinary issues, a urine culture and sensitivity should also be considered.







The information and recommendations provided are based on the images presented by the referring veterinarian. No evaluation can be communicated regarding pathology that was not visible in the image/video clips provided.

Thank you for this referral. If the clinical or image interpretation does not parallel your findings or if I can be of any further assistance please contact me.

Andrea Nicastro, DVM, Diplomate DACVIM (Small Animal Internal Medicine)
info@SonoPath.com