



PATIENT PRESENTING CLINICAL SIGNS

Walker Lobello History: Presented with leaking urine while sleeping (3 times past month). Dog is also polyphasic and polydipsic. Bloodwork All WNL except Alk Phos - 546. UA shows SpGravity 1.009, rest all WNL. LDDT is inconclusive (baseline - 3.2; 4hr - 1.9; 8hr - 1.5) Ultrasound done for further diagnostics

SPECIES

Canine

29 still images and 26 video clips are available for interpretation.

ULTRASONOGRAPHIC EXAMINATION OF THE ABDOMEN

BREED

Mixed

Urinary System

The **urinary bladder** wall is normal in thickness and the mucosal surface is smooth. The bladder lumen is moderately distended with anechoic urine. No masses, inflammatory changes or calculi are observed. Ureteral papillae and visualized portion of the proximal urethra, visible to a depth of 2 cm, are normal.

SEX

Neutered Male

The region of the **prostate** is not visualized due to its pelvic location.

AGE

10 years, 11 mos

The **left kidney** is normal size (6.45 cm in length); normal shape and architecture with smooth peripheral margins. There is a normal 1:3 cortex to medulla ratio with minimal to mild loss of corticomedullary distinction. A small cortical cyst is observed at the medial aspect. There is no evidence of pyelectasia, nephroliths, infarcts or hydroureter.

WEIGHT

63 lbs

The **right kidney** is normal size (6.48 cm in length); normal shape and architecture with smooth peripheral margins. There is a normal 1:3 cortex to medulla ratio with minimal to mild loss of corticomedullary distinction. There is no evidence of pyelectasia, nephroliths, infarcts or hydroureter.

Adrenal Glands

The **left adrenal gland** is normal size (0.72 cm at cranial pole) (0.68 cm at caudal pole) (3.28 cm in length); normal shape; homogenous parenchyma. The glandular echogenicity and detail are unremarkable. Capsule, cortex, and medullary definition are normal. The phrenicoabdominal vein and surrounding vasculature are normal.

The **right adrenal gland** is normal size (1.34 cm at cranial pole) (0.61 cm at caudal pole) (2.73 cm in length); normal shape; homogenous parenchyma. The glandular echogenicity and detail are unremarkable. Capsule, cortex, and medullary definition are normal. The phrenicoabdominal vein and surrounding vasculature are normal.

INTERPRETED BY

Andrea Nicastro,
DVM, Diplomate
ACVIM (*Small Animal
Internal Medicine*)

IMAGING PERFORMED BY

Dr. Leal

Spleen

The **spleen** is normal in size (2.20 cm in width at the level of the hilus) with a normal capsular contour. There is appropriate echogenicity and echotexture. No focal lesions are observed. Splenic vasculature is normal.

HOSPITAL NAME

Blairstown AH

Liver

The **liver** is prominent in size with normal peripheral contours. The parenchyma is isoechoic relative to the spleen and diffusely homogeneous in appearance. No distinct focal lesions are observed. Vascular and biliary tracts are of normal volume with no evidence of congestion.

REFERRING VET

Dr. Leal

INVOICE

11845

DATE

10.19.22

The **gall bladder** is of normal contours and contains some dependent echogenic debris. The wall is normal in thickness. No choleliths are observed. The cystic and common bile ducts are normal/not seen.

Gastrointestinal

The **gastric lumen** is mildly distended with ingesta. The gastric wall is normal in thickness with a normal layering pattern. The small intestinal lumen is segmentally dilated with chyme. The small intestinal wall thickness is normal with a normal layering pattern and appropriate mural detail. Discreet masses are not identified. The colonic wall is normal. There is no evidence of an obstructive pattern.

Pancreas

The region of the **pancreas** is isoechoic relative to surrounding omental fat. No obvious parenchymal abnormalities are observed. There is no evidence of regional inflammation or effusion.

Free Abdomen

The **peritoneal cavity** is normal. There is no evidence of inflammation or effusion. The abdominal **lymph nodes** are normal/not visible.

ULTRASONOGRAPHIC FINDINGS

Primary Findings

- Suspected benign hepatopathy. Top differentials include vacuolar hepatopathy and regenerative nodular hyperplasia. Given the liver enzyme pattern, inflammatory disease is considered less likely. Infiltrative neoplasia is possible but also considered less likely, given the sonographic appearance of the liver.

Secondary Findings

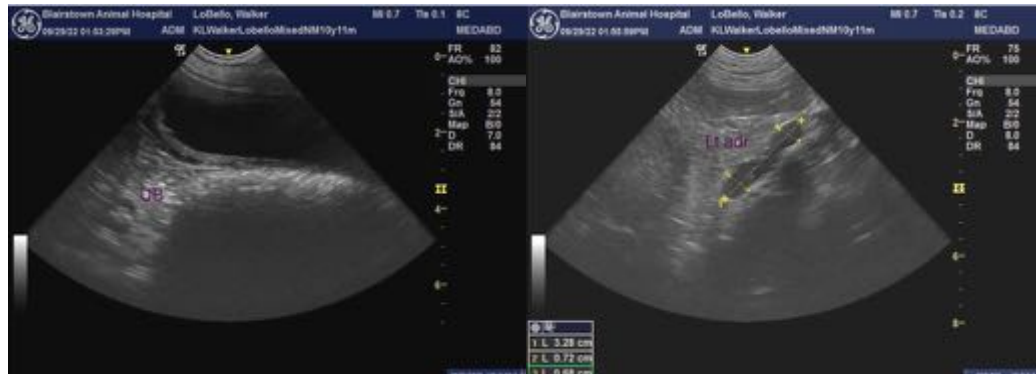- Minor bilateral age-related renal changes

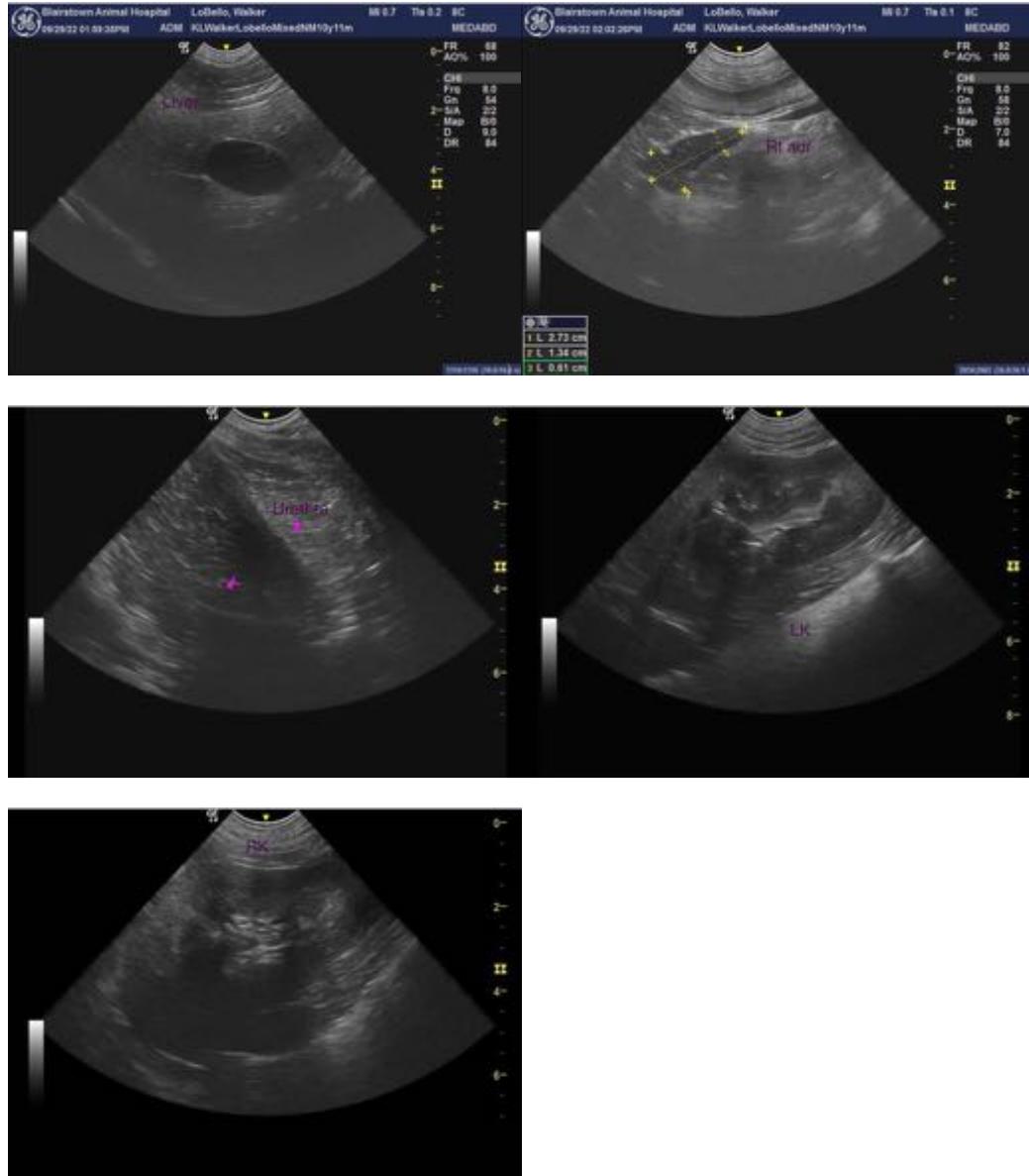
INTERPRETATION OF THE FINDINGS & FURTHER RECOMMENDATIONS

A urine culture and sensitivity is recommended.

Given the inconclusive results from the low-dose dexamethasone suppression test, consider further testing for Cushing's Disease (i.e., ACTH stimulation test +/- a full adrenal panel (University of TN)). If the above diagnostics are inconclusive, consider the following:

1. Pre-and postprandial serum bile acids to assess hepatic function
2. Leptospirosis testing, as this infection can cause PU/PD in some animals
3. DDAVP trial
4. +/- water deprivation test.





The information and recommendations provided are based on the images presented by the referring veterinarian/sonographer. No evaluation can be communicated regarding pathology that was not visible in the image/video clips provided.

Thank you for this referral. If the clinical or image interpretation does not parallel your findings or if I can be of any further assistance, please contact me.

Andrea Nicastro, MPH, DVM, Diplomate DACVIM (Small Animal Internal Medicine)
info@SonoPath.com