



PATIENT

Mia Richardson

PRESENTING CLINICAL SIGNS

History: several months history of vomiting, recently increased in frequency to daily. Thickened intestines on palpation. On gabapentin for exams.
Abnormal PE/Chem/CBC/UA Results: n/a

SPECIES

Feline

ULTRASONOGRAPHIC EXAMINATION OF THE ABDOMEN

BREED

DSH

Urinary System

The **urinary bladder** wall is normal in thickness and the mucosal surface is smooth. The bladder is moderately distended. A small amount of suspended, echogenic debris is observed within the lumen. No masses, inflammatory changes or calculi are observed. Ureteral papillae and visualized portion of the proximal urethra, visible to a depth of 2 cm, are normal.

SEX

Spayed Female

The **left kidney** is normal size (3.57 cm in length); normal shape and architecture with smooth peripheral margins. There is a normal 1:3 cortex to medulla ratio with minimal loss of corticomedullary distinction. There is no evidence of pyelectasia, nephroliths, infarcts or hydronephrosis. Renal vasculature is normal.

AGE

12 years

The **right kidney** is normal size (3.88 cm in length); normal shape and architecture with smooth peripheral margins. There is a normal 1:3 cortex to medulla ratio with normal corticomedullary distinction. There is no evidence of pyelectasia, nephroliths, infarcts or hydronephrosis. Renal vasculature is normal.

WEIGHT

10 lbs

Adrenal Glands

The **left adrenal gland** is normal size (0.38 cm width). Normal shape and glandular echogenicity. The phrenicoabdominal vein and surrounding vasculature are normal.

The **right adrenal gland** is normal size (0.32 cm width). Normal shape and glandular echogenicity. The phrenicoabdominal vein and surrounding vasculature are normal.

INTERPRETED BY

Andrea Nicastro,
DVM, Diplomate
ACVIM (*Small Animal
Internal Medicine*)

Spleen

The **spleen** is normal in size (0.75 cm in width at the level of the hilus) with a normal capsular contour. There is appropriate echogenicity and echotexture. No focal lesions are observed. Splenic vasculature is normal.

IMAGING PERFORMED BY

Diane McFadden

Liver

The **liver** is subjectively normal in size with normal contours and structure. There is appropriate echogenicity and echotexture. No overt structural evidence of inflammatory, infiltrative, or regenerative pathology is evident. Vascular and biliary tracts are of normal volume with no evidence of congestion. No pathological hepatic lymphadenopathy observed. The portal vein to caudal vena cava ratio is approximately 1: 1.

HOSPITAL NAME

Milburn VH

The **gall bladder** lumen is moderately distended. The wall is thin and smooth. Luminal contents are anechoic. The cystic and common bile ducts are normal.

REFERRING VET

Dr Turowsky

Gastrointestinal

The **stomach and intestine** are free of stasis and exhibit normal peristaltic activity. The gastric lumen is not distended. The gastric wall and pylorus are normal in thickness with a normal layering pattern. The pyloric outflow tract is patent. The small intestinal lumen is not dilated. The small intestinal wall thickness is normal with a normal layering pattern and appropriate mural detail. Discreet masses are not identified. The ileoceocolic junction and colonic wall are normal. There is no evidence of an obstructive pattern.

INVOICE

11852

Pancreas

The **pancreas** is normal in size with normal peripheral contours. The pancreatic duct is normal. The base and limbs of the pancreas are isoechoic to surrounding omental fat. No focal lesions are observed. There is

DATE

10.19.22

no evidence of peripancreatic inflammation or effusion.

Free Abdomen

There is no evidence of free fluid. A few prominent, slightly irregular mesenteric **lymph nodes** are visualized, the largest measuring 2.04 cm in length. Surrounding mesentery is hyperechoic.

ULTRASONOGRAPHIC FINDINGS

Primary Findings

- The abdominal lymphadenopathy could be consistent with lymphoid hyperplasia, reactive lymphadenitis or emerging neoplasia (i.e., lymphoma)

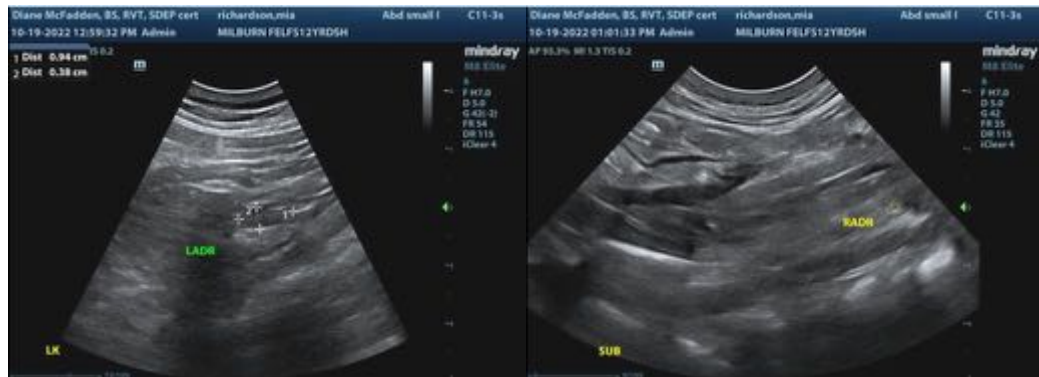*An obvious cause for the patient's clinical signs is not identified in this study. Considerations include microscopic gastrointestinal disease (food allergy/intolerance, inflammatory bowel disease, infectious/parasitic disease, emerging lymphoma), underlying metabolic issue, mild pancreatitis, other.

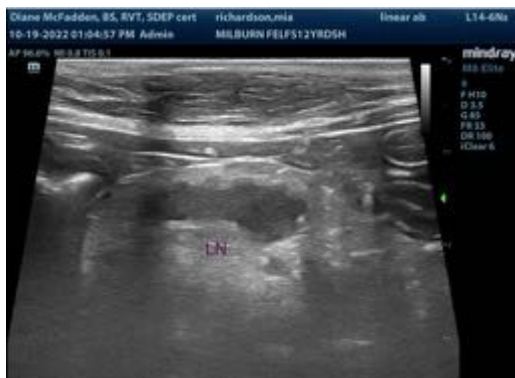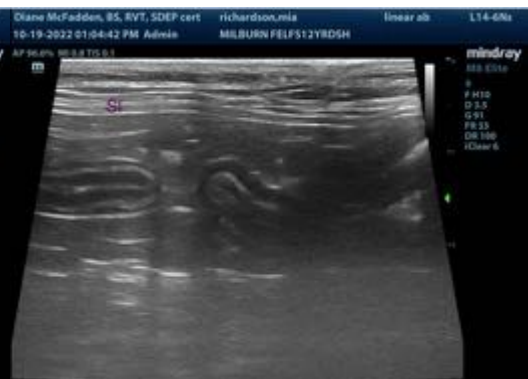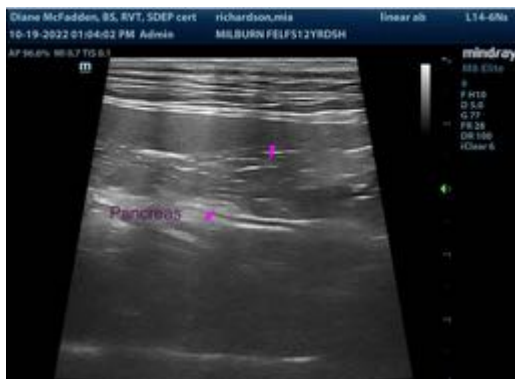
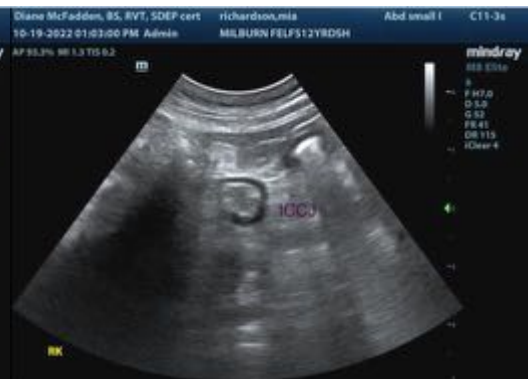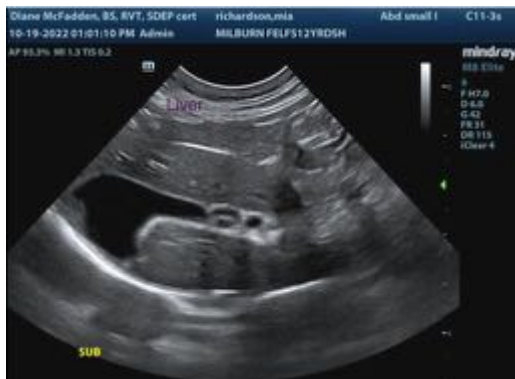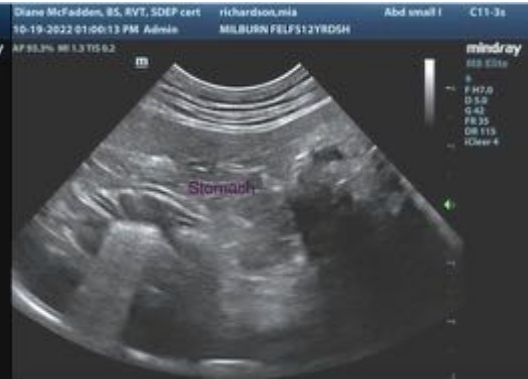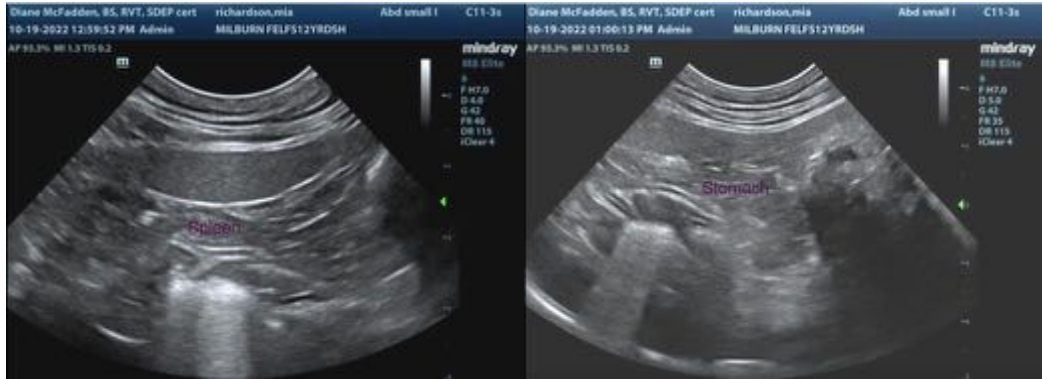INTERPRETATION OF THE FINDINGS & FURTHER RECOMMENDATIONS

Baseline lab work, including a CBC, chemistry panel, urinalysis and T4 is recommended, if not already performed.

Other diagnostic/therapeutic considerations include the following:

1. A fecal evaluation for ova and Giardia is recommended
2. Maldigestion panel including serum cobalamin and folate, TLI and PLI
3. Heartworm testing (i.e., antigen and antibody)
4. Three-view thoracic radiographs to assess occult esophageal disease
5. Hydrolyzed protein or limited antigen diet trial
6. Ultimately, GI biopsies (i.e., endoscopic, or surgical) may be necessary to get a definitive diagnosis.
7. If biopsies are not to be pursued, consider empirical treatment for helicobacter:
 - a. Amoxicillin: 10-22 mg/kg PO q 12 hours x 14-21 days
 - b. Metronidazole: 10-15 mg/kg PO q 12 hours for 14-21 days
 - c. Omeprazole: 0.7 mg/kg PO q 24 hours for 14-21 days
 - d. (+/- the addition of Bismuth subsalicylate: 3.85 mg/kg PO q 6-8 hours x 14-21 days)





The information and recommendations provided are based on the images presented by the referring veterinarian/sonographer. No evaluation can be communicated regarding pathology that was not visible in the image/video clips provided.

Thank you for this referral. If the clinical or image interpretation does not parallel your findings or if I can be of any further assistance, please contact me.

Andrea Nicastro, MPH, DVM, Diplomate DACVIM (Small Animal Internal Medicine)
info@SonoPath.com