

**DATE PRESENTING CLINICAL SIGNS**

10/19/2021

History: marked elevation ALP (increasing). Per owner- no recent changes in drinking/urination over the past few years; pet does not appear Cushingoid.

**PATIENT**

Cherry Powers

Current Medications: Denamarin Advanced.  
 Lab Results: 10/7/2021 ap 1560, bile acids sent to Antech normal.  
 Radiographs: Not provided by the veterinarian.  
 Date of Previous IntraPet Ultrasound: No previous IntraPet scans.  
 Sedation: Sedation not required for scan.  
 Stat Report: STAT report not requested by the veterinarian.

**SPECIES**

Canine

**BREED**

Cocker spaniel

**SEX**

Female, spayed

**AGE**

2/27/2009

**WEIGHT**

36.6 lbs.

**ULTRASONOGRAPHIC EXAMINATION OF THE ABDOMEN****Urinary System**

The urinary bladder, trigone, and pelvic urethra are normal in thickness and the mucosal surface is smooth. The bladder lumen is moderately distended with mostly anechoic urine. No masses, inflammatory changes or calculi are observed. Ureteral papillae and visualized portion of the proximal urethra, visible to a depth of 2 cm, are normal.

The left kidney is normal size (6.08 cm in length); normal shape and architecture with smooth peripheral margins. There is a normal 1:3 cortex to medulla ratio with minimal to mild loss of corticomedullary distinction. There is no evidence of pyelectasia, nephroliths, infarcts or hydroureter.

The right kidney is normal size (6.57 cm in length); normal shape and architecture with smooth peripheral margins. There is a normal 1:3 cortex to medulla ratio with minimal loss of corticomedullary distinction. 1-2 pinpoint hyperechoic foci are observed within the cortex. There is no evidence of pyelectasia, nephroliths, infarcts or hydroureter.

**INTERPRETED BY**

Andrea Nicastro, DVM,  
 Diplomate ACVIM  
 (Small Animal Internal  
 Medicine)

**Adrenal Glands**

The left adrenal gland is mildly enlarged (0.52 cm at cranial pole) (0.79 cm at caudal pole) (2.35 cm in length) with a prominent caudal pole. The glandular echogenicity and detail are unremarkable. Capsule, cortex, and medullary definition are normal. The phrenicoabdominal vein and surrounding vasculature are normal.

The right adrenal gland is normal size (0.50 cm at cranial pole) (0.55 cm at caudal pole) (2.15 cm in length); normal shape; homogenous parenchyma. The glandular echogenicity and detail are unremarkable. Capsule, cortex, and medullary definition are normal. The phrenicoabdominal vein and surrounding vasculature are normal.

**HOSPITAL NAME**

Banfield Pet Hospital  
 of Towson

**Spleen**

The spleen is normal to slightly prominent in size (1.36 cm in width at the level of the hilus) with normal curvilinear peripheral contours. The parenchyma is subtly mottled in appearance. No focal lesions are observed. Splenic vasculature is normal.

**REFERRING VET**

Dr. Mike

**Liver****INVOICE**

12398

The liver is subjectively prominent in size with slightly rounded peripheral contours. The parenchyma is hyperechoic relative to the spleen and subtly heterogeneous in appearance. No distinct focal lesions are observed. Vascular and biliary tracts are of normal volume with no evidence of congestion. The gall bladder lumen is moderately distended. The wall is thin and smooth. A small to moderate amount of aggregated echogenic partially dependent debris is observed within the lumen. The cystic and common bile ducts are normal/not seen.

### ***Gastrointestinal***

The stomach and intestine are free of stasis and exhibit normal peristaltic activity. The gastric lumen is not distended. The gastric wall and pylorus are normal in thickness with a normal layering pattern. The pyloric outflow tract is patent. The small intestinal lumen is not dilated. The small intestinal wall thickness is normal with a normal layering pattern and appropriate mural detail. Discreet masses are not identified. The colonic wall is normal. No obstructive disease is noted.

### ***Pancreas***

The right limb of the pancreas is prominent in size with slightly irregular peripheral contours. The parenchyma is hypoechoic relative to surrounding omental fat and slightly mottled in appearance. No distinct focal lesions are observed. The pancreatic duct is not overtly dilated.

### ***Free Abdomen***

The peritoneal cavity is normal. There is no evidence of inflammation or effusion. The abdominal lymph nodes are normal/not visible.

## **ULTRASONOGRAPHIC FINDINGS**

### **Primary Findings:**

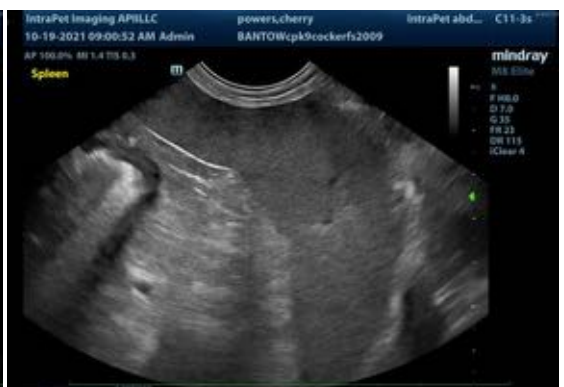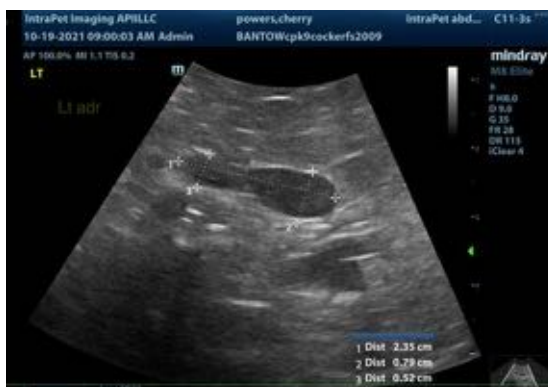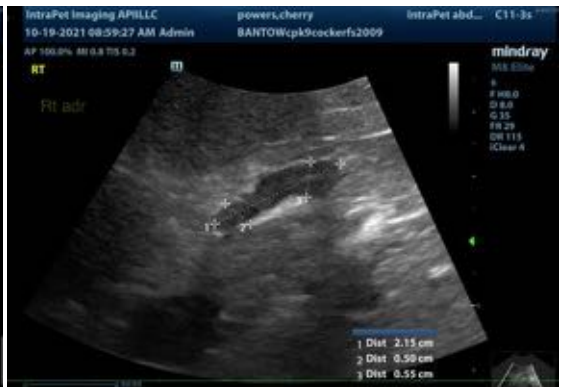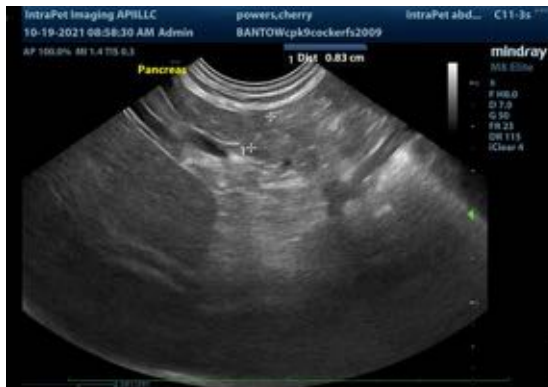
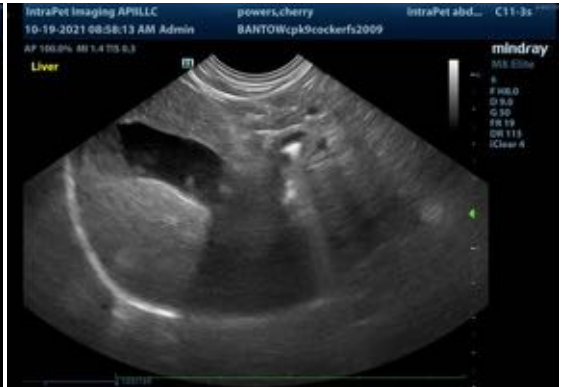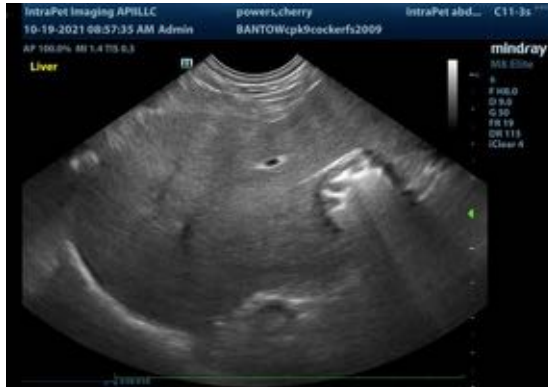- The diffuse hepatic changes are non-specific and could be consistent with vacuolar hepatopathy, regenerative nodular hyperplasia, and/or age-related remodeling. Inflammatory and infiltrative disease are considered less likely.
- Gallbladder debris, incidental.
- The mild left adrenomegaly is most consistent with hyperplastic change.

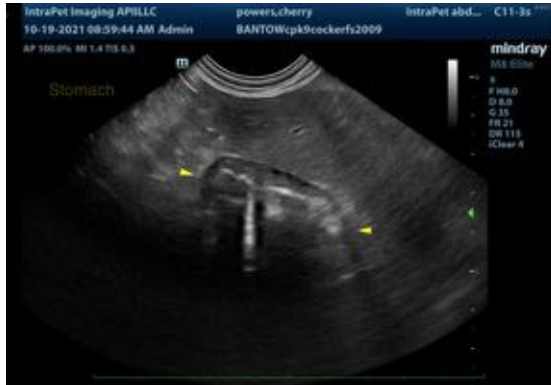### **Secondary Findings:**

- The pancreatic changes are suggestive of chronic low-grade pancreatitis with age-related remodeling. However, correlation with clinical findings is recommended.
- Bilateral age-related renal changes.
- The splenic parenchyma changes are most consistent with a benign process such as lymphoid hyperplasia, extramedullary hematopoiesis or splenitis with a low possibility of infiltrative neoplasia (i.e., lymphoma, mast cell neoplasia).

## **INTERPRETATION OF THE FINDINGS & FURTHER RECOMMENDATIONS**

- Continued monitoring of the patient's liver values (i.e., every 3-4 months) is recommended. If values continue to increase, a repeat abdominal ultrasound +/- hepatic tissue sampling may be warranted.
- Consider testing for hyperadrenocorticism with a low-dose dexamethasone suppression test or ACTH stimulation test if clinical signs (i.e., PU/PD) develop in the future.





The information and recommendations provided are based on the images presented by the referring veterinarian. No evaluation can be communicated regarding pathology that was not visible in the image/video clips provided.

Thank you for this referral. If the clinical or image interpretation does not parallel your findings or if I can be of any further assistance please contact me.

Andrea Nicastro, DVM, Diplomate ACVIM (*Small Animal Internal Medicine*)  
Andrea.nicastro@sonopath.com