

**DATE PRESENTING CLINICAL SIGNS**

10/18/2021

History: Losing weight, uncontrolled hyperthyroidism, renal dz, cancer.
 Current Medications: Methimazole 5mg... Dr. Alexander said to increase to 10mg BID.
 Lab Results: High ATL 172, Calcium 13.5, T4 5.9. CBC normal, T4 5.9.
 Radiographs: Not provided by the veterinarian.
 Date of Previous IntraPet Ultrasound: No previous IntraPet scans.
 Sedation: Not needed.
 Stat Report: Not requested.

SPECIES ULTRASONOGRAPHIC EXAMINATION OF THE ABDOMEN

Feline

Urinary System

The urinary bladder is moderately distended. The wall is normal in thickness with a smooth mucosal surface. A small amount of gravity-dependent mineralized sand is observed along with a scant amount of suspended echogenic debris. The region of the trigone and the visible portion of the proximal urethra are normal.

BREED

Domestic shorthair

SEX

Male, neutered

The left kidney is normal in size (3.52 cm in length) with a normal shape, smooth peripheral margins and normal internal architecture. There is moderate loss of corticomedullary distinction. Several hyperechoic shadowing diverticular foci are observed. There is no evidence of pyelectasia, infarcts or hydronephrosis. Renal vasculature is normal.

AGE

3/4/2008

The right kidney is normal size (3.18 cm in length); normal shape and architecture with smooth peripheral margins. There is a normal 1:3 cortex to medulla ratio with moderate loss of corticomedullary distinction. Hyperechoic shadowing diverticular foci are visualized. Trace pyelectasia is present. There is no evidence of infarcts or hydroureter. Renal vasculature is normal.

WEIGHT

7.3 lbs.

Adrenal Glands

The left adrenal gland is normal in size (0.50 cm width). Normal shape and glandular echogenicity. The phrenicoabdominal vein and surrounding vasculature are normal.

INTERPRETED BY

Andrea Nicastro, DVM,
 Diplomate ACVIM
 (Small Animal Internal
 Medicine)

The right adrenal gland is normal in size (0.45 cm width). Normal shape and glandular echogenicity. The phrenicoabdominal vein and surrounding vasculature are normal.

Spleen

The spleen is normal in size (0.60 cm in width at the level of the hilus) with a normal capsular contour. There is appropriate echogenicity and echotexture. No focal lesions are observed. Splenic vasculature is normal.

HOSPITAL NAME

Animal Hospital at
 Southgate

Liver

The liver is subjectively normal in size with normal curvilinear peripheral contours. The parenchyma is hypoechoic relative to surrounding omental fat. 1-2 hypoechoic nodules are observed on the left side, the largest measuring 0.99 x 0.61 cm. There is an increase in portal markings. Hepatic vasculature is of normal volume with no evidence of congestion. The gall bladder lumen is moderately distended. The wall is thin and smooth. Luminal contents are anechoic. The cystic and common bile ducts are normal.

REFERRING VET

Dr. Alexander

Gastrointestinal

The stomach and intestine are free of stasis and exhibit normal peristaltic activity. The gastric lumen is not distended. The gastric wall and pylorus are normal in thickness with a normal layering pattern. The pyloric outflow tract is patent. The small intestinal lumen is not dilated. The small intestinal wall thickness is normal with a normal layering pattern and appropriate mural detail. Discreet masses are not identified. The ileocecal colic junction and colonic wall are normal. No obstructive disease is noted.

INVOICE

12368

Pancreas

The left limb of the pancreas is prominent to enlarged with minimal deviation from the normal peripheral contours. The parenchyma is hypoechoic relative to surrounding omental fat. No focal lesions are observed.

The pancreatic duct is borderline dilated (0.23 cm in diameter). The mesentery effacing the serosal surface is hyperechoic.

Free Abdomen

There is no evidence of free fluid. 1-2 prominent mesenteric lymph nodes are visualized.

ULTRASONOGRAPHIC FINDINGS

Primary Findings:

- The pancreatic changes are most consistent with mild to moderate acute or chronic, active pancreatitis.
- The increase in hepatic portal markings is suggestive of inflammatory disease. The hypoechoic hepatic nodule(s) trend toward the benign (i.e., areas of hyperplasia or inflammation) with a low possibility of an emerging neoplasia.

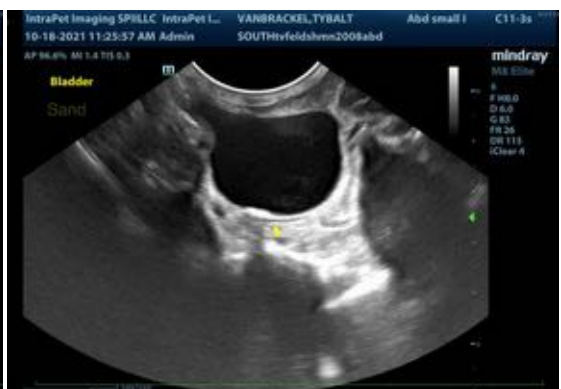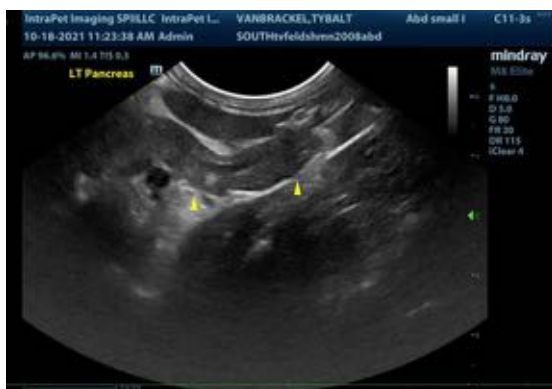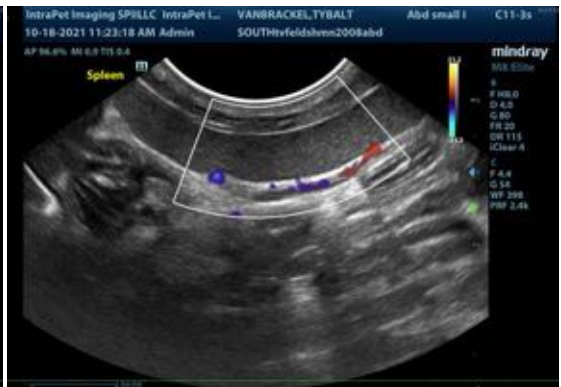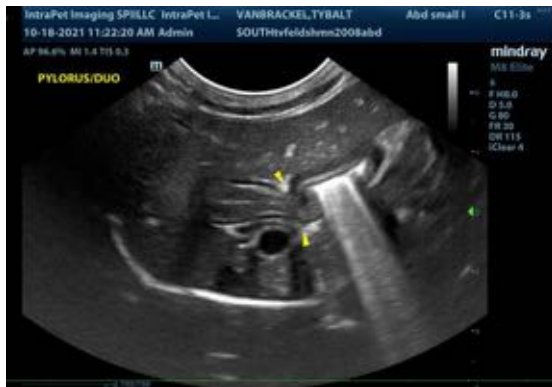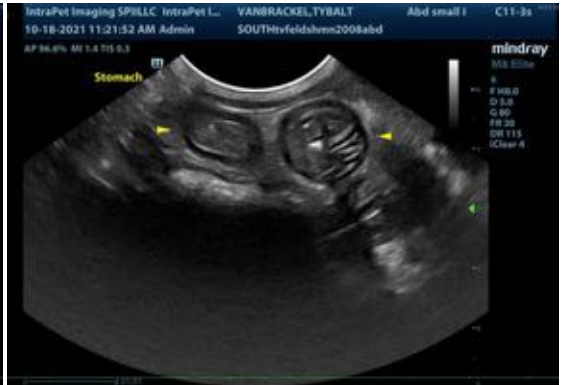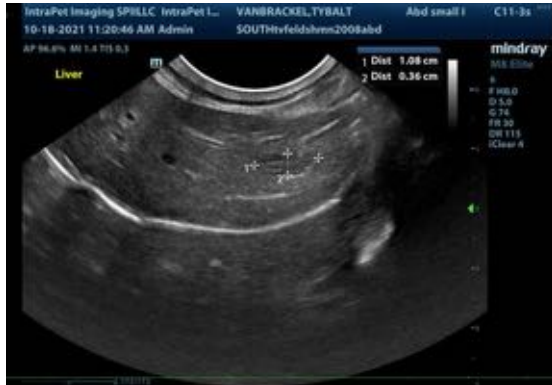Secondary Findings:

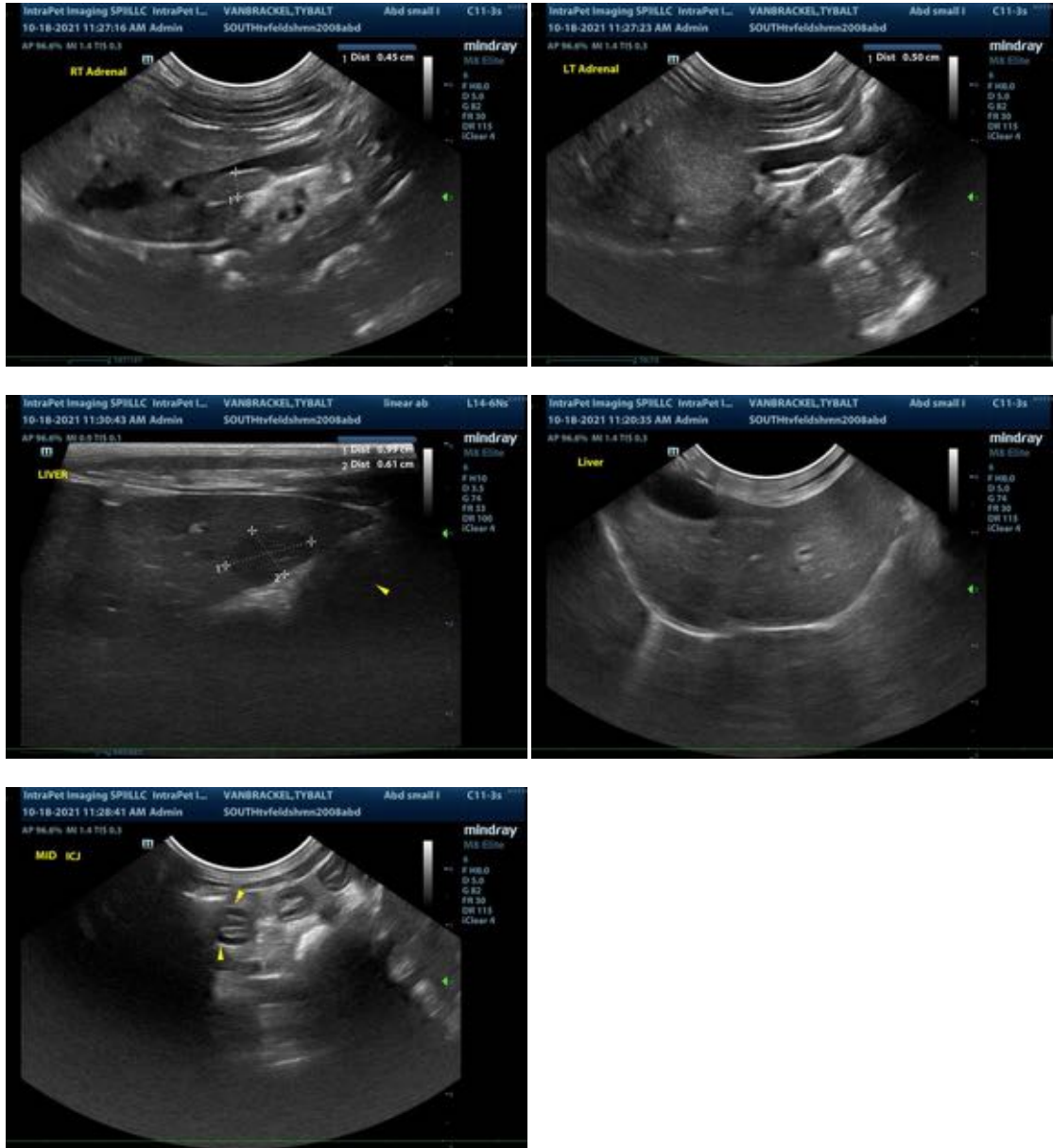
- Bilateral, age-related renal pathology with dystrophic mineralization.
- Urinary bladder sand.
- The prominent mesenteric lymph nodes are likely reactive.

*An obvious cause for the patient's hypercalcemia is not identified in this study. Differentials include occult neoplasia, idiopathic, primary hyperparathyroidism, other.

INTERPRETATION OF THE FINDINGS & FURTHER RECOMMENDATIONS

- Three-view thoracic radiographs are recommended to assess for occult neoplasia in the chest.
- A PTH/PTHrP and ionized calcium levels (Michigan State University Veterinary Diagnostic Laboratory) is recommended; <https://cvm.msu.edu/vdl/laboratory-sections/endocrinology>.
- Regarding the weight loss, consider a more advanced GI workup (i.e., GI panel, fecal evaluation for ova and giardia, +/- endoscopic or surgical gastrointestinal biopsies) if regulation of the hyperthyroidism does not result in weight stabilization.





The information and recommendations provided are based on the images presented by the referring veterinarian. No evaluation can be communicated regarding pathology that was not visible in the image/video clips provided.

Thank you for this referral. If the clinical or image interpretation does not parallel your findings or if I can be of any further assistance please contact me.

Andrea Nicastro, DVM, Diplomate ACVIM (*Small Animal Internal Medicine*)
 Andrea.nicastro@sonopath.com