

**DATE PRESENTING CLINICAL SIGNS**

10/17/22

Patient presents for distended abdomen, not eating. Large amount of abdominal fluid noted on AFast, slightly blood tinged. noted splenic mass, no thoracic fluid noted. P is fed grain free. No Heart Murmur

PATIENT

Houdini Baldwin

Current Medications: cerenia 60mg, lasix 40mg BID

Lab Results: See attached.

Radiographs: thx rads nsf for metastasis. suspect splenic neoplasia +/- mottled/moth eaten liver

Date of Previous IntraPet Ultrasound: No previous.

Sedation: Not required to complete full diagnostic ultrasound.

Stat Report: Not requested.

Imaging Performed By: Andi Parkinson, BS, RDMS.

SPECIES

Canine

BREED

Cane Corso

SEX

Female, spayed

AGE

10/12/2012

WEIGHT

94.8 lbs.

INTERPRETED BY

Andrea Nicastro, DVM,
 Diplomate ACVIM
 (Small Animal Internal
 Medicine)

HOSPITAL NAME

Everhart VH

REFERRING VET

Dr. Hays

INVOICE

14095

ULTRASONOGRAPHIC EXAMINATION OF THE ABDOMEN**Urinary System**

The urinary bladder and visible portion of the pelvic urethra are normal for the degree of luminal distension.

The urine is anechoic with no evidence of debris. Cystic calculi and discrete masses are not observed. The region of the trigone is normal.

The left kidney is normal size (8.27 cm in length); normal shape and architecture with smooth peripheral margins. There is a normal 1:3 cortex to medulla ratio with minimal loss of corticomedullary distinction. There is no evidence of pyelectasia, nephroliths, infarcts or hydroureter.

The right kidney is normal size (8.35 cm in length); normal shape and architecture with smooth peripheral margins. There is a normal 1:3 cortex to medulla ratio with minimal loss of corticomedullary distinction. There is no evidence of pyelectasia, nephroliths, infarcts or hydroureter.

Adrenal Glands

The left adrenal gland is normal size (0.67 cm at cranial pole) (0.71 cm at caudal pole) (3.37 cm in length); normal shape; homogenous parenchyma. The glandular echogenicity and detail are unremarkable. Capsule, cortex, and medullary definition are normal. The phrenicoabdominal vein and surrounding vasculature are normal.

The region of the right adrenal gland is evaluated. No obvious pathology is observed.

Spleen

The spleen is enlarged with irregular peripheral contours. A >13 cm heterogeneous cavitated mass is arising from the parenchyma at the caudal aspect. In addition, a 3.4 cm heterogeneous mass is seen at the medial aspect. The mass causes capsular expansion. The remaining parenchyma is homogeneous. Splenic vasculature appears normal with no evidence of thrombosis.

Liver

The liver is subjectively normal in size with slightly irregular peripheral contours. The parenchyma is isoechoic relative to the spleen. Numerous varying sized hypoechoic to heterogeneous nodules are observed throughout the organ, the largest measuring 2.06 cm in diameter. Vascular and biliary tracts are of normal volume with no evidence of congestion. The gallbladder is of normal contours and contains some dependent echogenic debris. The wall is normal in thickness. No choleliths are observed. The cystic and common bile ducts are normal.

Gastrointestinal

The gastric lumen is not distended. The gastric wall is normal in thickness with a normal layering pattern. The small intestinal lumen is not dilated. The small intestinal wall thickness is normal with a normal layering

pattern and appropriate mural detail. Discreet masses are not identified. The colonic wall is normal. No obstructive disease is noted.

Pancreas

A portion of the pancreas is obscured by the large splenic mass. In the visualized portions, no obvious abnormalities are seen.

Free Abdomen

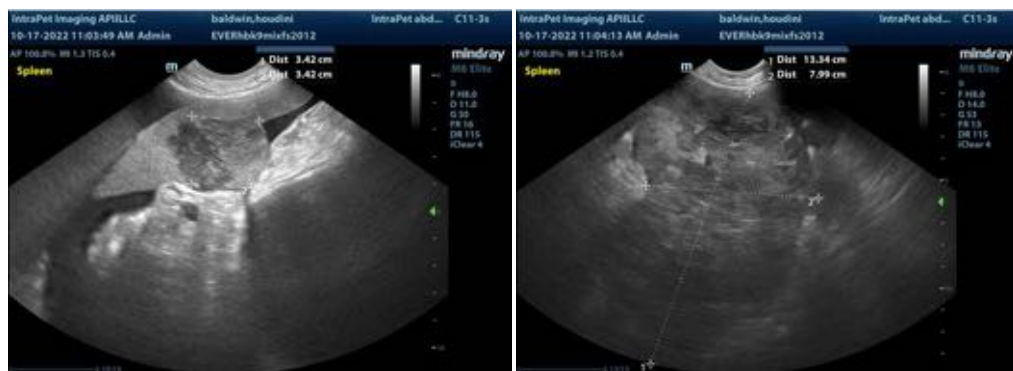
A large amount of echogenic free fluid is present. The abdominal lymph nodes are normal/not visible.

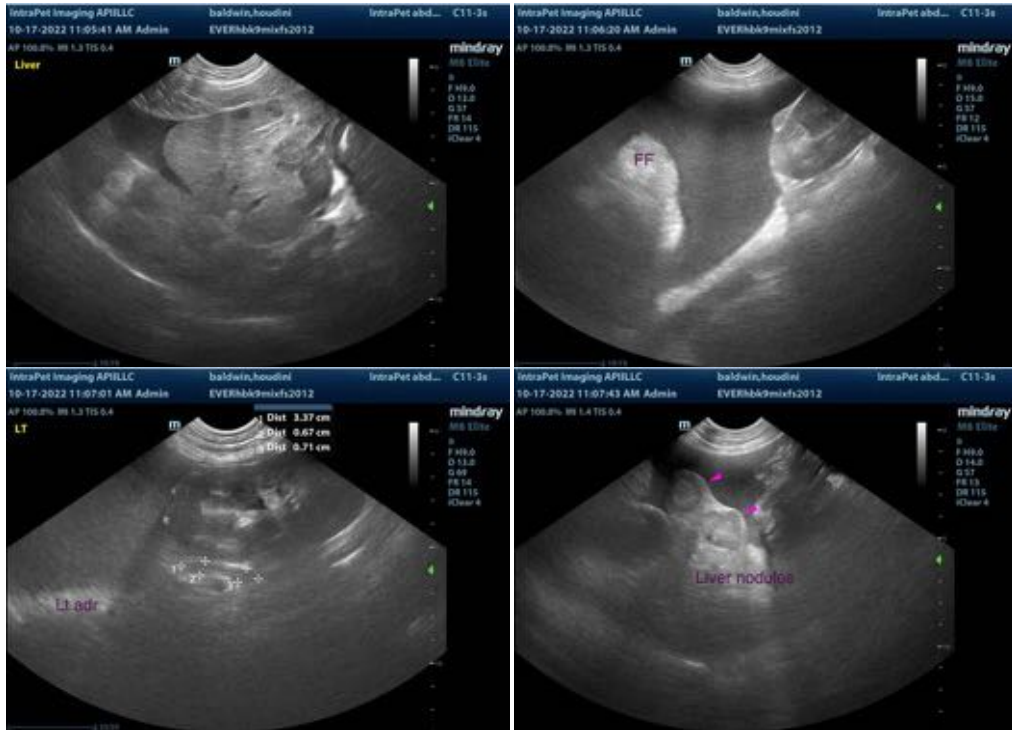
ULTRASONOGRAPHIC FINDINGS

- Splenic masses. Neoplasia (i.e., hemangiosarcoma, round cell tumor) is suspected.
- The numerous hepatic nodules are most concerning for metastatic disease with a lower possibility of a benign process (i.e., regenerative nodules).
- The ascites is likely secondary to hemorrhage and/or neoplastic effusion.

INTERPRETATION OF THE FINDINGS & FURTHER RECOMMENDATIONS

- Three-view thoracic radiographs are recommended to assess for pulmonary metastases.
- Given the high likelihood of metastatic disease in the abdomen, consider palliative/symptomatic care over invasive procedures.





The information and recommendations provided are based on the images presented by the referring veterinarian. No evaluation can be communicated regarding pathology that was not visible in the image/video clips provided.

Thank you for this referral. If the clinical or image interpretation does not parallel your findings or if I can be of any further assistance please contact me.

Andrea Nicastro, MPH, DVM, Diplomate DACVIM (Small Animal Internal Medicine)
info@SonoPath.com