

**DATE PRESENTING CLINICAL SIGNS**

10/15/21 History: Anorexia, weight loss, with intermittent vomiting.

**PATIENT**

Mylo Falter

Lab Results: treated in 2019 for hyperthyroidism/ Radiocat

Radiographs: possible mass cranial abdomen

Date of Previous IntraPet Ultrasound: 10/30/2020

Sedation: not needed

**SPECIES**

Stat Report: not requested

Feline

**ULTRASONOGRAPHIC EXAMINATION OF THE ABDOMEN****BREED**

DSH

**Urinary System**

The urinary bladder, trigone, and pelvic urethra are normal in thickness and the mucosal surface is smooth. The bladder lumen is moderately distended with anechoic urine. No masses, inflammatory changes or calculi are observed. Ureteral papillae and visualized portion of the proximal urethra, visible to a depth of 2.0 cm, are normal.

**SEX**

Neutered Male

**AGE**

2008

The left kidney is normal size (3.63 cm in length); normal shape and architecture with smooth peripheral margins. There is a normal 1:3 cortex to medulla ratio with minimal to mild loss of corticomedullary distinction. There is no evidence of pyelectasia, nephroliths, infarcts or hydroureter. Renal vasculature is normal.

**WEIGHT**

11.4 Pounds

The right kidney is normal size (3.85 cm in length); normal shape and architecture with smooth peripheral margins. There is a normal 1:3 cortex to medulla ratio with minimal to mild loss of corticomedullary distinction. There is no evidence of pyelectasia, nephroliths, infarcts or hydroureter. Renal vasculature is normal.

**INTERPRETED BY**

Andrea Nicastro, DMV,  
Diplomate DACVIM  
(Small Animal  
Internal Medicine)

**Adrenal Glands**

The left adrenal gland is normal size (0.53 cm width). Normal shape and glandular echogenicity. The phrenicoabdominal vein and surrounding vasculature are normal.

**HOSPITAL NAME**

Honeygo AH

The right adrenal gland is normal size (0.55 cm width). Normal shape and glandular echogenicity. The phrenicoabdominal vein and surrounding vasculature are normal.

**REFERRING VET**

Dr. Wright

**Spleen**

The spleen is subjectively enlarged (1.27 cm in width at the level of the hilus) with scalloping of the medial contour. The parenchyma is slightly mottled in appearance. No distinct focal lesions are observed. Splenic vasculature is of normal volume with no evidence of thrombosis.

**INVOICE**

13773

**Liver**

The liver is subjectively enlarged with irregular peripheral contours. Several ill-defined isoechoic coalescing masses throughout the organ, the largest measuring 3.34 cm in length. A 1.90 cm x 1.46 cm irregular hypoechoic nodule is also observed at the tip of the left lateral lobe. The lesion cause capsular expansion. The remaining parenchyma is mottled in appearance. Hepatic vasculature and intrahepatic biliary tracts are of normal volume with no evidence of congestion.

The gall bladder lumen is mildly distended. The wall is thin and smooth. Luminal contents are anechoic. The cystic and common bile ducts are normal.

### ***Gastrointestinal***

The stomach and intestine are free of stasis and exhibit normal peristaltic activity. The gastric lumen is not distended. The gastric wall and pylorus are normal in thickness with a normal layering pattern. The pyloric outflow tract is patent. The small intestinal lumen is not dilated. The small intestinal wall thickness is normal to mildly thickened (up to 0.27 cm) with a normal layering pattern and appropriate mural detail. There is disruption in the normal 1:3 muscularis: mucosal ratio in some segments. Discreet masses are not identified. The ileocecal colic junction and colonic wall are normal. No obstructive disease is noted.

### ***Pancreas***

The pancreas is visible with normal deviation from the normal peripheral contours. The parenchyma is hypoechoic relative to surrounding omental fat. No distinct focal lesions are observed. The pancreatic duct is borderline dilated (0.26 cm in diameter).

### ***Free Abdomen***

Trace free fluid is observed. The mesentery in the cranial abdomen is hyperechoic. Several prominent lymph nodes are observed at the mesenteric root, the largest measuring 1.45 cm in length. A few prominent cranial abdominal lymph nodes are also seen.

## **ULTRASONOGRAPHIC FINDINGS**

### **Primary Findings**

- Multiple hepatic masses, neoplasia (i.e., round cell tumor) is considered likely with a lower possibility of a severe inflammatory process.
- The splenic changes could be consistent with infiltrative neoplasia, lymphoid hyperplasia or extramedullary hematopoiesis.
- The abdominal lymphadenopathy could be consistent with reactive lymphadenitis, lymphoid hyperplasia or infiltrative neoplasia.
- Cranial peritonitis is present, likely secondary to hepatic pathology

### **Secondary Findings**

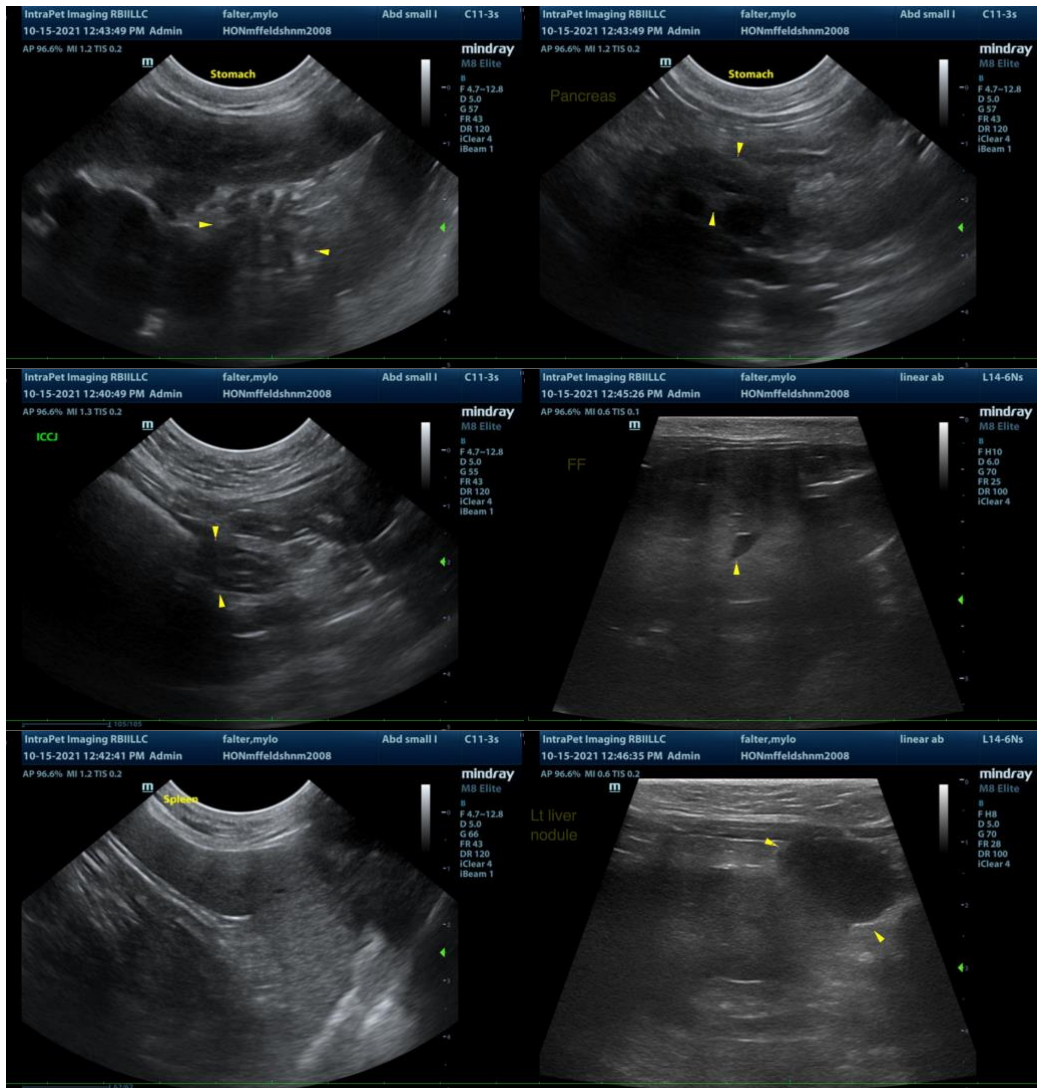
- The pancreatic changes are consistent with chronic pancreatitis
- Mild age-related renal pathology
- Bowel pattern consistent with inflammatory bowel disease with potential for emerging lymphoma

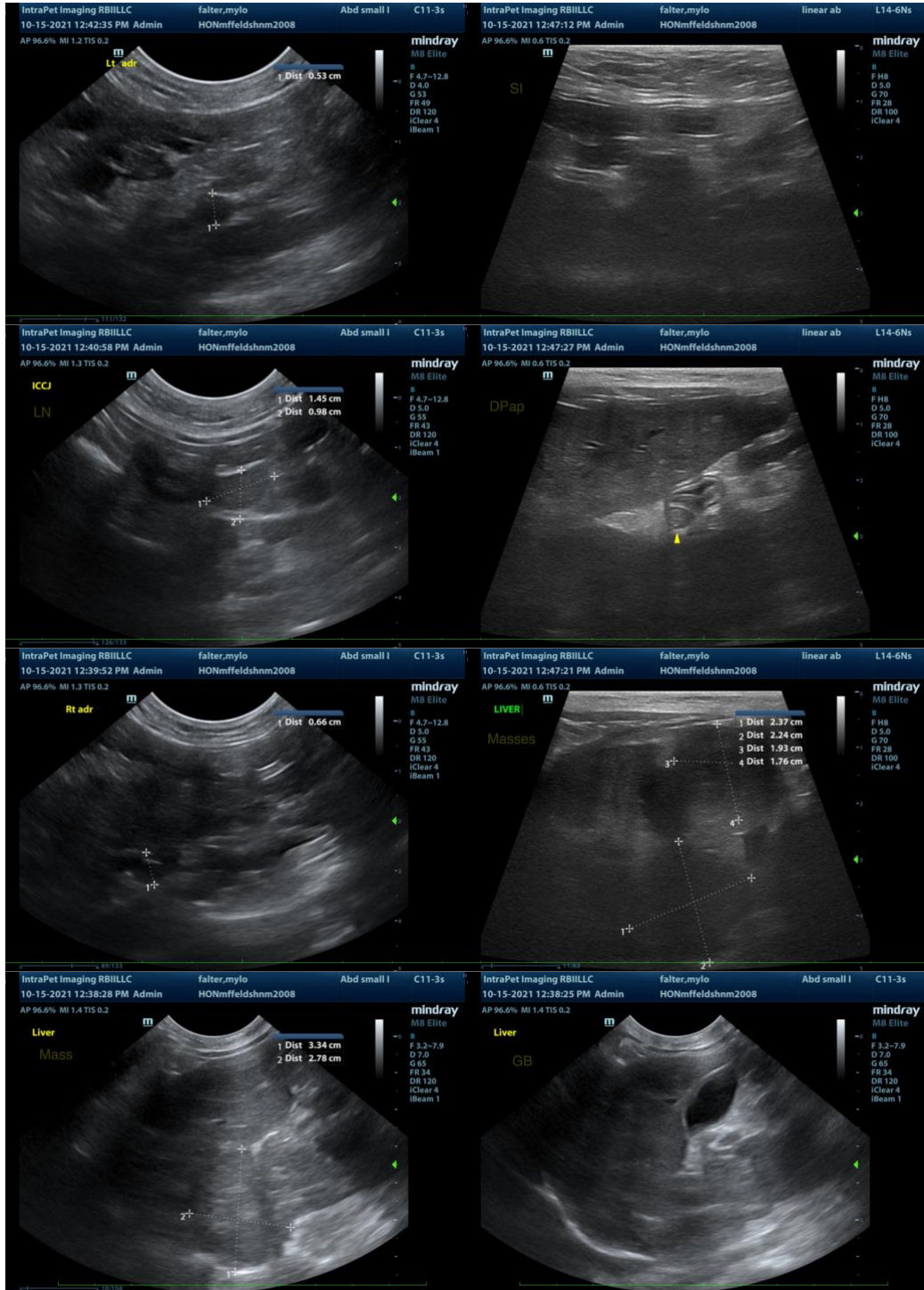
## **INTERPRETATION OF THE FINDINGS & FURTHER RECOMMENDATIONS**

- Three-view thoracic radiographs are recommended to assess for pulmonary metastases.
- Fine needle aspirates of the liver and spleen are recommended if clotting status is appropriate. A

25-gauge needle should be used.

- A GI panel including serum cobalamin, folate, TLI and PLI should also be considered.
- If the above diagnostics are inconclusive, an abdominal exploratory with liver, splenic, gastrointestinal and lymph node biopsies may be necessary to get a definitive diagnosis.





The information and recommendations provided are based on the images presented by the referring veterinarian. No evaluation can be communicated regarding pathology that was not visible in the image/video clips provided.

Thank you for this referral. If the clinical or image interpretation does not parallel your findings or if I can be of any further assistance please contact me.

**Andrea Nicastro**, DVM, Diplomate DACVIM (Small Animal Internal Medicine)  
info@SonoPath.com