



PATIENT PRESENTING CLINICAL SIGNS

Melanie Newsock History: Has been vomiting after eating, happens about 4x a month CBC/Chemistry/T4 WNL

SPECIES ULTRASONOGRAPHIC EXAMINATION OF THE ABDOMEN

Feline Urinary System

The **urinary bladder** wall is normal in thickness and the mucosal surface is smooth. The bladder is moderately distended. A scant amount of suspended, echogenic debris is observed within the lumen. No masses, inflammatory changes or calculi are observed. Ureteral papillae and visualized portion of the proximal urethra, visible to a depth of 1-2 cm, are normal.

BREED

DSH

The **left kidney** is normal size (3.24 cm in length); normal shape and architecture with smooth peripheral margins. There is a normal 1:3 cortex to medulla ratio with mild to moderate loss of corticomedullary distinction. There is no evidence of pyelectasia, nephroliths, infarcts or hydroureter. Renal vasculature is normal.

SEX

Spayed Female

The **right kidney** is normal size (3.81 cm in length); normal shape and architecture with smooth peripheral margins. There is a normal 1:3 cortex to medulla ratio with mild to moderate loss of corticomedullary distinction. There is no evidence of pyelectasia, nephroliths, infarcts or hydroureter. Renal vasculature is normal.

AGE

12 years

Adrenal Glands

WEIGHT

The **left adrenal gland** is normal size (0.27 cm width). Normal shape and glandular echogenicity. The phrenicoabdominal vein and surrounding vasculature are normal.

8.42 bs

The **right adrenal gland** is normal size (0.26 cm width). Normal shape and glandular echogenicity. The phrenicoabdominal vein and surrounding vasculature are normal.

INTERPRETED BY

Andrea Nicastro,
DVM, Diplomate
ACVIM (*Small Animal
Internal Medicine*)

Spleen

The **spleen** is normal in size (0.63 cm in width at the level of the hilus) with a normal capsular contour. There is appropriate echogenicity and echotexture. No focal lesions are observed. Splenic vasculature is normal.

IMAGING PERFORMED BY

Dr. Sheldon

Liver

The **liver** is subjectively normal in size with normal contours and structure. There is appropriate echogenicity and echotexture. No overt structural evidence of inflammatory, infiltrative, or regenerative pathology is evident. Vascular and biliary tracts are of normal volume with no evidence of congestion. No pathological hepatic lymphadenopathy observed.

HOSPITAL NAME

Advanced PetCare
of Oakland

The gall bladder is of normal contours and contains some dependent echogenic debris. The wall is normal in thickness. No choleliths are observed. The cystic and common bile ducts are normal/not seen.

REFERRING VET

Dr. Sheldon

Gastrointestinal

The **stomach and intestine** are free of stasis and exhibit normal peristaltic activity. The gastric lumen is not distended. The gastric wall and pylorus are normal in thickness with a normal layering pattern. The pyloric outflow tract is patent. The small intestinal lumen is not dilated. The small intestinal wall is normal to mildly thickened (up to 0.28 cm) with a normal layering pattern and appropriate mural detail. There is disruption in the normal 1:3 muscularis: mucosal ratio in some segments. Discreet masses are not identified. The ileocecal colic junction and colonic wall are normal. The colonic lumen contains shadowing fecal material. There is no evidence of an obstructive pattern.

INVOICE

11827

DATE

10.13.22

Pancreas

The region of the **pancreas** is isoechoic relative to surrounding omental fat. No obvious parenchymal abnormalities are observed. There is no evidence of regional inflammation or effusion.

Free Abdomen

There is no evidence of free fluid. A 1.27 x 0.38 cm **lymph node** is observed in the caudal abdomen, near the aortic trifurcation.

ULTRASONOGRAPHIC FINDINGS

Primary Findings

- Bowel pattern suggestive of inflammatory bowel disease. There is some potential for emerging lymphoma. However, neoplasia is considered less likely at this time.

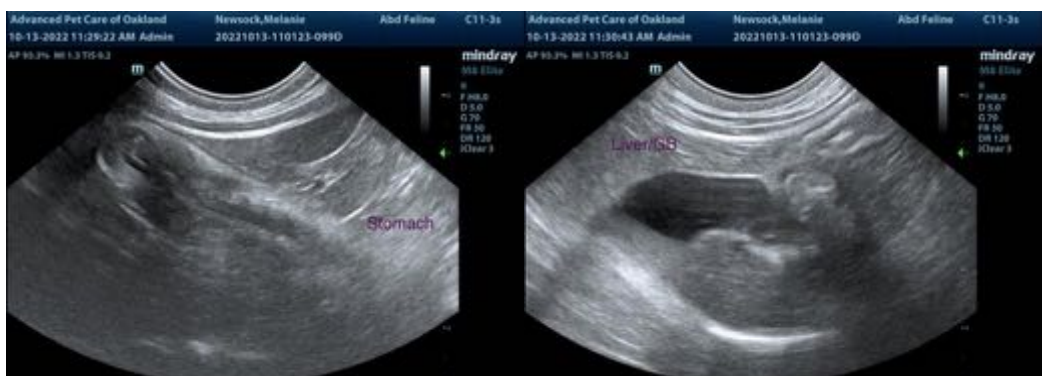
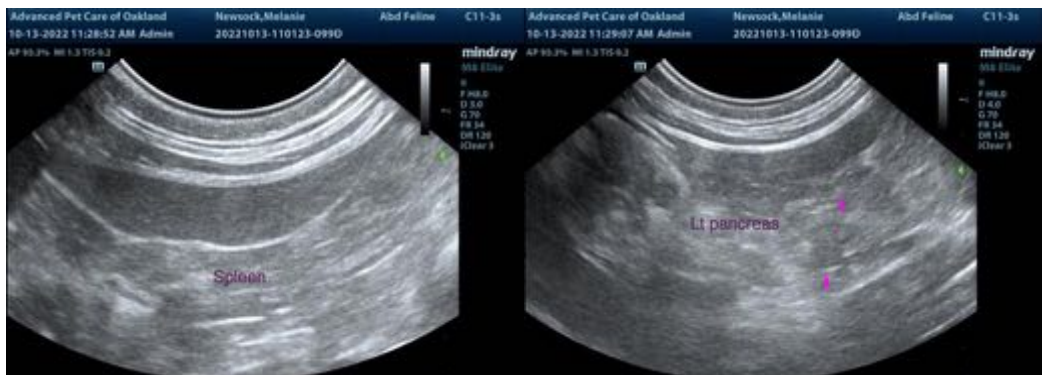
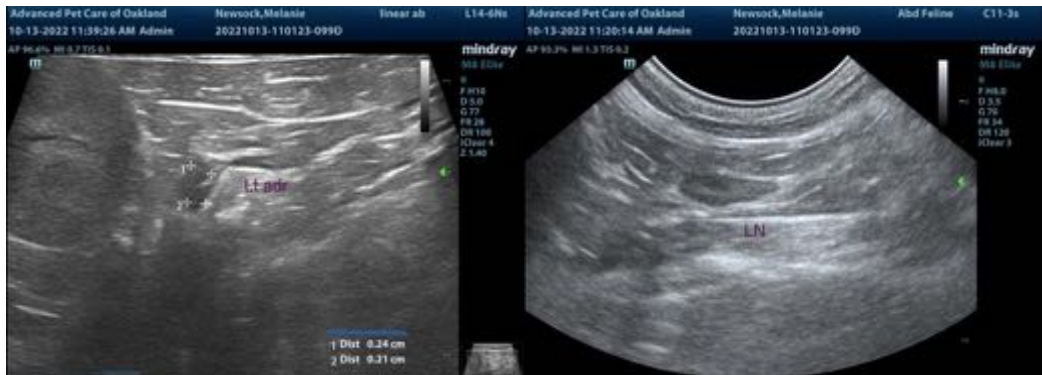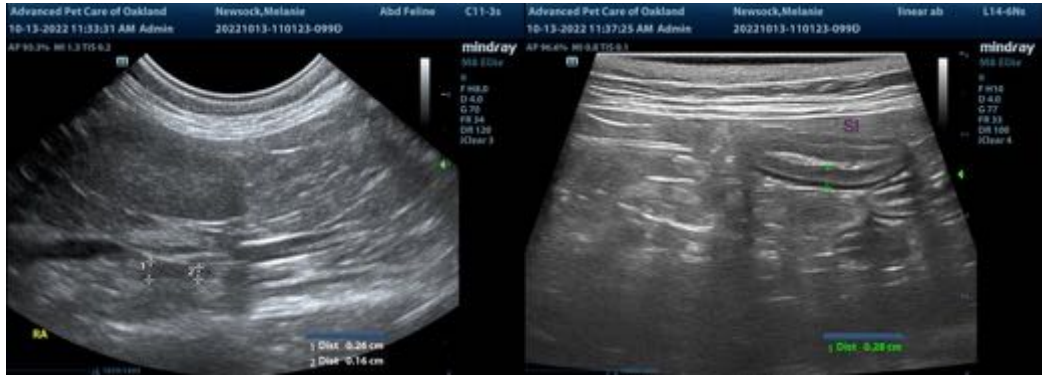
Secondary Findings

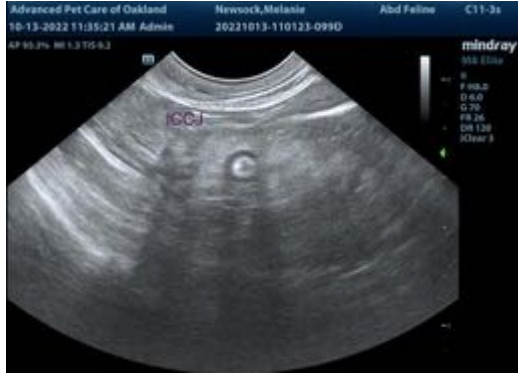- The prominent caudal abdominal lymph node could be consistent with lymphoid hyperplasia, reactive lymphadenopathy or emerging neoplasia.

INTERPRETATION OF THE FINDINGS & FURTHER RECOMMENDATIONS

The following diagnostic/treatment recommendations can be considered:

1. Serum cobalamin, folate, PLI and TLI
2. A fecal evaluation for ova/Giardia
3. A 6-week limited antigen diet trial to assess for food allergies
4. For patients where chronic vomiting is present but additional diagnostics are not to be performed, consider triple therapy as empirical treatment for Helicobacter gastritis:
 - a. Amoxicillin: 10-22 mg/kg PO q 12 hours x 14-21 days
 - b. Metronidazole: 10-15 mg/kg PO q 12 hours for 14-21 days
 - c. Omeprazole: 0.7 mg/kg PO q 24 hours for 14-21 days
 - d. (+/- the addition of Bismuth subsalicylate: 3.85 mg/kg PO q 6-8 hours x 14-21 days)
5. Also consider heartworm antigen and antibody testing as heartworm disease can be a cause of chronic vomiting in cats.
6. Three-view thoracic radiographs are recommended to assess for occult esophageal disease.
7. If the above diagnostics/therapeutics are inconclusive, endoscopic or surgical gastrointestinal biopsies may be warranted.





The information and recommendations provided are based on the images presented by the referring veterinarian/sonographer. No evaluation can be communicated regarding pathology that was not visible in the image/video clips provided.

Thank you for this referral. If the clinical or image interpretation does not parallel your findings or if I can be of any further assistance, please contact me.

Andrea Nicastro, MPH, DVM, Diplomate DACVIM (Small Animal Internal Medicine)
info@SonoPath.com