



PATIENT

Willy Frooman

SPECIES

Canine

BREED

Sheepdog Mix

SEX

Male, neutered

AGE

10 Yrs.

WEIGHT

25.2 lbs.

INTERPRETED BY

Andrea Nicastro, DVM,
Diplomate ACVIM
(Small Animal Internal
Medicine)

**IMAGING
PERFORMED BY**

Dr. Goodman

HOSPITAL NAME

Evandale Blue-Ash Pet
Hospital

REFERRING VET

Dr. Goodman

INVOICE

12352

DATE

10/12/21

PRESENTING CLINICAL SIGNS

History: Presented today for abdominal ultrasound d/t elevated ALP. We have been monitoring his ALP for the last 2 years and it has decreased and then elevated again, urine is dilute. History of cystotomy in March 2020. Has been doing well at home, e/d well and acting normal. Owner has noted signs of increased panting, hunger and urination. Currently on Hill's c/d food. LDDS performed 8/16/2021 and came back inconclusive for diagnosis.

Abnormal PE/Chem/CBC/UA Results: 5/17/19: ALP - 243 3/23/2020: ALP - 387 11/25/2020: ALP - 277 7/15/21: ALP - 344 8/17/21: Cortisol baseline - 2.2 (administered 0.01mg/kg, 2mg/ml dex IV) 4 hours post - <1.00 8 hour post - 1.1

ULTRASONOGRAPHIC EXAMINATION OF THE ABDOMEN

Urinary System

The urinary bladder is moderately distended. The wall is normal in thickness with a smooth mucosal surface. A few tiny cystic calculi are visualized. Luminal contents are anechoic. The region of the trigone and the visible portion of the proximal urethra are normal.

The prostate is normal in size (1.31 cm in width) and shape. Parenchyma is homogenous. The prostatic urethra appears normal without evidence of dilation or obstruction.

The left kidney is normal in size (4.60 cm in length) with a normal shape, smooth peripheral margins and normal internal architecture. There is mild loss of corticomedullary distinction. Several hyperechoic shadowing diverticular foci are observed. Several small nephroliths are visualized. There is no evidence of pyelectasia, infarcts or hydronephrosis.

The right kidney is normal size (4.64 cm in length) with a normal shape, smooth peripheral margins and normal internal architecture. There is mild loss of corticomedullary distinction. Several hyperechoic shadowing diverticular foci are observed. Several small nephroliths are visualized. There is no evidence of pyelectasia, infarcts or hydronephrosis.

Adrenal Glands

The left adrenal gland is upper limits of normal size (0.67 cm at cranial pole) (0.68 cm at caudal pole) (2.06 cm in length); normal shape; homogenous parenchyma. The glandular echogenicity and detail are unremarkable. Capsule, cortex, and medullary definition are normal. The phrenicoabdominal vein and surrounding vasculature are normal.

The right adrenal gland is mildly enlarged (0.80 cm at cranial pole) (0.82 cm at caudal pole) (3.05 cm in length); normal shape; homogenous parenchyma. The glandular echogenicity and detail are unremarkable. Capsule, cortex, and medullary definition are normal. The phrenicoabdominal vein and surrounding vasculature are normal.

Spleen

The spleen is normal in size (1.13 cm in width at the level of the hilus) with a normal capsular contour. There is appropriate echogenicity and echotexture. No focal lesions are observed. Splenic vasculature is normal.

Liver

The liver is subjectively prominent in size with swollen curvilinear peripheral contours. The parenchyma is isoechoic relative to the spleen and exhibits mild heterogeneity. No distinct focal lesions are observed. Hepatic vasculature and biliary tracts are of normal volume with no evidence of congestion. The gall bladder lumen is moderately distended. The wall is normal in thickness. Several polypoid like lesions are arising from the luminal surface. A small amount of aggregated echogenic mostly gravity-dependent debris is also seen within the lumen. The cystic and common bile ducts are normal/not seen.



PATIENT

Willy Frooman

SPECIES

Canine

BREED

Sheepdog Mix

SEX

Male, neutered

AGE

10 Yrs.

WEIGHT

25.2 lbs.

INTERPRETED BY

Andrea Nicastro, DVM,
Diplomate ACVIM
(Small Animal Internal
Medicine)

**IMAGING
PERFORMED BY**

Dr. Goodman

HOSPITAL NAME

Evandale Blue-Ash Pet
Hospital

REFERRING VET

Dr. Goodman

INVOICE

12352

DATE

10/12/21

Gastrointestinal

The stomach and intestine are free of stasis and exhibit normal peristaltic activity. The gastric lumen is not distended. The gastric wall and pylorus are normal in thickness with a normal layering pattern. The pyloric outflow tract is patent. The small intestinal lumen is not dilated. The small intestinal wall thickness is normal with a normal layering pattern and appropriate mural detail. Discreet masses are not identified. The colonic wall is normal. No obstructive disease is noted.

Pancreas

The region of the pancreas is isoechoic relative to surrounding omental fat. No obvious parenchymal abnormalities are observed. There is no evidence of regional inflammation or effusion.

Free Abdomen

The peritoneal cavity is normal. There is no evidence of inflammation or effusion. The abdominal lymph nodes are normal/not visible.

ULTRASONOGRAPHIC FINDINGS

Primary Findings:

- The diffuse hepatic changes are non-specific and could be consistent with vacuolar hepatopathy, regenerative nodular hyperplasia, and/or age-related remodeling. Inflammatory and infiltrative disease are considered less likely.
- Borderline to mild bilateral adrenomegaly.
- Small cystic calculi

Secondary Findings:

- Bilateral nephropathy with dystrophic mineralization and non-obstructive nephrolithiasis.

INTERPRETATION OF THE FINDINGS & FURTHER RECOMMENDATIONS

- Given the clinical history, sonographic changes and equivocal low-dose dexamethasone test results, consider an ACTH stimulation test +/- a full adrenal panel (send to the University of Tennessee Endocrinology Lab) to further assess for hyperadrenocorticism.
- A urine culture and sensitivity can also be considered to assess for occult pyelonephritis as a cause for PU/PD.
- Regarding the cystic calculi, a cystotomy with stone removal, analysis and culture can be considered. Alternatively, medical dissolution of the stones can be considered with a prescription renal diet and broad-spectrum antibiotic therapy. If there is no improvement in stone size after 4 weeks of therapy, a cystotomy should be reconsidered. If the stone size is reduced, continue therapy until complete dissolution has been achieved.



PATIENT

Willy Frooman

SPECIES

Canine

BREED

Sheepdog Mix

SEX

Male, neutered

AGE

10 Yrs.

WEIGHT

25.2 lbs.

INTERPRETED BY

Andrea Nicastro, DVM,
Diplomate ACVIM
(Small Animal Internal
Medicine)

IMAGING PERFORMED BY

Dr. Goodman

HOSPITAL NAME

Evandale Blue-Ash Pet
Hospital

REFERRING VET

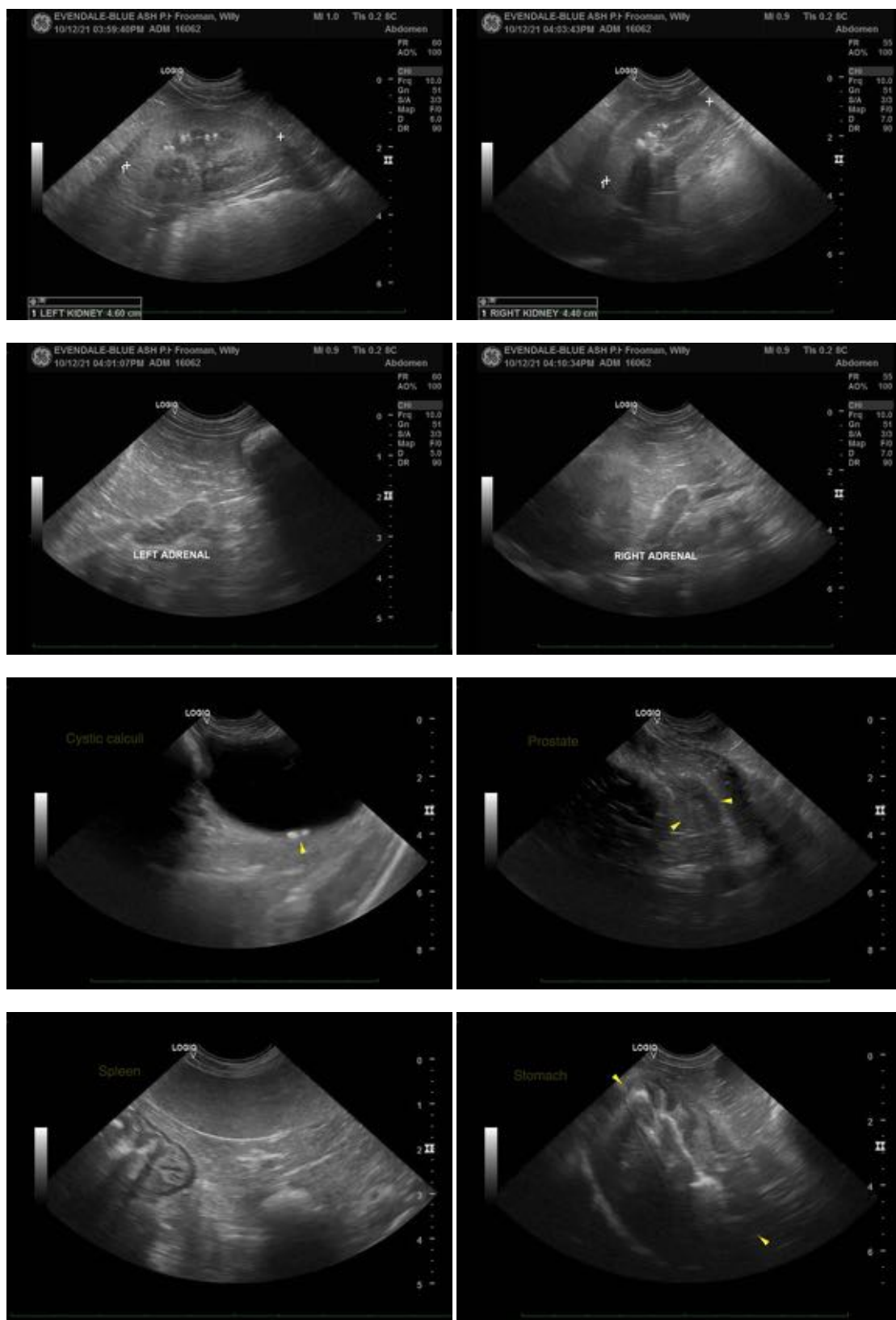
Dr. Goodman

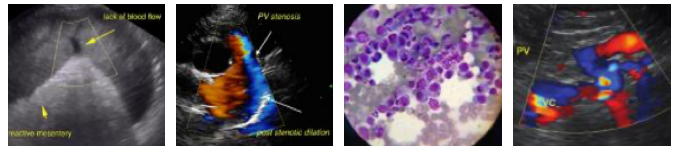
INVOICE

12352

DATE

10/12/21





PATIENT

Willy Frooman

SPECIES

Canine

BREED

Sheepdog Mix

SEX

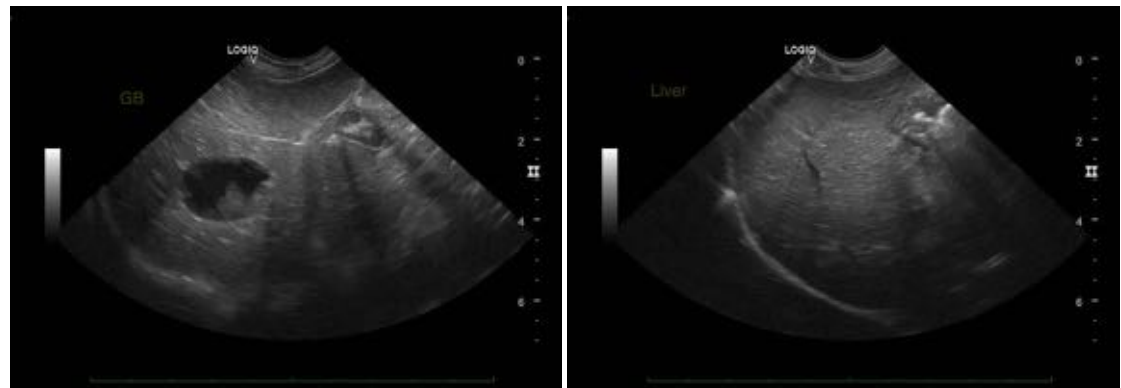
Male, neutered

AGE

10 Yrs.

WEIGHT

25.2 lbs.



The information and recommendations provided are based on the images presented by the referring veterinarian. No evaluation can be communicated regarding pathology that was not visible in the image/video clips provided.

Thank you for this referral. If the clinical or image interpretation does not parallel your findings or if I can be of any further assistance please contact me.

Andrea Nicastro, DVM, Diplomate ACVIM (*Small Animal Internal Medicine*)

Andrea.nicastro@sonopath.com

INTERPRETED BY

Andrea Nicastro, DVM,
Diplomate ACVIM
(*Small Animal Internal Medicine*)

IMAGING PERFORMED BY

Dr. Goodman

HOSPITAL NAME

Evandale Blue-Ash Pet
Hospital

REFERRING VET

Dr. Goodman

INVOICE

12352

DATE

10/12/21