



## PATIENT PRESENTING CLINICAL SIGNS

Mo Coppola History: Elevated ALP, asymptomatic. No current meds.  
Abnormal PE/Chem/CBC/UA Results: ALP 1664 (131 H)

## SPECIES ULTRASONOGRAPHIC EXAMINATION OF THE ABDOMEN

### Canine *Urinary System*

The **urinary bladder** wall is normal in thickness and the mucosal surface is smooth. The bladder lumen is moderately distended with anechoic urine. No masses, inflammatory changes or calculi are observed. Ureteral papillae and visualized portion of the proximal urethra, visible to a depth of 2-3 cm, are normal.

### BREED

Mixed

The **prostate** is normal in size (0.89 cm in width) and shape. Parenchyma is homogenous. The prostatic urethra appears normal without evidence of dilation or obstruction.

### SEX

Neutered Male

The **left kidney** is normal size (7.04 cm in length); with a slightly irregular shape, smooth peripheral margins, and normal internal architecture. There is mild to moderate loss of corticomedullary distinction. Pinpoint focus of mineralization are observed within the cortex. Several hyperechoic shadowing diverticular foci are observed. There is no evidence of pyelectasia or hydronephrosis. Renal vasculature is normal.

### AGE

9 years

The **right kidney** is normal size (6.86 cm in length); with a normal shape, smooth peripheral margins, and normal internal architecture. There is mild loss of corticomedullary distinction. Several hyperechoic shadowing diverticular foci are observed. There is no evidence of pyelectasia, infarcts or hydronephrosis. Renal vasculature is normal.

### WEIGHT

89.4 lbs

### *Adrenal Glands*

The **left adrenal gland** is normal size (0.73 cm at cranial pole) (0.82 cm at caudal pole) (2.38 cm in length); normal shape; homogenous parenchyma. The glandular echogenicity and detail are unremarkable. Capsule, cortex, and medullary definition are normal. The phrenicoabdominal vein and surrounding vasculature are normal.

## INTERPRETED BY

Andrea Nicastro,  
DVM, Diplomate  
ACVIM (*Small Animal  
Internal Medicine*)

The **right adrenal gland** is normal size (1.09 cm at cranial pole) (0.77 cm at caudal pole) (2.98 cm in length); normal shape; homogenous parenchyma. The glandular echogenicity and detail are unremarkable. Capsule, cortex, and medullary definition are normal. The phrenicoabdominal vein and surrounding vasculature are normal.

## IMAGING PERFORMED BY

Shari Reffi, CVT

### *Spleen*

The **spleen** is normal in size (2.07 cm in width at the level of the hilus) with a normal capsular contour. There is appropriate echogenicity and echotexture. No focal lesions are observed. Splenic vasculature is normal.

## HOSPITAL NAME

Newton VH

### *Liver*

The **liver** is subjectively prominent in size with normal curvilinear peripheral contours. The parenchyma is isoechoic relative to the spleen and homogenous in appearance. No focal lesions are observed. Hepatic vasculature and intrahepatic biliary tracts are of normal volume with no evidence of congestion.

## REFERRING VET

Dr. Wyman-  
Greenwald

The **gall bladder** lumen is moderately distended. The wall is thin and smooth. Luminal contents are anechoic. The cystic and common bile ducts are normal/not seen.

## INVOICE

11799

### *Gastrointestinal*

The **stomach and intestine** are free of stasis and exhibit normal peristaltic activity. The gastric lumen is not distended. The gastric wall and pylorus are normal in thickness with a normal layering pattern. The pyloric

## DATE

10.10.22

outflow tract is patent. The small intestinal lumen is not dilated. The small intestinal wall thickness is normal with a normal layering pattern and appropriate mural detail. Discreet masses are not identified. The colonic wall is normal. There is no evidence of an obstructive pattern.

### **Pancreas**

The region of the **pancreas** is isoechoic relative to surrounding omental fat. No obvious parenchymal abnormalities are observed. There is no evidence of regional inflammation or effusion.

### **Free Abdomen**

The **peritoneal cavity** is normal. There is no evidence of inflammation or effusion. A 2.21 cm medial iliac **lymph node** is visualized. The node is normal in shape and echogenicity.

### **Other**

A **brief echocardiogram** reveals no evidence of pericardial effusion or obvious right atrial/auricular mass.

## **ULTRASONOGRAPHIC FINDINGS**

### **Primary Findings**

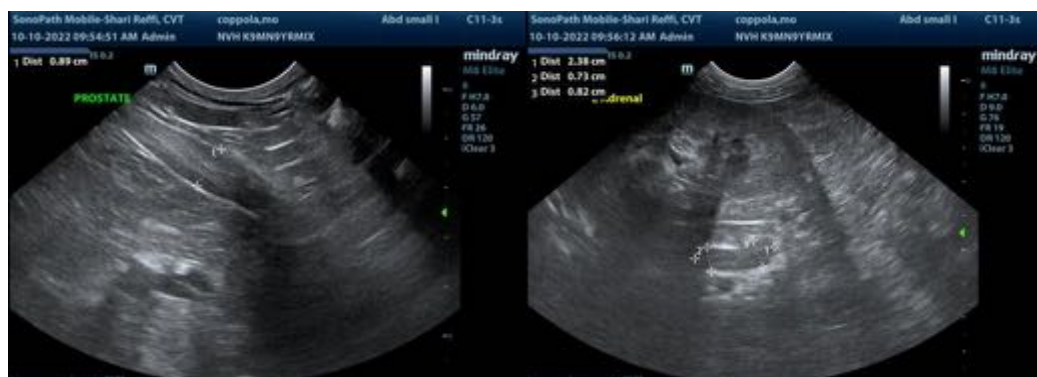- The diffuse hepatic changes are non-specific and could be consistent with vacuolar hepatopathy, regenerative nodular hyperplasia, and/or age-related remodeling. Inflammatory and infiltrative disease are considered less likely.

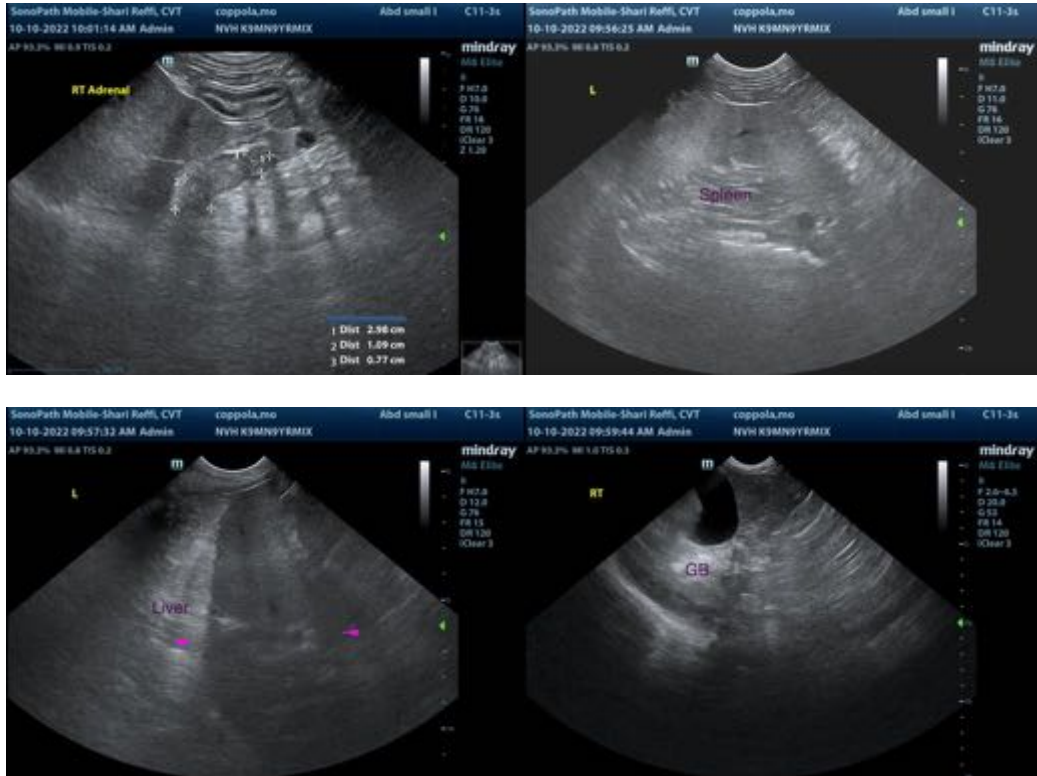
### **Secondary Findings**

- Mild bilateral age-related renal changes with dystrophic mineralization

## **INTERPRETATION OF THE FINDINGS & FURTHER RECOMMENDATIONS**

Serial monitoring (i.e., every 3-4 months) of the patient's liver values is recommended. If values continue to increase, a repeat abdomen ultrasound +/- a more advanced hepatic work-up (i.e., tissue sampling) may be warranted.





The information and recommendations provided are based on the images presented by the referring veterinarian/sonographer. No evaluation can be communicated regarding pathology that was not visible in the image/video clips provided.

Thank you for this referral. If the clinical or image interpretation does not parallel your findings or if I can be of any further assistance, please contact me.

**Andrea Nicastro, MPH, DVM, Diplomate DACVIM (Small Animal Internal Medicine)**  
[info@SonoPath.com](mailto:info@SonoPath.com)