



PATIENT PRESENTING CLINICAL SIGNS

Bash Sequeria History: Bash was diagnosed with pancreatitis on 9/30. On 10/4 he was hospitalized at Wilvet for 24 hours for vomiting, lethargy, and painful abdomen. He has done well at home until yesterday. Yesterday Bash was hiding in his kennel and not interacting with his owner's. This morning he was intermittently yelping. Owner gave him a dose of Gabapentin 100mg capsule. Bash is still eating and drinking and no vomiting

SPECIES

Canine

ULTRASONOGRAPHIC EXAMINATION OF THE ABDOMEN

Urinary System

BREED

Cavalier KC

The **urinary bladder** wall is normal in thickness and the mucosal surface is smooth. The bladder lumen is moderately distended with anechoic urine. No masses, inflammatory changes or calculi are observed. Ureteral papillae and visualized portion of the proximal urethra, visible to a depth of 2 cm, are normal.

SEX

Neutered Male

The **prostate** is normal in size (0.71 cm in width) and shape. Parenchyma is homogenous. The prostatic urethra appears normal without evidence of dilation or obstruction.

AGE

3 years

The **left kidney** is normal size (4.91 cm in length); normal shape and architecture with smooth peripheral margins. There is a normal 1:3 cortex to medulla ratio with normal corticomedullary distinction. There is no evidence of pyelectasia, nephroliths, infarcts or hydroureter. Renal vasculature is normal.

WEIGHT

11.4 kg

The **right kidney** is normal size (4.96 cm in length); normal shape and architecture with smooth peripheral margins. There is a normal 1:3 cortex to medulla ratio with normal corticomedullary distinction. There is no evidence of pyelectasia, nephroliths, infarcts or hydroureter. Renal vasculature is normal.

Adrenal Glands

The **left adrenal gland** is normal size (0.41 cm at cranial pole) (0.41 cm at caudal pole); normal shape; homogenous parenchyma. The glandular echogenicity and detail are unremarkable. Capsule, cortex, and medullary definition are normal. The phrenicoabdominal vein and surrounding vasculature are normal.

INTERPRETED BY

Andrea Nicastro,
DVM, Diplomate
ACVIM (Small Animal
Internal Medicine)

The region of the **right adrenal gland** is evaluated. No obvious pathology is observed.

IMAGING PERFORMED BY

Dr. Brittany Gardner
DVM

Spleen

The **spleen** is normal in size (1.51 cm in width at the level of the hilus) with a normal capsular contour. There is appropriate echogenicity and echotexture. No focal lesions are observed. Splenic vasculature is normal.

HOSPITAL NAME

Wilvet Salem

Liver

The **liver** is subjectively normal in size with normal contours and structure. There is appropriate echogenicity and echotexture. No overt structural evidence of inflammatory, infiltrative, or regenerative pathology is evident. Vascular and biliary tracts are of normal volume with no evidence of congestion. No pathological hepatic lymphadenopathy observed.

REFERRING VET

Dr. Brittany Gardner
DVM

The **gall bladder** lumen is moderately distended. The wall is thin and smooth. Luminal contents are anechoic. The cystic and common bile ducts are normal/not seen.

INVOICE

11788

Gastrointestinal

The **gastric lumen** is mildly distended with irregular hyperechoic shadowing structures. The gastric wall and pylorus are normal in thickness with a normal layering pattern. The pyloric outflow tract appears patent. The small intestinal lumen is not dilated. The small intestinal wall thickness is normal with a normal layering pattern and appropriate mural detail. Discreet masses are not identified. The colonic wall is normal. There is no evidence of an obstructive pattern.

DATE

10.10.22

Pancreas

The region of the **pancreas** is isoechoic relative to surrounding omental fat. No obvious parenchymal abnormalities are observed. There is no evidence of regional inflammation or effusion.

Free Abdomen

The **peritoneal cavity** is normal. There is no evidence of inflammation or effusion. A few prominent mesenteric **lymph nodes** are visualized, the largest measuring 1.15 cm in length.

ULTRASONOGRAPHIC FINDINGS

Primary Findings

- The shadowing structures within the gastric lumen are most consistent with kibble. However, nonobstructive foreign material cannot be completely excluded.

Secondary Findings

- The lymph node changes are most consistent with reactive lymphadenitis or lymphoid hyperplasia.

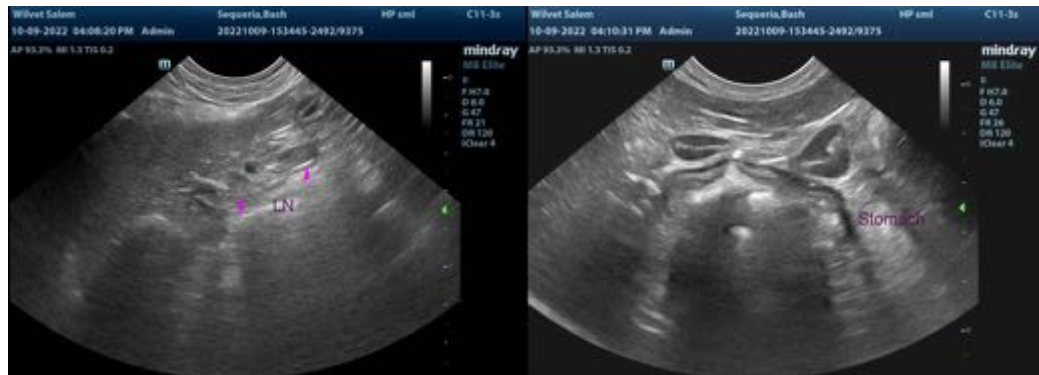
*An obvious cause for the patient's clinical signs is not identified in this study.

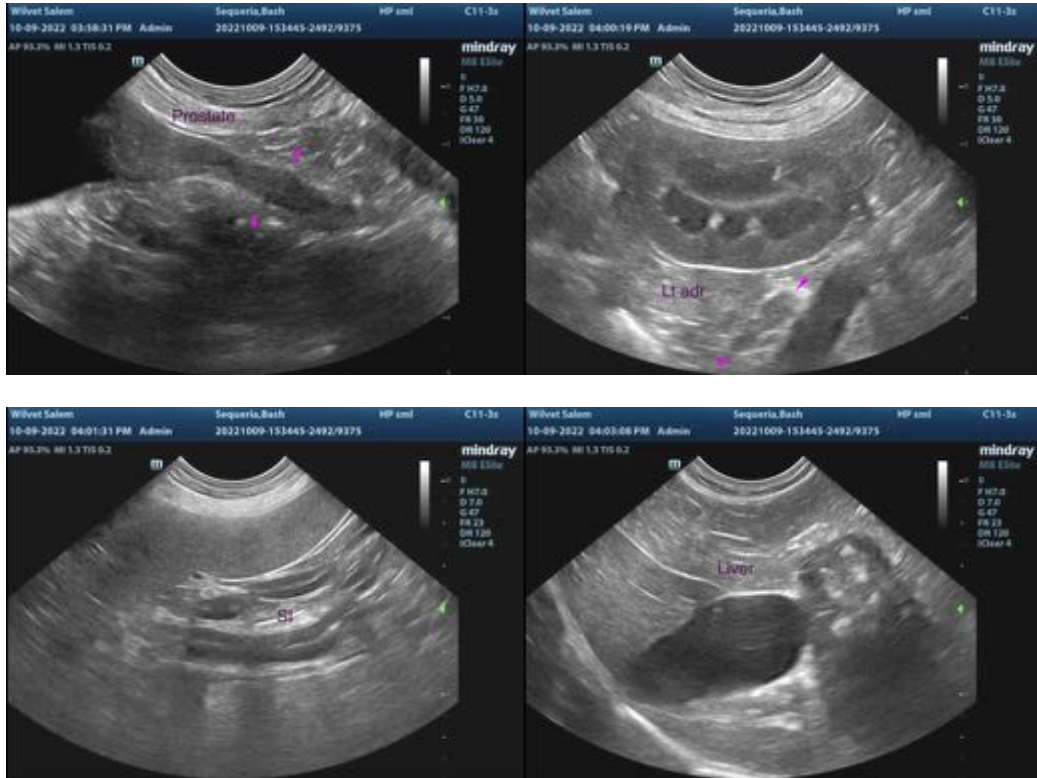
INTERPRETATION OF THE FINDINGS & FURTHER RECOMMENDATIONS

Consider thorough orthopedic and neurologic evaluations to assess for nonmetabolic causes of pain.

Also consider a fecal evaluation for ova and Giardia, a cPLI +/- a full GI panel including serum cobalamin and folate, TLI and PLI to further assess for pancreatitis and maldigestion/malabsorption.

If GI signs persist, a resting cortisol level (to screen for hypoadrenocorticism) +/- a more advanced workup may be warranted.





The information and recommendations provided are based on the images presented by the referring veterinarian/sonographer. No evaluation can be communicated regarding pathology that was not visible in the image/video clips provided.

Thank you for this referral. If the clinical or image interpretation does not parallel your findings or if I can be of any further assistance, please contact me.

Andrea Nicastro, MPH, DVM, Diplomate DACVIM (Small Animal Internal Medicine)
info@SonoPath.com