

PATIENT PRESENTING CLINICAL SIGNS

Arya Grant
History: Elevated ALT
Abnormal PE/Chem/CBC/UA Results: ALT 450

SPECIES ULTRASONOGRAPHIC EXAMINATION OF THE ABDOMEN

Canine

Urinary System

The urinary bladder, trigone, and pelvic urethra are normal in thickness and the mucosal surface is smooth. The bladder lumen is mildly distended with anechoic urine. No masses, inflammatory changes or calculi are observed. Ureteral papillae and visualized portion of the proximal urethra, visible to a depth of 2 cm, are normal.

BREED

Mix

SEX

Spayed Female

The left kidney presented normal size (5.77 cm in length); normal shape and architecture with smooth peripheral margins. There is a normal 1:3 cortex to medulla ratio with normal corticomedullary distinction. There is no evidence of pyelectasia, nephroliths, infarcts or hydronephrosis. Renal vasculature is normal.

AGE

5 Years

The right kidney presented normal size (5.92 cm in length); normal shape and architecture with smooth peripheral margins. There is a normal 1:3 cortex to medulla ratio with normal corticomedullary distinction. There is no evidence of pyelectasia, nephroliths, infarcts or hydronephrosis. Renal vasculature is normal.

WEIGHT

45 Lbs.

Adrenal Glands

The left adrenal gland is normal size (0.47 cm at cranial pole) (0.49 cm at caudal pole) (2.86 cm in length); normal shape; homogenous parenchyma. The glandular echogenicity and detail are unremarkable. Capsule, cortex, and medullary definition are normal. The phrenicoabdominal vein and surrounding vasculature are normal.

INTERPRETED BY

Andrea Nicastro, DMV,
Diplomate DACVIM
(Small Animal
Internal Medicine)

The right adrenal gland is normal size (1.52 cm at cranial pole) (0.40 cm at caudal pole) (2.06 cm in length); normal shape; homogenous parenchyma. The glandular echogenicity and detail are unremarkable. Capsule, cortex, and medullary definition are normal. The phrenicoabdominal vein and surrounding vasculature are normal.

IMAGING PERFORMED BY

Shari Reffi, CVT

Spleen

The spleen is normal in size (1.95 cm in width at the level of the hilus) with a normal capsular contour. There is appropriate echogenicity and echotexture. No focal lesions are observed. Splenic vasculature is normal.

HOSPITAL NAME

Newton Vet

Liver

The liver is subjectively normal in size with normal contours and structure. There is appropriate echogenicity and echotexture. No overt structural evidence of inflammatory, infiltrative or regenerative pathology is evident. Vascular and biliary tracts are of normal volume with no evidence of congestion. No pathological hepatic lymphadenopathy observed.

REFERRING VET

Dr. Wyman-Greenwald

The gall bladder lumen is moderately distended. The wall is thin and smooth. Luminal contents are anechoic. The cystic and common bile ducts are normal.

INVOICE

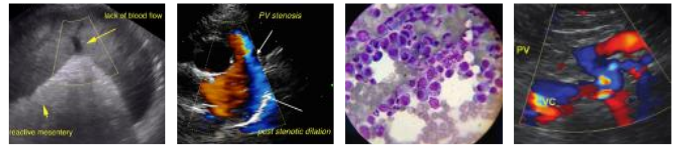
10108

Gastrointestinal

The gastric lumen is mildly distended with ingesta. The gastric wall and pylorus are normal in thickness with a normal layering pattern. The small intestinal lumen is segmentally dilated with chyme. The small intestinal wall thickness is normal with a normal layering pattern and appropriate mural detail. Discreet masses are not identified. The colonic wall is normal. No obstructive or overt infiltrative disease is noted.

DATE

1/6/22



PATIENT

Pancreas

Arya Grant

The region of the pancreas is isoechoic relative to surrounding omental fat. No obvious parenchymal abnormalities are observed. There is no evidence of regional inflammation or effusion.

SPECIES

Free Abdomen

Canine

The peritoneal cavity is normal. There is no evidence of inflammation or effusion. The abdominal lymph nodes are normal/not visible.

ULTRASONOGRAPHIC FINDINGS

BREED

- Unremarkable abdomen.
- An obvious cause for the elevated liver enzymes is not identified in the study. However, a microscopic hepatopathy (i.e., bacterial cholangiohepatitis, Leptospirosis, chronic active hepatitis, hepatotoxicity, infiltrative neoplasia (less likely)) cannot be excluded.

Mix

SEX

Spayed Female

INTERPRETATION OF THE FINDINGS & FURTHER RECOMMENDATIONS

AGE

- Leptospirosis testing, including blood-in urine PCR, serology is recommended.
- Cytologic evaluation of the liver should be considered in this patient if clotting status is appropriate. A fine needle aspirate using a 25-gauge needle is recommended. If cytologic evaluation is inconclusive, consider a surgical liver biopsy with aerobic and anaerobic bile cultures and acquisition of additional hepatic tissue samples for copper quantitation.
- If a conservative approach is desired, consider empirical treatment for bacterial cholangiohepatitis (amoxicillin-clavulanic acid, Denamarin Advanced). If no improvement in the liver values is seen within 7-10 days of initiating therapy, antibiotics should be discontinued, and hepatic tissue sampling reconsidered. If liver values improve, continue therapy for at least 4-6 weeks and 1 week beyond normalization of the liver values.

5 Years

WEIGHT

45 Lbs.

INTERPRETED BY

Andrea Nicastro, DMV,
Diplomate DACVIM
(Small Animal
Internal Medicine)

IMAGING PERFORMED BY

Shari Reffi, CVT

HOSPITAL NAME

Newton Vet

REFERRING VET

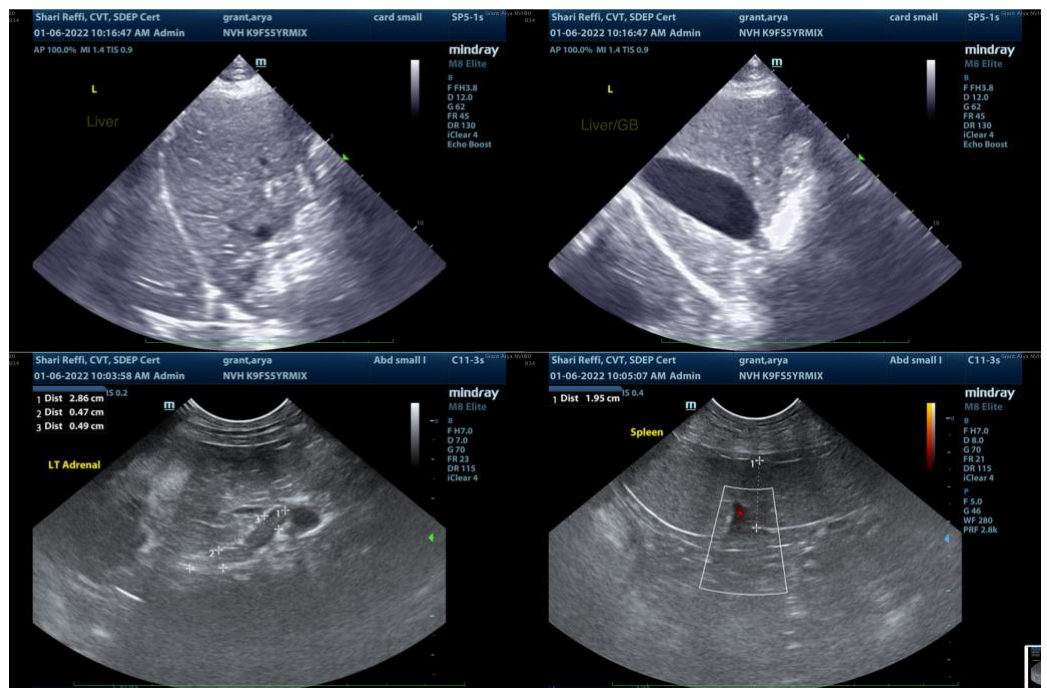
Dr. Wyman-Greenwald

INVOICE

10108

DATE

1/6/22





PATIENT

Arya Grant

SPECIES

Canine

BREED

Mix

SEX

Spayed Female

AGE

5 Years

WEIGHT

45 Lbs.

INTERPRETED BY

Andrea Nicastro, DMV,
Diplomate DACVIM
(Small Animal
Internal Medicine)

IMAGING PERFORMED BY

Shari Reffi, CVT

HOSPITAL NAME

Newton Vet

REFERRING VET

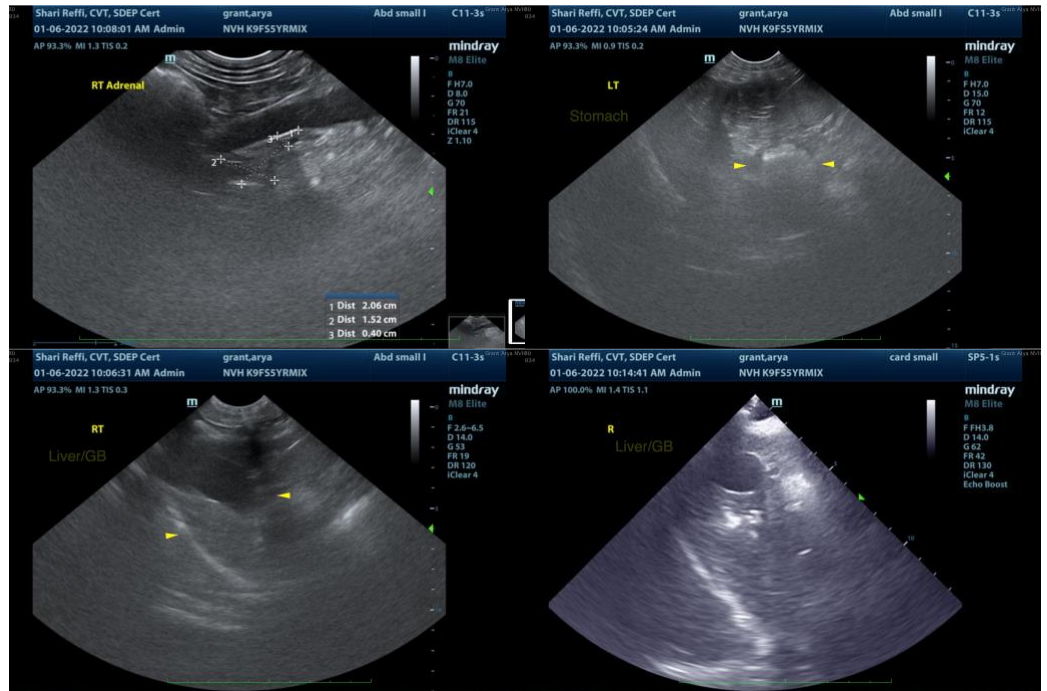
Dr. Wyman-Greenwald

INVOICE

10108

DATE

1/6/22



The information and recommendations provided are based on the images presented by the referring veterinarian. No evaluation can be communicated regarding pathology that was not visible in the image/video clips provided.

Thank you for this referral. If the clinical or image interpretation does not parallel your findings or if I can be of any further assistance, please contact me.

Andrea Nicastro, DVM, Diplomate DACVIM (Small Animal Internal Medicine)
info@SonoPath.com