



PATIENT

Russell Foley

SPECIES

Canine

BREED

Great Dane

SEX

Male, neutered

AGE

3 Yrs. 8 months

WEIGHT

57.7 kg.

INTERPRETED BY

Andrea Nicastro, DVM,
Diplomate ACVIM
(Small Animal Internal
Medicine)

IMAGING PERFORMED BY

Dr. Chmielinski

HOSPITAL NAME

Apex VS

REFERRING VET

Dr. Bregliano

INVOICE

13374

DATE

1/5/26

PRESENTING CLINICAL SIGNS

History: Presented at ER clinic on Jan 4 with a history of Russell has a history of intermittent, on-and-off vomiting for the past few weeks. The episodes became more severe on Wednesday, at which point he was unable to keep anything down. He was started on a bland diet of rice and cottage cheese in small, frequent meals (approximately half a cup, 4 times a day), which he was able to keep down. Recheck today for vomiting. He just went home to check on him and massive puddle of drool, gums are super white.

Abnormal PE/Chem/CBC/UA Results: Vital Signs: Temperature [Celsius]: 39.0, Heart Rate/min (HR): 100, HR: Pulse Ratio: 1:1, Respiratory Rate/min: 26, Respiratory Effort: 0, Mucus Membranes/CRT: pink, moist/ CRT < 2 sec, Mentation: BAR, Hydration: Adequate, BCS (scale 1 to 5): 3/5, CBC mild thrombocytopenia and mild hemoconcentration Chemistry wnl. The patient was sedated with Dexdomitor for this study.

ULTRASONOGRAPHIC EXAMINATION OF THE ABDOMEN

Urinary System

The urinary bladder wall is normal in thickness and the mucosal surface is smooth. The bladder is mildly to moderately distended. Luminal contents are anechoic. No cystic calculi are observed. The region of the trigone and the proximal urethra, visible to a depth of 2 cm, are normal. The region of the trigone is normal.

The prostate is not definitively visualized due to its pelvic location.

The left kidney is normal in size (9.03 cm in length) with a normal shape, architecture and smooth peripheral margins. There is a normal 1:3 cortex to medulla ratio with normal corticomedullary distinction. There is no evidence of pyelectasia, nephroliths, infarcts or hydronephrosis.

The right kidney is normal in size (9.25 cm in length) with a normal shape, architecture and smooth peripheral margins. There is a normal 1:3 cortex to medulla ratio with normal corticomedullary distinction. There is no evidence of pyelectasia, nephroliths, infarcts or hydronephrosis.

Adrenal Glands

The left adrenal gland is normal in size (0.46 cm at cranial pole) (0.49 cm at caudal pole) with a normal shape and homogenous parenchyma. The glandular echogenicity and detail are unremarkable. Capsule, cortex, and medullary definition are normal. The phrenicoabdominal vein and surrounding vasculature are normal.

The right adrenal gland is normal in size (0.55 cm at cranial pole) (0.73 cm at caudal pole) with a normal shape and homogenous parenchyma. The glandular echogenicity and detail are unremarkable. Capsule, cortex, and medullary definition are normal. The phrenicoabdominal vein and surrounding vasculature are normal.

Spleen

The spleen is prominent in size (2.11 cm in width at the level of the hilus) with smooth peripheral margins and a folded contour. The parenchyma is subtly mottled in appearance. No focal lesions are observed. Splenic vasculature is normal.

Liver

The liver is subjectively normal in size with normal contours and structure. There is appropriate echogenicity and echotexture. No overt structural evidence of inflammatory, infiltrative, or regenerative pathology is evident. Vascular and biliary tracts are of normal volume with no evidence of congestion.



PATIENT

Russell Foley

SPECIES

Canine

BREED

Great Dane

SEX

Male, neutered

AGE

3 Yrs. 8 months

WEIGHT

57.7 kg.

INTERPRETED BY

Andrea Nicastro, DVM,
Diplomate ACVIM
(Small Animal Internal
Medicine)

IMAGING PERFORMED BY

Dr. Chmielinski

HOSPITAL NAME

Apex VS

REFERRING VET

Dr. Bregliano

INVOICE

13374

DATE

1/5/26

The gall bladder lumen is moderately distended. The wall is thin and smooth. A small to moderate amount of gravity-dependent echogenic debris is observed within the lumen. The cystic and common bile ducts are normal/not seen.

Gastrointestinal

The gastric lumen is moderately fluid distended and hypomotile. The gastric wall is normal to moderately thickened (up to 1.21 cm) with apparent retention of the normal layering pattern. The pyloric outflow tract is patent. The small intestinal lumen is segmentally dilated with fluid and gas. The small intestinal wall is normal in thickness with a normal layering pattern and appropriate mural detail. Discreet masses are not identified. The ileocecolic junction and colonic wall are normal. There is no obvious evidence of an obstructive pattern.

Pancreas

A portion of the pancreas is obscured by the gastric distention. In the visualized portion, no obvious abnormalities are seen.

Lymph nodes

A few prominent jejunal lymph nodes are visualized, one of the nodes measuring 1.25 x 0.40 cm.

Free Abdomen

There is no obvious evidence of free fluid.

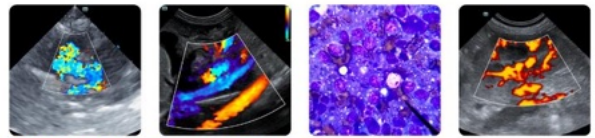
ULTRASONOGRAPHIC FINDINGS

- Gastric ileus. A functional ileus is suspected as there is no obvious evidence of a mechanical pyloric outflow tract obstruction. The gastric wall changes are most consistent with gastritis with a lower possibility of hyperplasia or emerging neoplasia.
- The splenic changes could be secondary to sedation, lymphoid hyperplasia, extramedullary hematopoiesis, splenitis, antigenic stimulation or less likely, emerging round cell neoplasia.
- The prominent abdominal lymph nodes are most consistent with reactive lymphadenitis or lymphoid hyperplasia. Neoplastic infiltration is considered less likely.

*A specific cause for the patient's vomiting is not definitively identified in this study. Considerations include a microscopic enteropathy (i.e., primary motility disorder, food allergy/intolerance, inflammatory bowel disease, infectious/parasitic disease), underlying metabolic issue, other.

INTERPRETATION OF THE FINDINGS & FURTHER RECOMMENDATIONS

1. A minimum database including a CBC chemistry panel, urinalysis and T4 is recommended (if not already performed).
2. A fecal evaluation for ova and Giardia should also be performed.
3. Consider a GI panel including serum cobalamin, folate, TLI, PLI and resting cortisol level.
4. Depending on results from the above diagnostics, an upper GI endoscopy with biopsies or an abdominal exploratory with surgical biopsies may be indicated.



PATIENT

Russell Foley

SPECIES

Canine

BREED

Great Dane

SEX

Male, neutered

AGE

3 Yrs. 8 months

WEIGHT

57.7 kg.

INTERPRETED BY

Andrea Nicastro, DVM,
Diplomate ACVIM
(*Small Animal Internal
Medicine*)

IMAGING PERFORMED BY

Dr. Chmielinski

HOSPITAL NAME

Apex VS

REFERRING VET

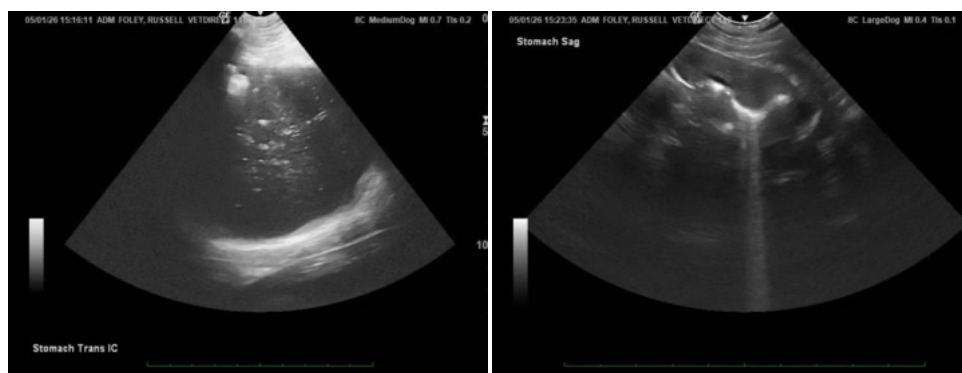
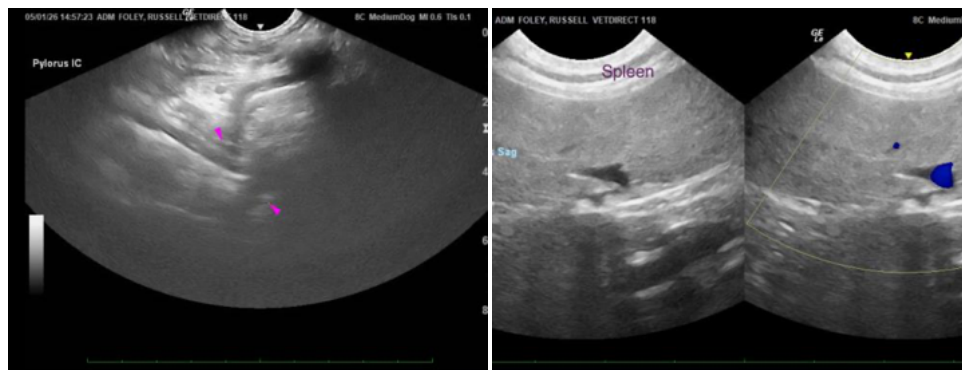
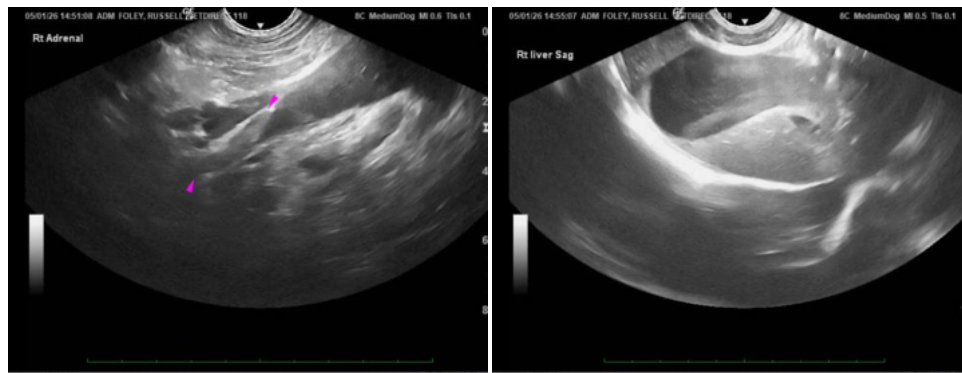
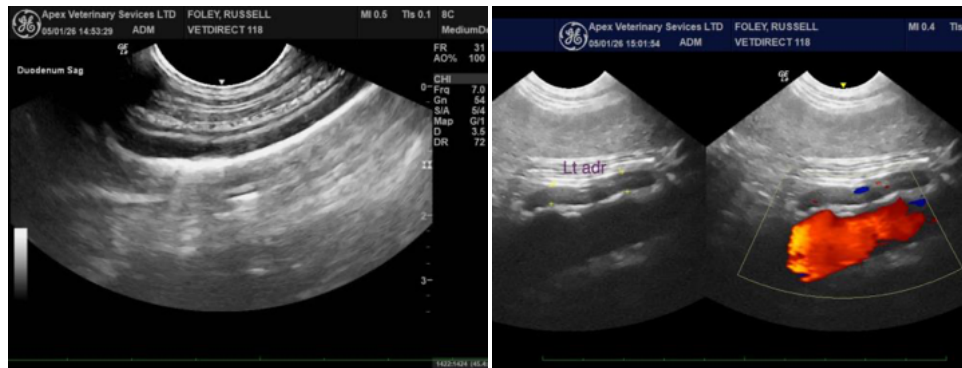
Dr. Bregliano

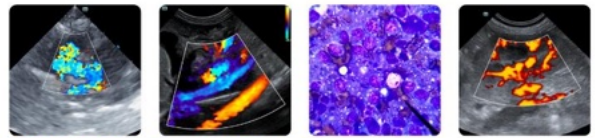
INVOICE

13374

DATE

1/5/26





PATIENT

Russell Foley

SPECIES

Canine

BREED

Great Dane

SEX

Male, neutered

AGE

3 Yrs. 8 months

WEIGHT

57.7 kg.

INTERPRETED BY

Andrea Nicastro, DVM,
Diplomate ACVIM
(*Small Animal Internal
Medicine*)

IMAGING PERFORMED BY

Dr. Chmielinski

HOSPITAL NAME

Apex VS

REFERRING VET

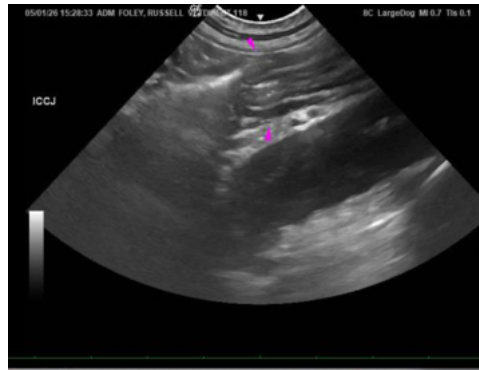
Dr. Bregliano

INVOICE

13374

DATE

1/5/26



The information and recommendations provided are based on the images presented by the referring veterinarian/sonographer. No evaluation can be communicated regarding pathology that was not visible in the image/video clips provided.

Thank you for this referral. If the clinical or image interpretation does not parallel your findings or if I can be of any further assistance please contact me.

Andrea Nicastro, MPH, DVM, Diplomate DACVIM (Small Animal Internal Medicine)
info@SonoPath.com