

**DATE**

1/5/22

PRESENTING CLINICAL SIGNS**PATIENT**

Frack Fidler

History: Weight loss, chronic vomiting, new heart murmur, hx of elevated ALT, hx of hyperthyroidism (controlled w/ hill's y/d diet), CKD, hypertension (controlled w/ Amlodipine). Hx of AUS last year with Intrapet performed at DocSide Animal Hospital. Hepatic parenchymal changes, small intestinal changes suggestive of possible IBD, and prominent LN's (most likely reactive). Bilateral chronic renal changes.

SPECIES

Feline

Current Medications: Amlodipine 0.625 mg SID, Cerenia 8 mg PO EOD.

Lab Results: CBC/Chem/T4 from 11/5/21 - ALT 222, Amyl 1628, BUN 41, creat 3.0, Ca 11.4, T4 1.9, Eos 1326, HCT 31%, USG 1.015, no proteinuria, or signs of infection / inflammation.

Date of Previous IntraPet Ultrasound: 3-11-2021.

BREED

DSH

Sedation: Torbugesic and Midazolam IV.

Stat Report: Not requested.

Imaging Performed By: Stephanie Pearce RDCS, RVT

SEX

Neutered Male

ULTRASONOGRAPHIC EXAMINATION OF THE ABDOMEN**AGE**

3/1/05

Urinary System

The urinary bladder, trigone, and pelvic urethra are normal in thickness and the mucosal surface is smooth. The bladder lumen is moderately distended with mostly anechoic urine. No masses, inflammatory changes or calculi are observed. Ureteral papillae and visualized portion of the proximal urethra, visible to a depth of 2 cm, are normal.

WEIGHT

10 Lbs.

The left kidney is small in size (2.82 cm in length); with a relatively normal shape. There is moderate loss of corticomedullary distinction. The cortex is mildly hyperechoic and slightly heterogeneous in appearance. Several hyperechoic shadowing diverticular foci are observed. There is no evidence of pyelectasia, infarcts or hydronephrosis. Renal vasculature is normal.

INTERPRETED BY

Andrea Nicastro, DMV,
Diplomate DACVIM
(Small Animal
Internal Medicine)

The right kidney is normal in size (3.79 cm in length); with a normal shape and smooth peripheral contours. There is moderate loss of corticomedullary distinction. The cortex is mildly hyperechoic in appearance. Several hyperechoic shadowing diverticular foci are observed. There is no evidence of pyelectasia, infarcts or hydronephrosis. Renal vasculature is normal.

HOSPITAL NAME

Stevenson Village VH

Adrenal Glands

The left adrenal gland is mildly enlarged (0.56 cm width) with a normal shape and glandular echogenicity. The phrenicoabdominal vein and surrounding vasculature are normal.

REFERRING VET

Dr. Vinson

The right adrenal gland is mildly enlarged (0.67 cm width) with a normal shape and glandular echogenicity. The phrenicoabdominal vein and surrounding vasculature are normal.

INVOICE

13126

Spleen

The spleen is subjectively prominent in size (1.12 cm in width at the level of the hilus) with slightly swollen peripheral contours. There is appropriate echogenicity and echotexture. No focal lesions are observed. Splenic vasculature is normal.

Liver

The liver is subjectively prominent in size with slightly swollen peripheral contours. The parenchyma is hyperechoic relative to the spleen and diffusely mottled and slightly heterogeneous in appearance. Several

ill-defined hypoechoic nodules are observed throughout the organ, particularly on the left side. Hepatic vasculature and intrahepatic biliary tracts are of normal volume with no evidence of congestion.

The gall bladder lumen is moderately distended. The wall is thin and smooth. A small amount of gravity dependent echogenic debris is observed within the lumen. The cystic and common bile ducts are normal.

Gastrointestinal

The gastric lumen is mildly distended with ingesta. A shadowing structure is observed within the lumen near the pylorus. The gastric wall and pylorus are normal in thickness with a normal layering pattern. The pyloric outflow tract appears patent. The small intestinal lumen is not dilated. The small intestinal wall is normal to mildly thickened (up to 0.27 cm) with a normal layering pattern and appropriate mural detail. There is slight disruption in the normal 1:3 muscularis to mucosal ratio in most segments. Discreet masses are not identified. The muscularis layer at the ileocecolic junction is prominent. The colonic wall is normal. There is no evidence of an obstructive pattern.

Pancreas

The pancreas is normal in size with normal peripheral contours. The pancreatic duct is normal. The base and limbs of the pancreas are isoechoic to surrounding omental fat. No focal lesions are observed. There is no evidence of peripancreatic inflammation or effusion.

Free Abdomen

There is no evidence of free fluid. Several prominent lymph nodes are observed adjacent to the ileocecolic junction, the largest measuring 0.84 cm in length.

ULTRASONOGRAPHIC FINDINGS

Primary Findings

- The hepatic parenchymal changes are nonspecific and could be secondary to inflammatory/immune mediated disease, infiltrative neoplasia (less likely), hepatic lipodosis, other hepatopathy. Changes are similar to the previous sonogram.
- The small intestinal wall changes are most consistent with inflammatory bowel disease with potential for emerging lymphoma. The shadowing structure within the gastric lumen may represent kibble and/or foreign material (i.e., hairball).

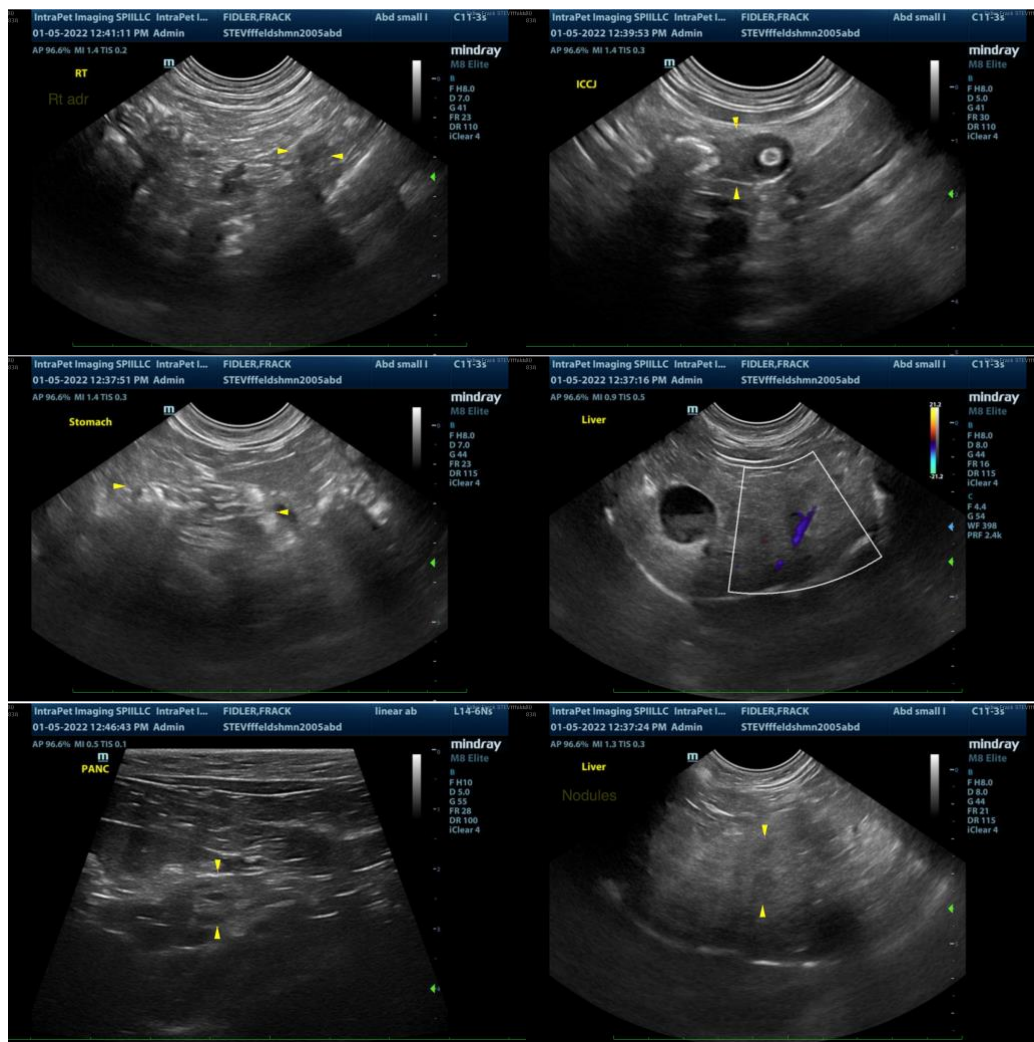
Secondary Findings

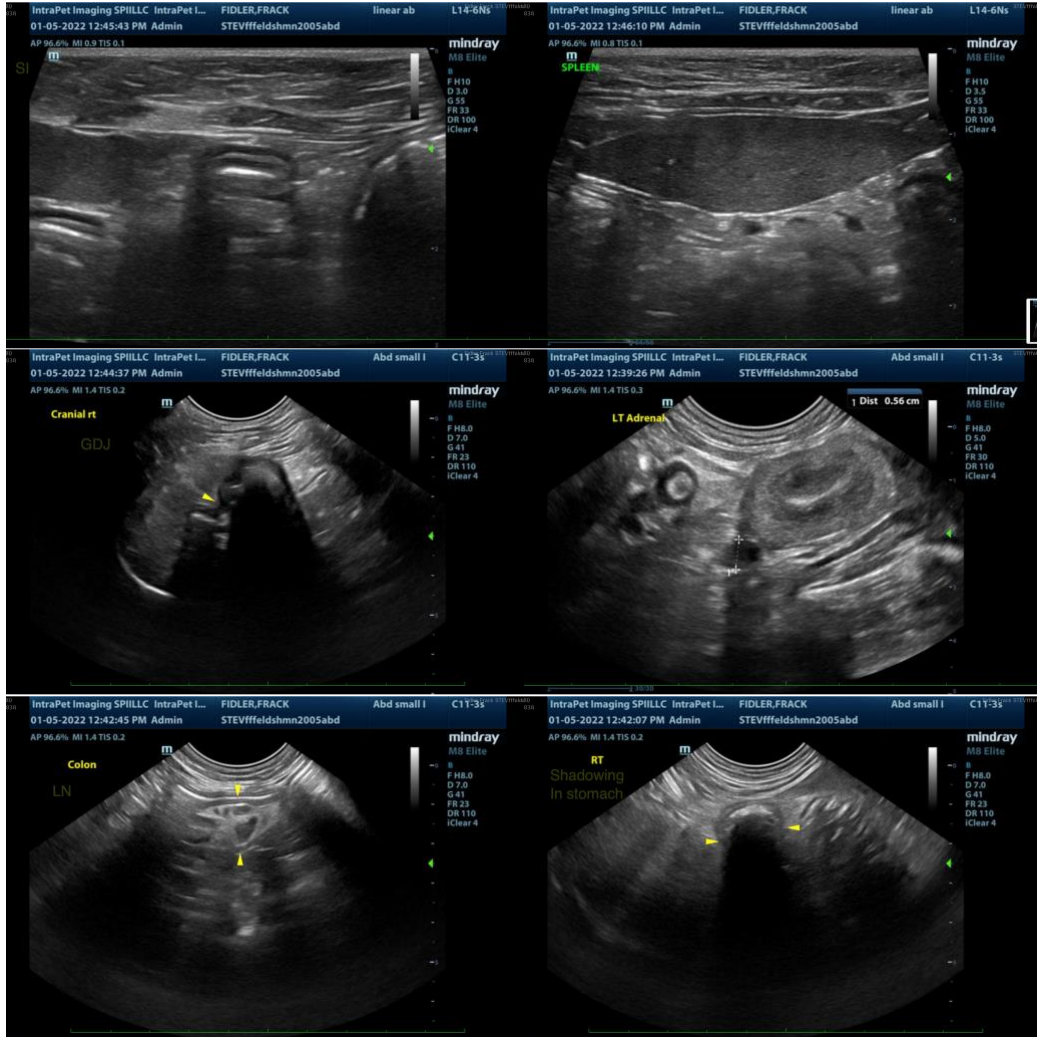
- Bilateral age-related renal changes with dystrophic mineralization.
- The bilateral adrenomegaly may be a normal variant for this patient or may be secondary to stress or hyperplastic change.
- The diffuse splenic changes are non-specific and could be consistent with lymphoid hyperplasia, extramedullary hematopoiesis, or less likely, infiltrative neoplasia.
- The prominent abdominal lymph nodes are most consistent with reactive lymphadenitis or lymphoid hyperplasia. Neoplastic infiltration is considered less likely.

*Overall, the abdominal changes are similar to the previous sonogram.

INTERPRETATION OF THE FINDINGS & FURTHER RECOMMENDATIONS

- Given the weight loss, three-view thoracic radiographs are recommended to assess for neoplasia in the chest.
- Other diagnostic considerations include the following:
 1. Malabsorption panel, including serum cobalamin, folate, TLI and PLI
 2. Fecal evaluation for ova and Giardia
 3. Fine needle aspirate of the liver, if clotting status is appropriate.
 4. Depending upon the results of the above diagnostics, endoscopic or surgical gastrointestinal biopsies +/- liver biopsies may be necessary to get a definitive diagnosis.





The information and recommendations provided are based on the images presented by the referring veterinarian. No evaluation can be communicated regarding pathology that was not visible in the image/video clips provided.

Thank you for this referral. If the clinical or image interpretation does not parallel your findings or if I can be of any further assistance please contact me.

Andrea Nicastro, DVM, Diplomate DACVIM (Small Animal Internal Medicine)
info@SonoPath.com