



PATIENT

Princess Vella

SPECIES

Canine

BREED

Miniature Pinscher

SEX

Female Spayed

AGE

07/29/2017

WEIGHT

21.2lb

INTERPRETED BY

Andrea Nicastrò DVM
Diplomate ACVIM
(Sm Animal Internal Med)

**IMAGING
PERFORMED BY**

Andrea Nicastrò DVM
Diplomate ACVIM
(Sm Animal Internal Med)

HOSPITAL NAME

VCA Westbury AH

REFERRING VET

Dr Heather Caughey

INVOICE

22374

DATE

1-5-2026

PRESENTING CLINICAL SIGNS

Clinical Exam Findings: Inappropriate urination for two weeks, PUPD, previously elevated liver values, recent labs done 12/15: DVM notes on labwork to owner: significant elevation in liver values compared to October - more than endocrine related and given this rise and potential for infection being present ideally we would get an abdominal ultrasound vs treating with Clavamox/metro; if considering LDDST now while we suspect infection to be present there is a high potential for false positive -- Treated with Clavamox for 14 days - no improvement in urinary issue.

Abnormal lab-work values: ALT(SGPT) 472. Alk Phos 1500. GGTP 22. Creatinine 0.2. BUN/Creat Ratio 75. Cholesterol 418. Triglycerides 551. Platelet Count 449., WBC 4-10. Thrombocytosis. T4 1.5. USG 1.021 with 1+proteinuria. 4dx negative.

Current Medications: N/A

ULTRASONOGRAPHIC EXAMINATION OF THE ABDOMEN

Urinary System

The urinary bladder is moderately distended. The wall in the region of the apex/dorsal apical wall is thickened (up to 1.08 cm) and irregular. A 1.55 x 1.08 cm nodule is observed at the dorsal apical aspect. A small-to-moderate amount of echogenic debris is observed within the lumen. No cystic calculi are observed. The region of the trigone and the proximal urethra, visible to a depth of 3 cm, are normal.

The left kidney is normal in size (4.87 cm in length) with a normal shape, architecture and smooth peripheral margins. There is a normal 1:3 cortex to medulla ratio with minimal to mild loss of corticomedullary distinction. There is no evidence of pyelectasia, nephroliths, infarcts or hydronephrosis. Renal vasculature is normal.

The right kidney is normal in size (4.84 cm in length) with a normal shape, architecture and smooth peripheral margins. There is a normal 1:3 cortex to medulla ratio with minimal to mild loss of corticomedullary distinction. There is no evidence of pyelectasia, nephroliths, infarcts or hydronephrosis. Renal vasculature is normal.

Adrenal Glands

The left adrenal gland is normal in size at the cranial pole and enlarged at the caudal pole (0.64 cm at cranial pole) (1.21 cm at caudal pole). A 1.29 x 1.21 cm hyperechoic-to-heterogenous nodule is observed at the caudal pole. Glandular echogenicity and detail at the cranial pole are normal. The phrenicoabdominal vein and surrounding vasculature are normal.

The right adrenal gland is normal in size (0.63 cm at cranial pole) (0.45 cm at caudal pole) with a normal shape and homogenous parenchyma. The glandular echogenicity and detail are unremarkable. Capsule, cortex, and medullary definition are normal. The phrenicoabdominal vein and surrounding vasculature are normal.

Spleen

The spleen is normal in size (1.11 cm in width at the level of the hilus) with a normal capsular contour. There is appropriate echogenicity and echotexture. No focal lesions are observed. Splenic vasculature is normal.

Liver

The liver is subjectively prominent in size with swollen curvilinear peripheral contours. The parenchyma is isoechoic relative to the spleen and exhibits mild heterogeneity. No distinct focal lesions are observed. Hepatic vasculature and biliary tracts are of normal volume with no evidence of congestion. The portal vein to caudal vena cava ratio is approximately 1: 1.



PATIENT

Princess Vella

The gallbladder is moderately distended. The wall is normal in thickness. Several polypoid-like lesions are arising from the mucosal surface. A small amount of gravity-dependent, echogenic debris is observed within the lumen. The cystic and common bile ducts are normal/not seen.

SPECIES

Canine

Gastrointestinal

The gastric lumen is mildly distended with ingesta. The gastric wall and pylorus are normal in thickness with a normal layering pattern. The pyloric outflow tract is patent. The small intestinal lumen is segmentally dilated with chyme (mild). The small intestinal wall is normal in thickness with a normal layering pattern and appropriate mural detail. Discreet masses are not identified. The ileocecolic junction and colonic wall are normal. There is no evidence of an obstructive pattern.

BREED

Miniature Pinscher

SEX

Female Spayed

Pancreas

The right limb of the pancreas is visible with normal curvilinear peripheral contours. The parenchyma is slightly hyperechoic relative to surrounding omental fat and slightly heterogenous in appearance. The pancreatic duct is visible but not overtly dilated. There is no evidence of peripancreatic inflammation or effusion.

AGE

07/29/2017

Lymph Nodes

The abdominal lymph nodes are normal/not visible.

WEIGHT

21.2lb

Free Abdomen

There is no obvious evidence of free fluid.

INTERPRETED BY

Andrea Nicastrò DVM
Diplomate ACVIM
(Sm Animal Internal Med)

Other

A brief echocardiogram reveals no obvious evidence of right atrial or auricular mass. There is no obvious evidence of pericardial effusion.

ULTRASONOGRAPHIC FINDINGS

**IMAGING
PERFORMED BY**

Andrea Nicastrò DVM
Diplomate ACVIM
(Sm Animal Internal Med)

Primary Findings

- The hepatic changes are nonspecific and could be secondary to inflammatory disease (i.e., cholangiohepatitis, chronic hepatitis), Leptospirosis, hepatotoxicosis, infiltrative neoplasia (i.e., lymphoma), vacuolar hepatopathy, regenerative nodular hyperplasia, other hepatopathy, or some combination thereof.
- Gallbladder debris, non-mucocele. Gallbladder polyps are also present. These are typically a benign incidental finding in older canine patients. However, they can be associated with cholecystitis in some case.
- The urinary bladder wall changes are concerning for infiltrative neoplasia (i.e., transitional cell carcinoma). However, cystitis cannot be excluded.
- The left adrenal nodule could be consistent with focal nodular hyperplasia, adenoma, emerging adenocarcinoma, pheochromocytoma, other.

HOSPITAL NAME

VCA Westbury AH

REFERRING VET

Dr Heather Caughey

INVOICE

22374

Secondary Findings

- Mild Bilateral nonspecific age-related renal changes

DATE

1-5-2026



PATIENT

Princess Vella

- The pancreatic changes are most consistent with age-related parenchymal remodeling, potentially secondary to a prior inflammatory episode, early fibrosis or chronic pancreatitis.

SPECIES

Canine

- Regarding the hepatic changes, consider the following;

BREED

Miniature Pinscher

- Pre- and postprandial serum bile acids
- Leptospirosis testing (i.e., blood and urine PCR, serology), particularly if clinical suspicion for disease is high.
- Ultimately, hepatic tissue sampling (i.e., aspirates or biopsies) may be necessary to get a definitive diagnosis. If biopsies are pursued, aerobic and anaerobic bile cultures are recommended, along with hepatic copper quantitation.
- If a conservative approach is desired, consider empirical treatment for bacterial cholangiohepatitis/ Leptospirosis (amoxicillin-clavulanic acid, Denamarin). If no improvement in the liver values is seen within 7-10 days of initiating therapy, antibiotics should be discontinued, and hepatic tissue sampling reconsidered. If liver values improve, continue therapy for at least 4-6 weeks and 1 week beyond normalization of the liver values.

SEX

Female Spayed

AGE

07/29/2017

- Regarding the left adrenal nodule, consider the following:

WEIGHT

21.2lb

- Baseline blood pressure measurement
- Three-view thoracic radiographs are recommended to assess for pulmonary metastases
- Further testing for a functional tumor (i.e., low-dose dexamethasone suppression test, urine/blood metanephrine levels)

INTERPRETED BY

Andrea Nicastro DVM
 Diplomate ACVIM
 (Sm Animal Internal Med)

- Regarding the urinary bladder wall change, a urine BRAF test is recommended to further evaluate for lower urinary tract neoplasia. A positive test confirms neoplasia. However, a negative test does not rule out the possibility of cancer, and further diagnostics (i.e., bladder wall biopsy) may be necessary to get a definitive diagnosis.

IMAGING PERFORMED BY

Andrea Nicastro DVM
 Diplomate ACVIM
 (Sm Animal Internal Med)

HOSPITAL NAME

VCA Westbury AH

REFERRING VET

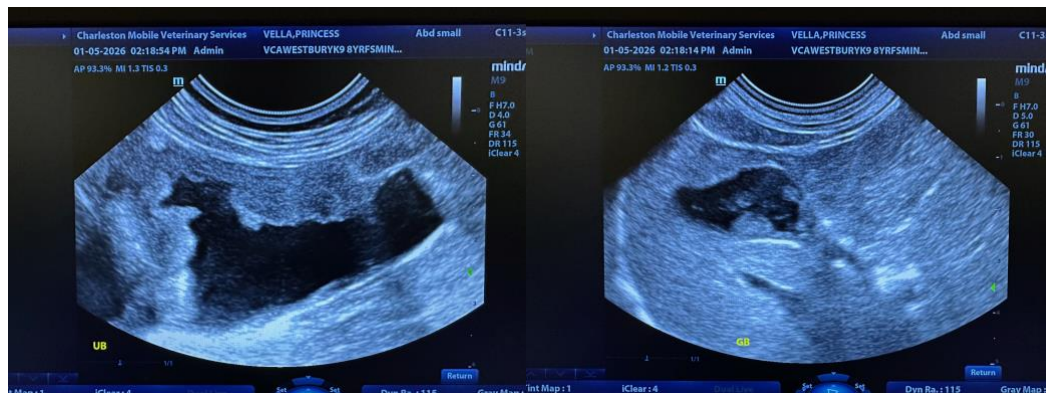
Dr Heather Caughey

INVOICE

22374

DATE

1-5-2026





PATIENT

Princess Vella

SPECIES

Canine

BREED

Miniature Pinscher

SEX

Female Spayed

AGE

07/29/2017

WEIGHT

21.2lb

INTERPRETED BY

Andrea Nicastrò DVM
 Diplomate ACVIM
 (Sm Animal Internal Med)

IMAGING PERFORMED BY

Andrea Nicastrò DVM
 Diplomate ACVIM
 (Sm Animal Internal Med)

HOSPITAL NAME

VCA Westbury AH

REFERRING VET

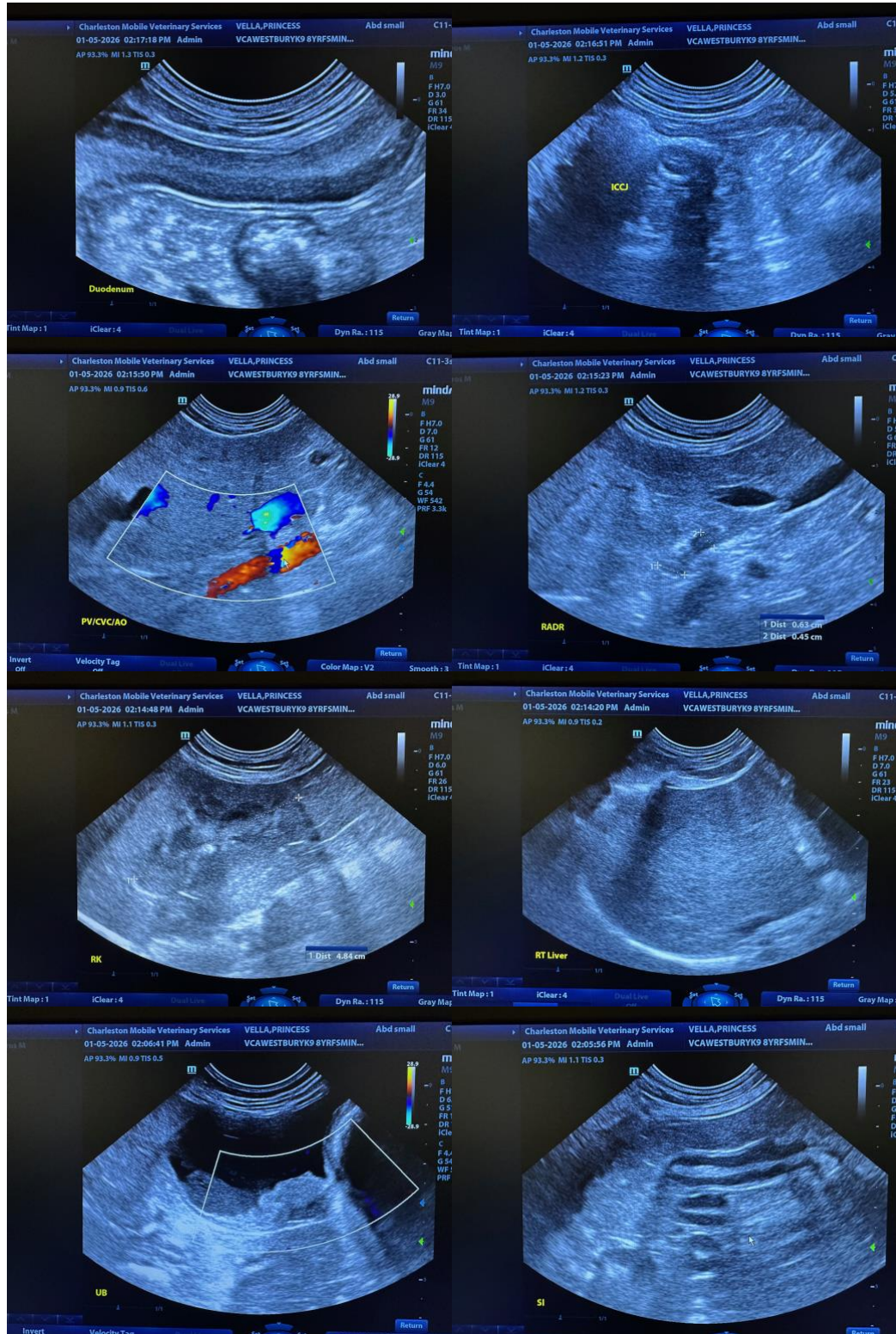
Dr Heather Caughey

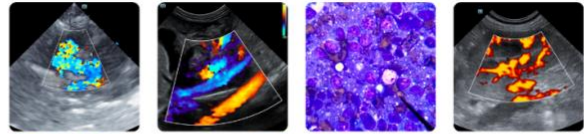
INVOICE

22374

DATE

1-5-2026





PATIENT

Princess Vella

SPECIES

Canine

BREED

Miniature Pinscher

SEX

Female Spayed

AGE

07/29/2017

WEIGHT

21.2lb

INTERPRETED BY

Andrea Nicastro DVM
 Diplomate ACVIM
 (Sm Animal Internal Med)

IMAGING PERFORMED BY

Andrea Nicastro DVM
 Diplomate ACVIM
 (Sm Animal Internal Med)

HOSPITAL NAME

VCA Westbury AH

REFERRING VET

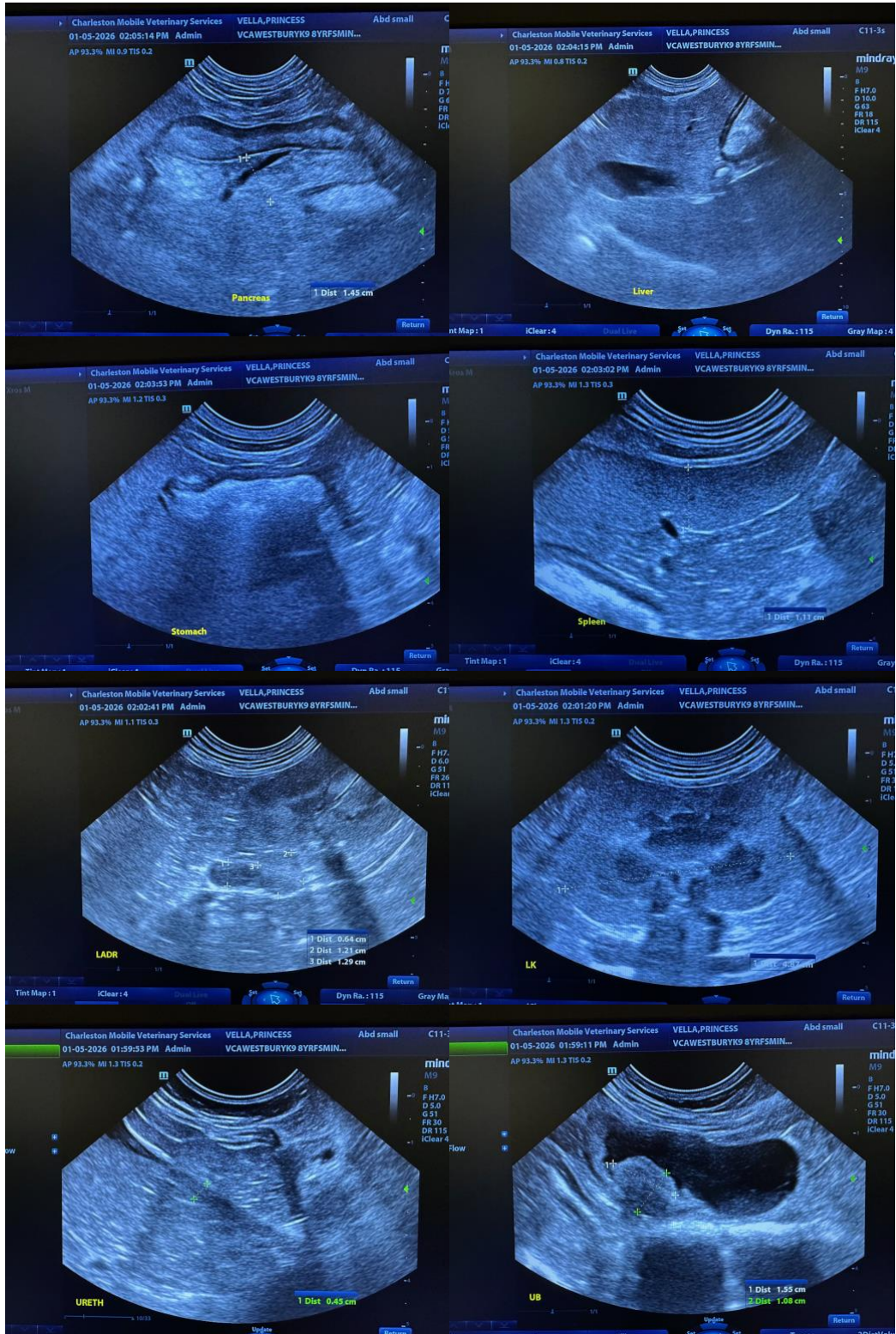
Dr Heather Caughey

INVOICE

22374

DATE

1-5-2026





PATIENT

Princess Vella

The information and recommendations provided are based on the images presented by the referring veterinarian/sonographer. No evaluation can be communicated regarding pathology that was not visible in the image/video clips provided.

SPECIES

Canine

Thank you for this referral. If the clinical or image interpretation does not parallel your findings or if I can be of any further assistance, please contact me.

BREED

Miniature Pinscher

Andrea Nicastro, MPH, DVM, Diplomate DACVIM (Small Animal Internal Medicine)
info@SonoPath.com

SEX

Female Spayed

AGE

07/29/2017

WEIGHT

21.2lb

INTERPRETED BY

Andrea Nicastro DVM
Diplomate ACVIM
(Sm Animal Internal Med)

**IMAGING
PERFORMED BY**

Andrea Nicastro DVM
Diplomate ACVIM
(Sm Animal Internal Med)

HOSPITAL NAME

VCA Westbury AH

REFERRING VET

Dr Heather Caughey

INVOICE

22374

DATE

1-5-2026