

**DATE PRESENTING CLINICAL SIGNS**

1/4/2022

History: Presenting Complaint: Not Eating; Lethargic. Date: 01-01-2022 Notes: Niko is a 7 y/o MN mixed breed dog who presents for not eating well and acting lethargic - 2 weeks ago treated for gastroenteritis - yesterday vomited yellow bile - was not interested in eating breakfast this morning, appeared more hunched - 3 pm ate a small meal of a bland diet - had a normal BM, normal urination - not as enthusiastic about food, laying around more - no history of foreign body, or toxin ingestion, will occasionally get into cat food. Assessment: decreased eating, vomiting - chronic pancreatitis vs pancreatitis vs IBD vs metabolic disease vs other. Plan: Recommended bloodwork, AXR, and outpatient management pending diagnostics. Discussed AXR may be low yield, just because we do not see a FB does not mean we do not have one. Ultimately if continues to have GI signs would recommend following up with AUS to further work up underlying disease.

**PATIENT**

Niko Klusewitz

**SPECIES**

Canine

**BREED**

Australian shepherd mix

**SEX**

Male, neutered

**AGE**

6/14/2014

**WEIGHT**

62.6 lbs.

**INTERPRETED BY**

Andrea Nicastro, DVM,  
 Diplomate ACVIM  
 (Small Animal Internal  
 Medicine)

**HOSPITAL NAME**

Animal Emergency Hospital

**REFERRING VET**

Dr. Thompson

**INVOICE**

12785

Current Medications: - Simparica Trio; probiotics at home. In-hospital: Gabapentin, Buprenex, Omeprazole, Provable, Ondansetron.

Lab Results: PCV normal, mini chemistry WNL

Radiographs: Xray Abdomen 2 View-No overt FB or obstruction, mildly gas filled stomach, SI fairly uniform in appearance.

Date of Previous IntraPet Ultrasound: No previous IntraPet scans.

Sedation: Not required to complete full diagnostic ultrasound.

Stat Report: Not requested.

Imaging Performed By: Rachel Brillhart, RDMS.

**ULTRASONOGRAPHIC EXAMINATION OF THE ABDOMEN****Urinary System**

The urinary bladder and visible portion of the pelvic urethra are normal for the degree of luminal distension. The urine is anechoic with no evidence of debris. Cystic calculi and discrete masses are not observed. The region of the trigone and the visible portion of the proximal urethra are normal.

The prostate is normal in size (0.74 cm in width) and shape. Parenchyma is homogenous. The prostatic urethra appears normal without evidence of dilation or obstruction.

The left kidney is normal size (6.52 cm in length); normal shape and architecture with smooth peripheral margins. There is a normal 1:3 cortex to medulla ratio with minimal loss of corticomedullary distinction. There is no evidence of pyelectasia, nephroliths, infarcts or hydroureter. Renal vasculature is normal.

The right kidney is normal size (5.62 cm in length); normal shape and architecture with smooth peripheral margins. There is a normal 1:3 cortex to medulla ratio with minimal to mild loss of corticomedullary distinction. There is no evidence of pyelectasia, nephroliths, infarcts or hydroureter. Renal vasculature is normal.

**Adrenal Glands**

The left adrenal gland is normal size (0.60 cm at cranial pole) (0.57 cm at caudal pole) (2.52 cm in length); normal shape; homogenous parenchyma. The glandular echogenicity and detail are unremarkable. Capsule, cortex, and medullary definition are normal. The phrenicoabdominal vein and surrounding vasculature are normal.

The right adrenal gland is normal size (0.72 cm at cranial pole) (0.74 cm at caudal pole) (1.96 cm in length); normal shape; homogenous parenchyma. The glandular echogenicity and detail are unremarkable. Capsule, cortex, and medullary definition are normal. The phrenicoabdominal vein and surrounding vasculature are normal.

### ***Spleen***

The spleen is normal in size (1.80 cm in width at the level of the hilus) with a normal capsular contour. The parenchyma is subtly mottled in appearance. A 1.66 x 1.51 cm hypoechoic to slightly heterogeneous nodule is observed at the lateral aspect. The lesion causes minimal capsular expansion. Splenic vasculature is normal.

### ***Liver***

The liver is subjectively normal in size with normal contours and structure. There is appropriate echogenicity and echotexture. No overt structural evidence of inflammatory, infiltrative or regenerative pathology is evident. Vascular and biliary tracts are of normal volume with no evidence of congestion. No pathological hepatic lymphadenopathy observed. The gall bladder lumen is moderately distended. The wall is thin and smooth. Luminal contents are anechoic. The cystic and common bile ducts are normal/not seen.

### ***Gastrointestinal***

The gastric lumen is not distended. The gastric wall in the region of the fundus is mildly thickened (up to 0.85 cm) with retention of the normal layering pattern. The pyloric outflow tract is patent. The small intestinal lumen is segmentally dilated with gas and chyme. The small intestinal wall thickness is normal with a normal layering pattern and appropriate mural detail. Discreet masses are not identified. The ileocecal colic junction and colonic wall are normal. No obstructive disease is noted.

### ***Pancreas***

The right limb of the pancreas is visible with normal curvilinear peripheral contours. The parenchyma is largely isoechoic relative to surrounding omental fat and slightly mottled in appearance. The pancreatic duct is visible but not overtly dilated. There is no evidence of peripancreatic inflammation or effusion.

### ***Free Abdomen***

The peritoneal cavity is normal. There is no evidence of inflammation or effusion. The abdominal lymph nodes are normal/not visible.

### ***Other***

A brief echocardiogram reveals no obvious evidence of pericardial effusion.

## **ULTRASONOGRAPHIC FINDINGS**

### **Primary Findings:**

- The splenic nodule could be consistent with emerging neoplasia (i.e., round cell tumor, sarcoma). Alternatively, benign pathology (i.e., lymphoid hyperplasia or extramedullary hematopoiesis) may be present. Differentials are similar for the diffuse splenic changes.
- The mild gastric wall thickening may be secondary to inflammation or less likely, emerging neoplasia.

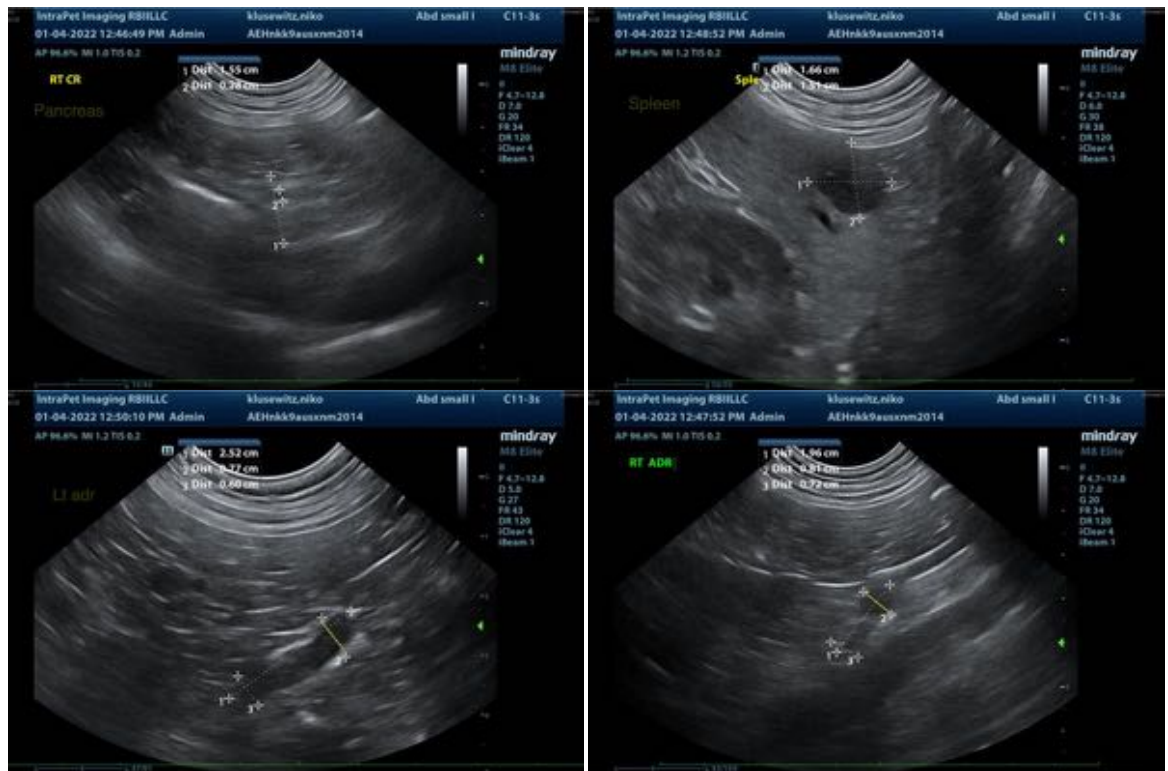
### **Secondary Findings:**

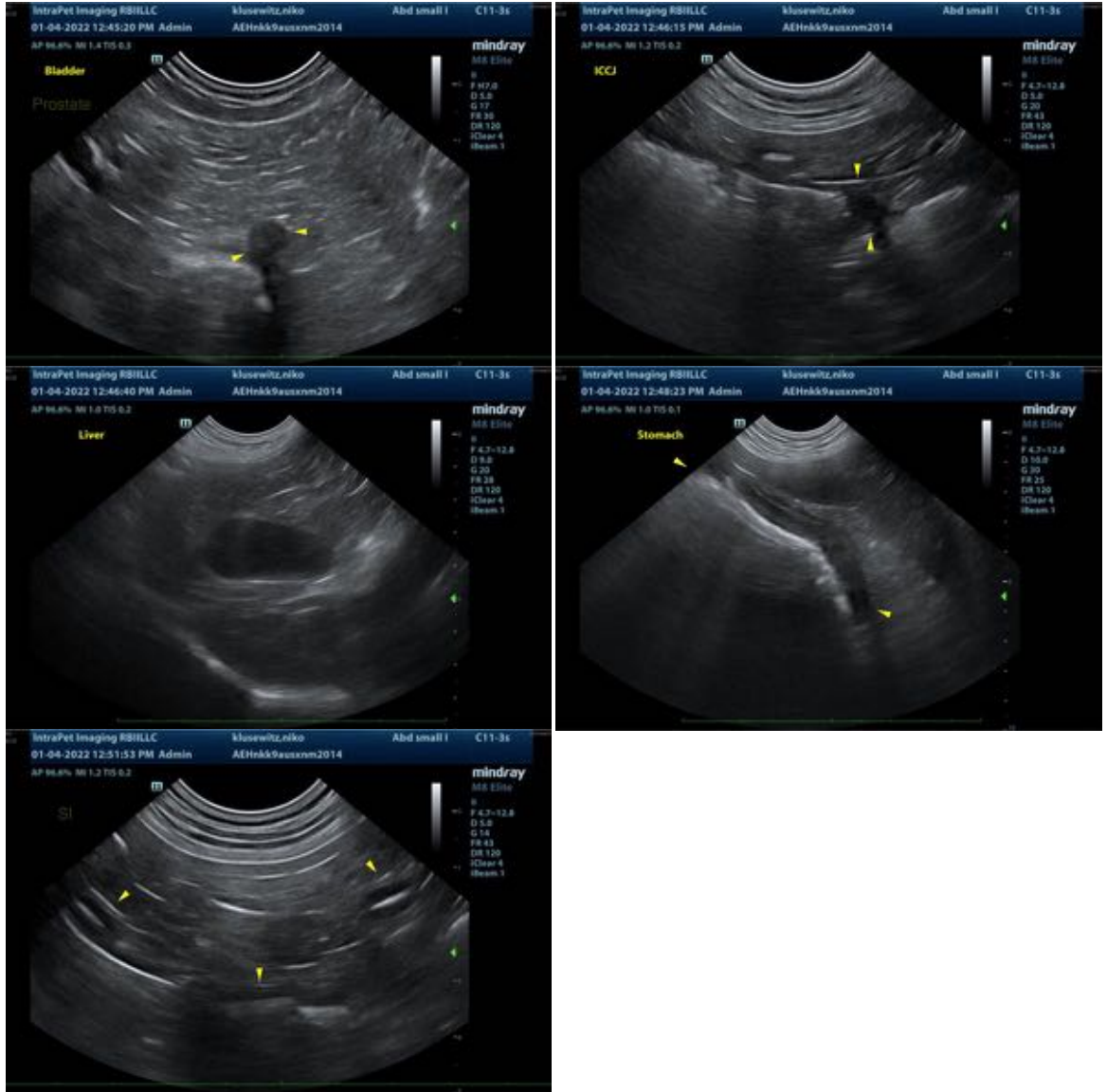
- Minor age-related pancreatic remodeling.
- Minor age-related renal changes.

\*An obvious cause for the patient's clinical signs is not identified in this study. Considerations include microscopic gastrointestinal disease (i.e., acute gastroenteritis, inflammatory bowel disease, infectious/parasitic, intestinal dysbiosis), low-grade pancreatitis, underlying metabolic issue, other.

## INTERPRETATION OF THE FINDINGS & FURTHER RECOMMENDATIONS

- Regarding the splenic nodule, consider the following:
  1. Three-view thoracic radiographs to assess for pulmonary metastatic disease.
  2. Fine needle aspirate of the nodule, if clotting status is appropriate.
- Regarding the GI signs, consider the following:
  1. A fecal evaluation for ova/Giardia.
  2. GI panel (sent to Texas A&M).
  3. A resting cortisol level to screen for hypoadrenocorticism. If resting cortisol level is  $< 2.0$  mcg/dL, an ACTH stimulation test is recommended
  4. Supportive care for acute gastroenteritis.
  5. If the patient's clinical signs do not improve with medical therapy over the next 24-72 hours, a more advanced GI workup may be warranted.





The information and recommendations provided are based on the images presented by the referring veterinarian. No evaluation can be communicated regarding pathology that was not visible in the image/video clips provided.

Thank you for this referral. If the clinical or image interpretation does not parallel your findings or if I can be of any further assistance please contact me.

Andrea Nicastro, DVM, Diplomate ACVIM (*Small Animal Internal Medicine*)  
 Andrea.nicastro@sonopath.com