

**DATE PRESENTING CLINICAL SIGNS**

1/4/2022

History: Acutely lethargic with decreased appetite last 3 days. Historically healthy, last visit in 2015.

PATIENT

Molly Mochtak

Current Medications: 100mL LRS SQ given on 1/3/22. Cerenia injection given sq 1/3/22.

Lab Results: CBC shows slightly low platelet count. Chemistry shows slightly elevated total bilirubin of 0.6. Low T4 and free T4.

Radiographs: Radiographs of abdomen- significant ingesta in stomach, on VD the pyloric antrum appears enlarged.

SPECIES

Feline

Date of Previous IntraPet Ultrasound: No previous IntraPet scans.

Sedation: Gabapentin.

Stat Report: Not requested.

BREED

Imaging Performed By: Andi Parkinson, RDMS.

Domestic shorthair

SEX

Female, spayed

ULTRASONOGRAPHIC EXAMINATION OF THE ABDOMEN**Urinary System**

The urinary bladder, trigone, and pelvic urethra are normal in thickness and the mucosal surface is smooth. The bladder lumen is mildly distended. A small amount of suspended echogenic debris is observed within the lumen. No masses, inflammatory changes or calculi are observed. Ureteral papillae and visualized portion of the proximal urethra, visible to a depth of 2 cm, are normal.

AGE

9/1/2011

The left kidney is normal in size (4.02 cm in length) with a normal shape, smooth peripheral margins and normal internal architecture. There is mild loss of corticomedullary distinction. Several hyperechoic shadowing diverticular foci are observed. There is no evidence of pyelectasia, infarcts or hydronephrosis.

WEIGHT

8.5 lbs.

The right kidney is normal in size (4.61 cm in length) with a normal shape, smooth peripheral margins and normal internal architecture. There is mild loss of corticomedullary distinction. Several hyperechoic shadowing diverticular foci are observed. There is no evidence of pyelectasia, infarcts or hydronephrosis.

INTERPRETED BY

Andrea Nicastro, DVM,
 Diplomate ACVIM
 (Small Animal Internal
 Medicine)

Adrenal Glands

The region of the left adrenal gland is evaluated. No obvious pathology is observed.

HOSPITAL NAME

Timonium AH

The right adrenal gland is normal in size (0.35 cm width) with a normal shape smooth peripheral contours. Hyperechoic foci are observed within the parenchyma. Glandular echogenicity and detail are otherwise normal. Surrounding vasculature appears normal.

Spleen**REFERRING VET**

Dr. Stephens

The spleen is subjectively normal in size (0.76 cm in width at the level of the hilus) with slight scalloping of the medial contour. There is appropriate echogenicity and echotexture. No focal lesions are observed. Splenic vasculature is normal.

INVOICE

12779

Liver

The liver is subjectively normal in size with normal curvilinear peripheral contours. The parenchyma is hypoechoic relative to the spleen and homogeneous in appearance. No distinct focal lesions are observed. Vascular and biliary tracts are of normal volume with no evidence of congestion. The portal vein: caudal vena cava ratio is approximately 1:1. The gall bladder lumen is moderately distended. The wall is slightly

thickened (up to 0.14 cm) and hyperechoic. A small amount of echogenic debris is observed within the lumen. The cystic and common bile ducts are normal/not seen.

Gastrointestinal

The gastric lumen is mildly distended with ingesta. The gastric wall is borderline thickened (up to 0.46 cm) and slightly heterogeneous in the region of the fundus. The pyloric outflow tract is patent. The small intestinal lumen is not dilated. The small intestinal wall thickness is normal with a normal layering pattern and appropriate mural detail. Discreet masses are not identified. The ileocecal colic junction and colonic wall are normal. No obstructive disease is noted.

Pancreas

The pancreas is normal in size with normal peripheral contours. The pancreatic duct is normal. The base and limbs of the pancreas are isoechoic to surrounding omental fat. No focal lesions are observed. There is no evidence of peripancreatic inflammation or effusion.

Free Abdomen

There is no evidence of free fluid. . A cluster of enlarged, hyperechoic rounded lymph nodes are observed in the right cranial quadrant, the largest measuring 1.70 x 0.93 cm. Surrounding mesentery is hyperechoic. A few prominent rounded hypoechoic lymph nodes are also observed adjacent to the ileocecal colic junction, the largest measuring 1.20 x 0.81 cm. Surrounding mesentery is hyperechoic. A few prominent mesenteric lymph nodes are also seen.

ULTRASONOGRAPHIC FINDINGS

Primary Findings:

- The abdominal lymphadenopathy could be consistent with infiltrative neoplasia (i.e., round cell tumor), reactive lymphadenitis, or lymphoid hyperplasia.
- The gastric wall changes are most consistent with an inflammatory process. However, emerging neoplasia cannot be completely excluded.

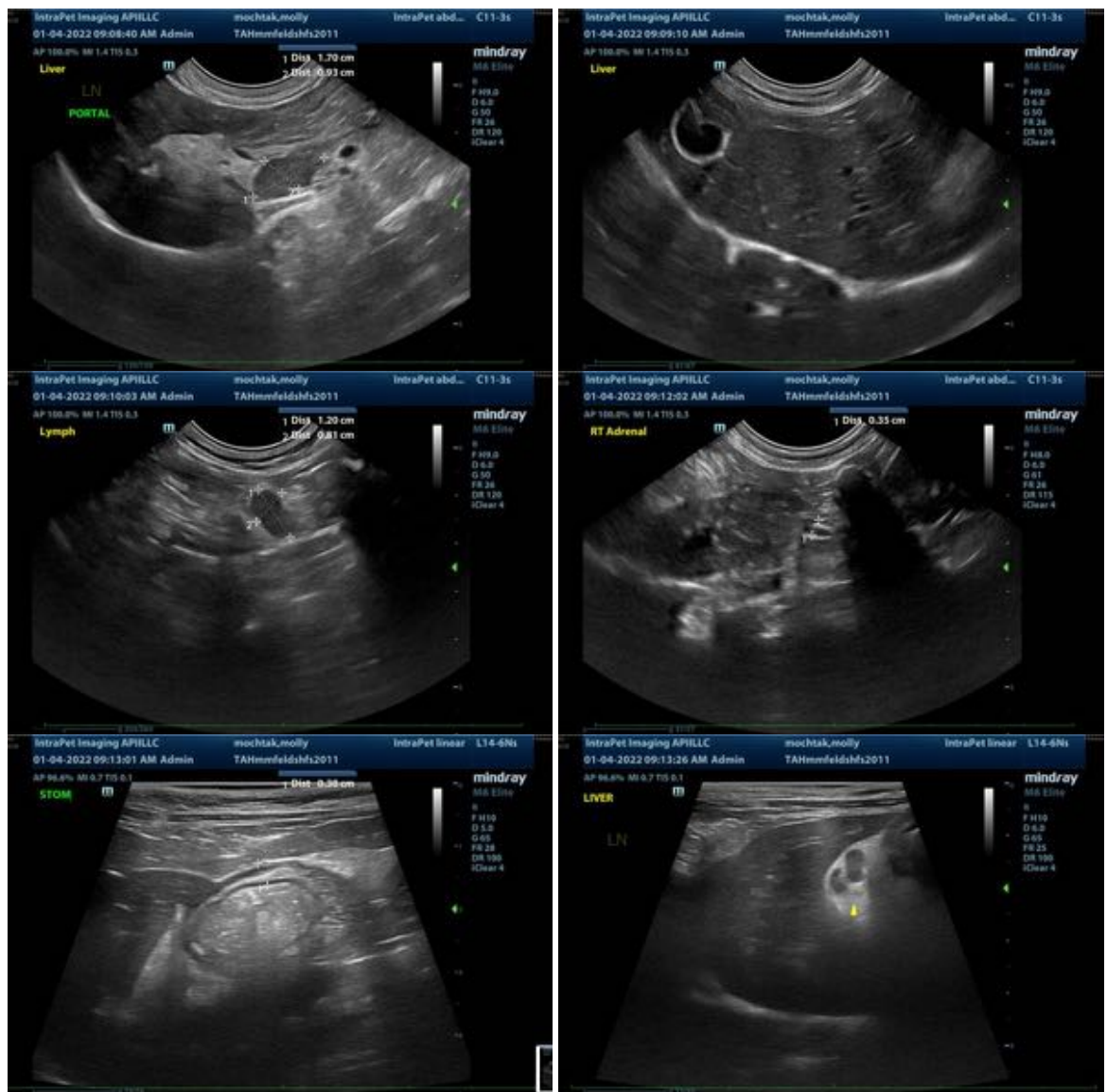Secondary Findings:

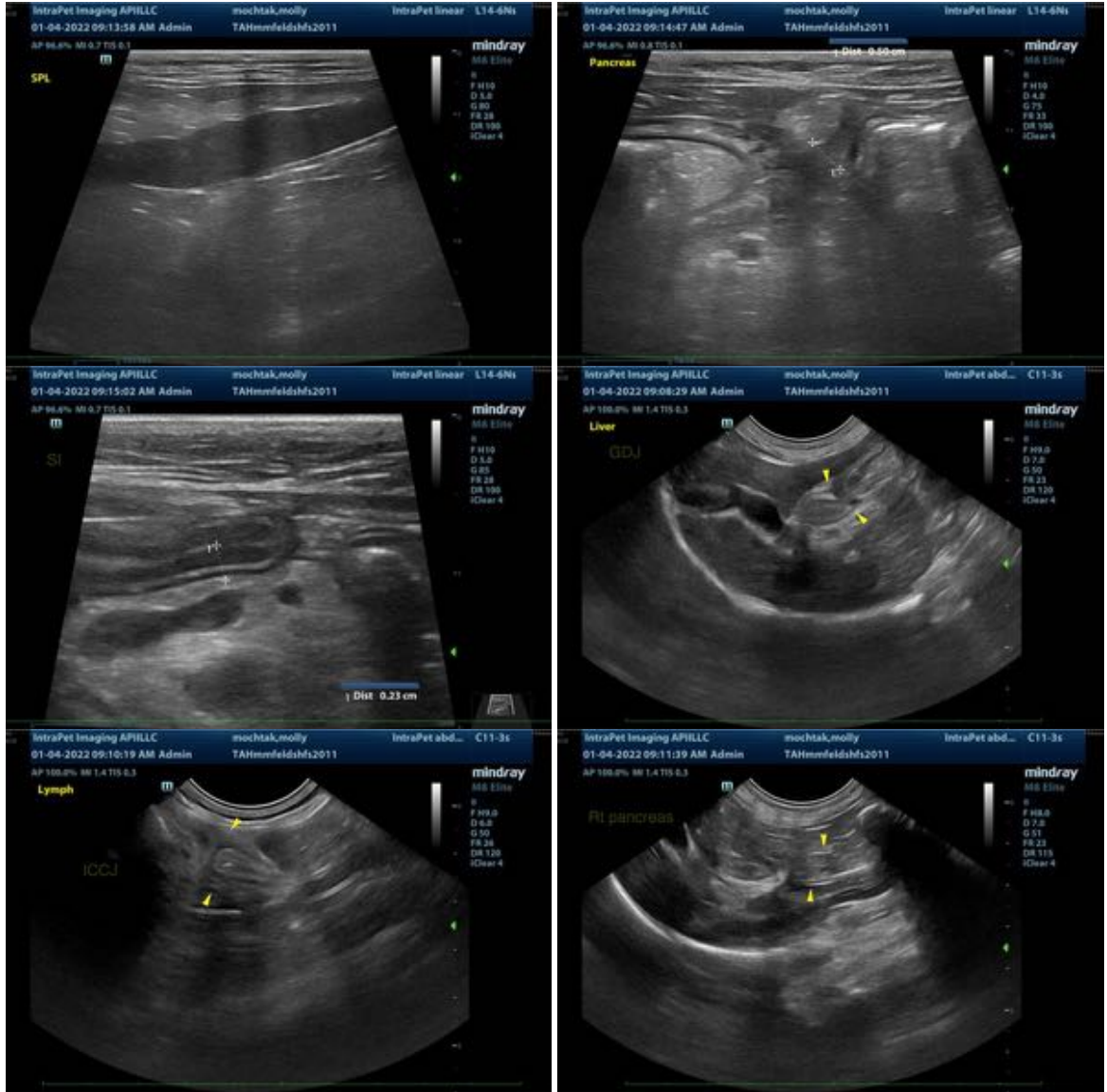
- The hepatic parenchymal changes may be a normal variant for this patient or may be secondary to inflammatory disease, emerging neoplasia (i.e., lymphoma), or other hepatopathy.
- The thickened gallbladder wall may be secondary to cholecystitis and/or benign age-related hyperplasia.
- The hyperechoic right adrenal foci are likely a benign age-related incidental finding.
- Bilateral, age-related renal changes with dystrophic mineralization.

INTERPRETATION OF THE FINDINGS & FURTHER RECOMMENDATIONS

- Three-view thoracic radiographs are recommended to assess for lymphadenopathy in the chest.

- If accessible, fine needle aspirates of the enlarged abdominal lymph nodes in the right cranial quadrant is recommended (if clotting status is appropriate).
- Other diagnostic considerations include a fecal evaluation for ova and Giardia and a GI panel (sent to Texas A&M).
- If the patient does not respond to supportive care and cytology results are inconclusive (or the nodes are inaccessible), an abdominal exploratory with gastrointestinal and abdominal lymph node biopsies may be necessary to get a definitive diagnosis. A liver biopsy should also be obtained at the time of surgery.





The information and recommendations provided are based on the images presented by the referring veterinarian. No evaluation can be communicated regarding pathology that was not visible in the image/video clips provided.

Thank you for this referral. If the clinical or image interpretation does not parallel your findings or if I can be of any further assistance please contact me.

Andrea Nicastro, DVM, Diplomate ACVIM (*Small Animal Internal Medicine*)
 Andrea.nicastro@sonopath.com