



PATIENT

Jager Hagerty

SPECIES

Canine

BREED

Frenchie

SEX

Male, neutered

AGE

11 Yrs.

WEIGHT

31 lbs.

INTERPRETED BY

Andrea Nicastro, DVM,
Diplomate ACVIM
(Small Animal Internal
Medicine)

IMAGING PERFORMED BY

Chaley Hunt, LVT

HOSPITAL NAME

Columbia AC

REFERRING VET

Dr. Michelle Engel

INVOICE

12773

DATE

1/4/22

PRESENTING CLINICAL SIGNS

History: Elevated liver values on screening labwork, higher at 1 month recheck after a course of antibiotics

Abnormal PE/Chem/CBC/UA Results: Oct 1st: ALT = 249, ALKP= 451 Nov 2nd: ALT= 361, ALKP= 530

ULTRASONOGRAPHIC EXAMINATION OF THE ABDOMEN

Urinary System

The urinary bladder, trigone, and pelvic urethra are normal in thickness and the mucosal surface is smooth. The bladder lumen is moderately distended with anechoic urine. No masses, inflammatory changes or calculi are observed. Ureteral papillae and visualized portion of the proximal urethra, visible to a depth of 2 cm, are normal.

The prostate is normal in size (0.7 cm in width) and shape. Parenchyma is homogenous. The prostatic urethra appears normal without evidence of dilation or obstruction.

The left kidney is normal in size (4.63 cm in length) with a normal shape, smooth peripheral margins and normal internal architecture. There is normal corticomedullary distinction. Several hyperechoic shadowing diverticular foci are observed. There is no evidence of pyelectasia, infarcts or hydronephrosis. Renal vasculature is normal.

The right kidney is normal size (4.76 cm in length); normal shape and architecture with smooth peripheral margins. There is a normal 1:3 cortex to medulla ratio with normal corticomedullary distinction. Several non-obstructive nephroliths are visualized. There is no evidence of pyelectasia, infarcts or hydronephrosis. Renal vasculature is normal.

Adrenal Glands

The left adrenal gland is normal size (0.46 cm at cranial pole) (0.54 cm at caudal pole) (1.91 cm in length); normal shape; homogenous parenchyma. The glandular echogenicity and detail are unremarkable. Capsule, cortex, and medullary definition are normal. The phrenicoabdominal vein and surrounding vasculature are normal.

The right adrenal gland is normal size (0.44 cm at cranial pole) (0.48 cm at caudal pole) (2.27 cm in length); normal shape; homogenous parenchyma. The glandular echogenicity and detail are unremarkable. Capsule, cortex, and medullary definition are normal. The phrenicoabdominal vein and surrounding vasculature are normal.

Spleen

The spleen is normal in size (1.19 cm in width at the level of the hilus) with a normal capsular contour. The parenchyma is subtly mottled in appearance. No focal lesions are observed. Splenic vasculature is normal.

Liver

The liver is subjectively prominent in size with slightly irregular peripheral contours. A >6 cm isoechoic



PATIENT

Jager Hagerty

SPECIES

Canine

BREED

Frenchie

SEX

Male, neutered

AGE

11 Yrs.

WEIGHT

31 lbs.

INTERPRETED BY

Andrea Nicastro, DVM,
Diplomate ACVIM
(Small Animal Internal
Medicine)

**IMAGING
PERFORMED BY**

Chaley Hunt, LVT

HOSPITAL NAME

Columbia AC

REFERRING VET

Dr. Michelle Engel

INVOICE

12773

DATE

1/4/22

to slightly heterogeneous mass is observed deep mid to right liver, adjacent to the diaphragm. The mass causes capsular expansion. The remaining parenchyma is homogeneous in appearance. Vascular and biliary tracts are of normal volume with no evidence of congestion. The gallbladder is of normal contours and contains some dependent echogenic debris. The wall is normal in thickness. No choleliths are observed. The cystic and common bile ducts are normal.

Gastrointestinal

The stomach and intestine are free of stasis and exhibit normal peristaltic activity. The gastric lumen is not distended. The gastric wall and pylorus are normal in thickness with a normal layering pattern. The pyloric outflow tract is patent. The small intestinal lumen is not dilated. The small intestinal wall thickness is normal with a normal layering pattern and appropriate mural detail. Discreet masses are not identified. The colonic wall is normal. No obstructive disease is noted.

Pancreas

The region of the pancreas is isoechoic relative to surrounding omental fat. No obvious parenchymal abnormalities are observed. There is no evidence of regional inflammation or effusion.

Free Abdomen

There is no evidence of free fluid. The abdominal lymph nodes are normal/not visible.

ULTRASONOGRAPHIC FINDINGS

Primary Findings:

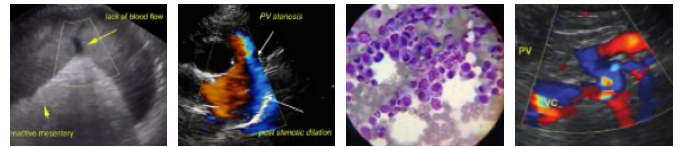
- Deep mid to right hepatic mass. Neoplasia (i.e., adenoma, adenocarcinoma) is suspected with a lower possibility of benign pathology.

Secondary Findings:

- The splenic parenchymal changes could be consistent with lymphoid hyperplasia, extramedullary hematopoiesis or less likely, infiltrative neoplasia.
- Right non-obstructive nephrolithiasis and left renal dystrophic mineralization.

INTERPRETATION OF THE FINDINGS & FURTHER RECOMMENDATIONS

- Three-view thoracic radiographs are recommended to assess for pulmonary metastases.
- If an aggressive approach is desired, consider hepatic mass removal with submission for histopathology. If surgery is to be pursued, referral to a board-certified surgeon is recommended due to the potential for perioperative complications. An abdominal CT scan would be useful in pre-surgical planning.



PATIENT

Jager Hagerty

- If a more conservative approach is desired, a fine needle aspirate of the hepatic mass can be considered (if clotting status is appropriate). a 25-gauge needle should be used. It should be noted, however, that cytology results from primary hepatic tumors are often inconclusive.

SPECIES

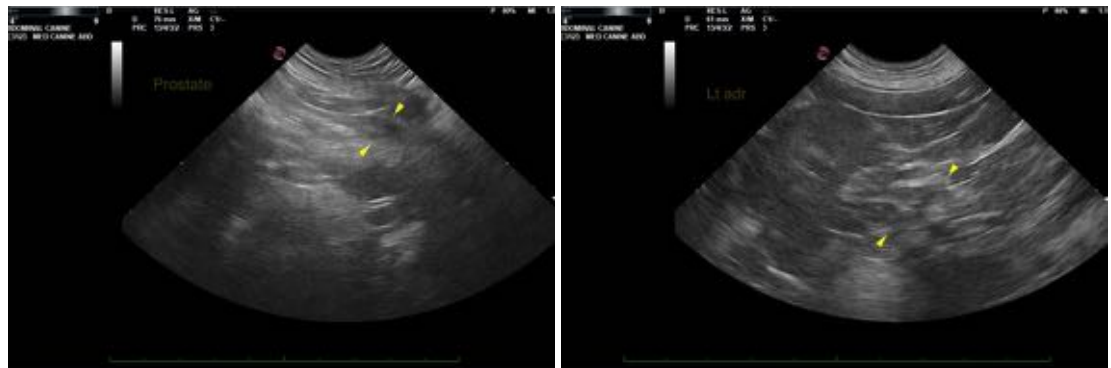Canine

BREED

Frenchie

SEX

Male, neutered

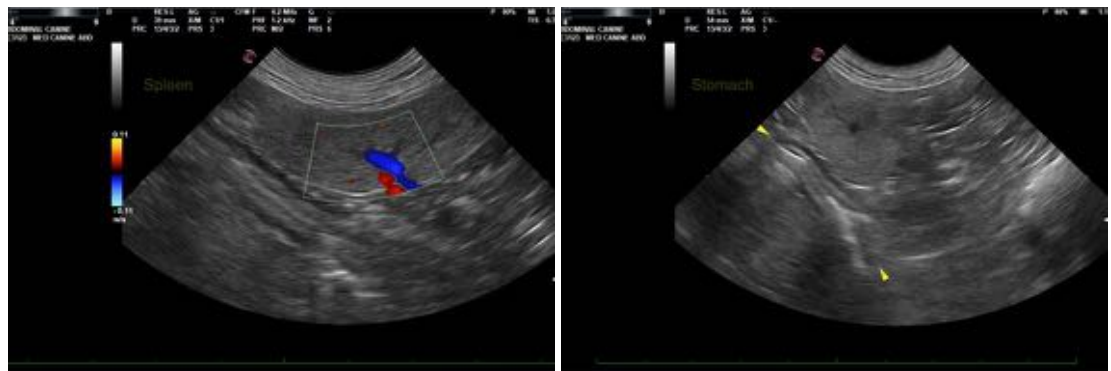

AGE

11 Yrs.

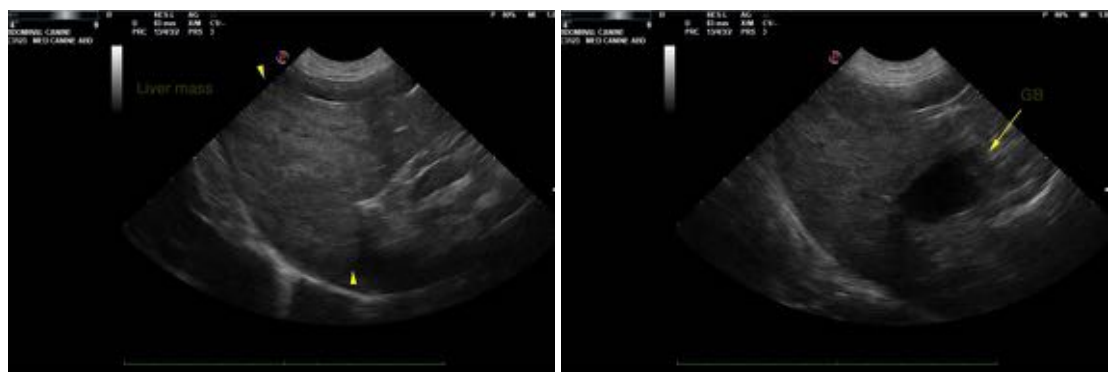WEIGHT

31 lbs.



INTERPRETED BY

Andrea Nicastro, DVM,
Diplomate ACVIM
(Small Animal Internal
Medicine)



IMAGING PERFORMED BY

Chaley Hunt, LVT

HOSPITAL NAME

Columbia AC

REFERRING VET

Dr. Michelle Engel

INVOICE

12773

DATE

1/4/22



PATIENT

Jager Hagerty

SPECIES

Canine

BREED

Frenchie

SEX

Male, neutered

AGE

11 Yrs.

WEIGHT

31 lbs.

INTERPRETED BY

Andrea Nicastro, DVM,
Diplomate ACVIM
(*Small Animal Internal
Medicine*)

**IMAGING
PERFORMED BY**

Chaley Hunt, LVT

HOSPITAL NAME

Columbia AC

REFERRING VET

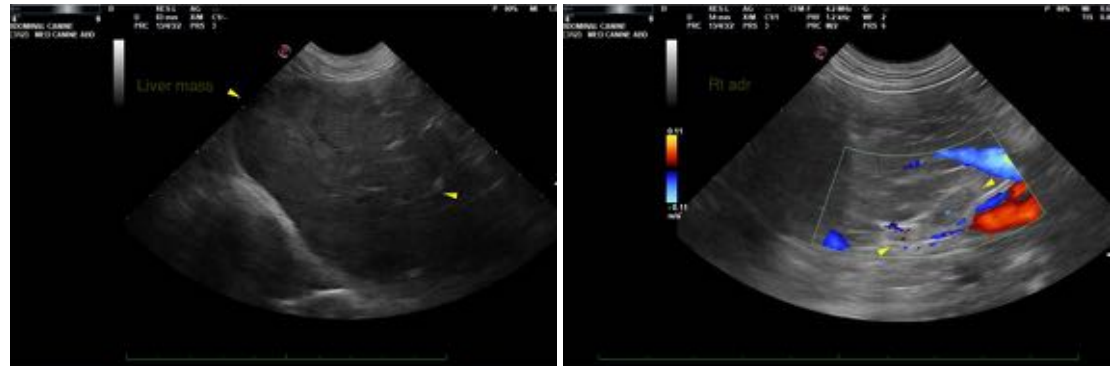
Dr. Michelle Engel

INVOICE

12773

DATE

1/4/22



The information and recommendations provided are based on the images presented by the referring veterinarian. No evaluation can be communicated regarding pathology that was not visible in the image/video clips provided.

Thank you for this referral. If the clinical or image interpretation does not parallel your findings or if I can be of any further assistance please contact me.

Andrea Nicastro, DVM, Diplomate ACVIM (*Small Animal Internal Medicine*)

Andrea.nicastro@sonopath.com