Charleston Mobile Veterinary Services
IN PARTNERSHIP WITH SONOPATH VETERINARY ULTRASOUND

SonoPath
FOSTERING THE ART OF VETERINARY MEDICINE™
www.charlestonmobile.net
info@charlestonmobile.net
800.403.5408

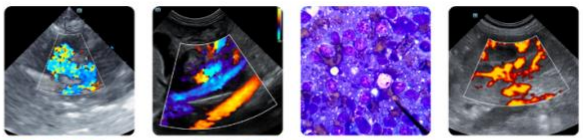

Clinical Sonography & Telecytology
Educational Teleconsultation Services™

PATIENT
Bondi Vandruff

SPECIES
Canine

BREED
French Bulldog

SEX
Male Neutered

AGE
1/6/2020

WEIGHT
23 lbs

INTERPRETED BY
Andrea Nicastro DVM
Diplomate ACVIM
(Sm Animal Internal Med)

IMAGING PERFORMED BY
Andrea Nicastro DVM
Diplomate ACVIM
(Sm Animal Internal Med)

HOSPITAL NAME
Waterway AH

REFERRING VET
Dr Eliza Roland

INVOICE
22476

DATE
1-30-26

PRESENTING CLINICAL SIGNS

Clinical Exam Findings: Blood in urine.
Abnormal lab-work values: Blood in urine; no other blood work is back yet. CBC chem and T4 unremarkable. USG 1.035. 3+ proteinuria. Pyuria, hematuria. 4dx negative.
Current Medications: None
Radiographic Findings: NSF

ULTRASONOGRAPHIC EXAMINATION OF THE ABDOMEN

Urinary System

The urinary bladder wall is normal in thickness. The mucosal surface is smooth. The bladder is moderately distended. Luminal contents are anechoic. No cystic calculi are observed. The region of the trigone and the proximal urethra, visible to a depth of 3 cm, are normal.

The prostate is normal in size (0.88 cm in width) and shape. Parenchyma is homogenous. The prostatic urethra appears normal without evidence of dilation or obstruction.

The left kidney is normal in size (4.92 cm in length) with a normal shape, architecture and smooth peripheral margins. There is a normal 1:3 cortex to medulla ratio with minimal loss of corticomedullary distinction. There is no evidence of pyelectasia, nephroliths, infarcts or hydroureter. Renal vasculature is normal.

The right kidney is normal in size (4.75 cm in length) with a normal shape, architecture and smooth peripheral margins. There is a normal 1:3 cortex to medulla ratio with minimal loss of corticomedullary distinction. There is no evidence of pyelectasia, nephroliths, infarcts or hydroureter. Renal vasculature is normal.

Adrenal Glands

The left adrenal gland is normal in size (0.49 cm at cranial pole) (0.60 cm at caudal pole) with a normal shape and homogenous parenchyma. The glandular echogenicity and detail are unremarkable. Capsule, cortex, and medullary definition are normal. The phrenicoabdominal vein and surrounding vasculature are normal.

The right adrenal gland is normal in size (0.62 cm at cranial pole) (0.51 cm at caudal pole) with a normal shape and homogenous parenchyma. The glandular echogenicity and detail are unremarkable. Capsule, cortex, and medullary definition are normal. The phrenicoabdominal vein and surrounding vasculature are normal.

Spleen

The spleen is normal in size (1.14 cm in width at the level of the hilus) with a normal capsular contour. There is appropriate echogenicity and echotexture. No focal lesions are observed. Splenic vasculature is normal.

Liver

The liver is subjectively normal in size with normal contours and structure. There is appropriate echogenicity and echotexture. No overt structural evidence of inflammatory, infiltrative, or regenerative pathology is evident. Vascular and biliary tracts are of normal volume with no evidence of congestion. The portal vein to caudal vena cava ratio is approximately 1: 1.

The gallbladder lumen is moderately distended. The wall is thin and smooth. A small amount of gravity-dependent, echogenic-to-mineralized debris/sand is observed within the lumen. The cystic and common bile ducts are normal/not seen.

Charleston Mobile Veterinary Services
IN PARTNERSHIP WITH SONOPATH VETERINARY ULTRASOUND

SonoPath
FOSTERING THE ART OF VETERINARY MEDICINE™
www.charlestonmobile.net
info@charlestonmobile.net
800.403.5408

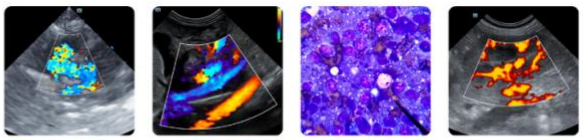

Clinical Sonography & Telecytology
Educational Teleconsultation Services™

PATIENT
Bondi Vandruff

SPECIES
Canine

BREED
French Bulldog

SEX
Male Neutered

AGE
1/6/2020

WEIGHT
23 lbs

INTERPRETED BY
Andrea Nicastro DVM
Diplomate ACVIM
(Sm Animal Internal Med)

IMAGING PERFORMED BY
Andrea Nicastro DVM
Diplomate ACVIM
(Sm Animal Internal Med)

HOSPITAL NAME
Waterway AH

REFERRING VET
Dr Eliza Roland

INVOICE
22476

DATE
1-30-26

Gastrointestinal
The gastric lumen is mildly-to-moderately-distended with ingesta. The gastric wall and pylorus are normal in thickness with a normal layering pattern. The pyloric outflow tract is patent. The small intestinal lumen is not dilated. The small intestinal wall is normal in thickness with a normal layering pattern and appropriate mural detail. Discreet masses are not identified. The colonic wall is normal. The colonic lumen contains granular-appearing fecal material. There is no obvious evidence of an obstructive pattern.

Pancreas
The region of the pancreas is isoechoic relative to surrounding omental fat. No obvious parenchymal abnormalities are observed. There is no evidence of regional inflammation or effusion.

Lymph Nodes
A 1.72 x 0.45 cm medial iliac lymph node is visualized. One-to-two prominent mesenteric lymph nodes are also seen (one measuring 1.65 x 0.44 cm).

Free Abdomen
There is no obvious evidence of free fluid.

Other
A brief echocardiogram reveals no obvious evidence of right atrial or auricular mass. There is no obvious evidence of pericardial effusion.

ULTRASONOGRAPHIC FINDINGS

- Gallbladder debris/sand, non-mucocele
- The presence of ingesta in the gastric lumen despite fasting is suggestive of delayed gastric emptying.
- The prominent abdominal lymph nodes are most consistent with reactive lymphadenitis or lymphoid hyperplasia. Neoplastic infiltration is considered less likely.

*An obvious cause for the patient's hematuria is not definitively identified in this study. However, urinalysis findings are suggestive of a urinary tract infection.

INTERPRETATION OF THE FINDINGS & FURTHER RECOMMENDATIONS

A urine culture and sensitivity is recommended (if not already performed). While awaiting test results, broad-spectrum antibiotic therapy should be initiated. Also consider a lateral caudal abdominal/pelvic radiograph to assess for distal urethral calculi.

Charleston Mobile Veterinary Services
IN PARTNERSHIP WITH SONOPATH VETERINARY ULTRASOUND

SonoPath
FOSTERING THE ART OF VETERINARY MEDICINE™
www.charlestonmobile.net
info@charlestonmobile.net
800.403.5408

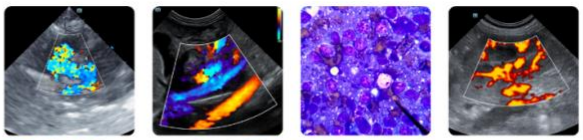

Clinical Sonography & Telecytology
Educational Teleconsultation Services™

PATIENT

Bondi Vandruff

SPECIES

Canine

BREED

French Bulldog

SEX

Male Neutered

AGE

1/6/2020

WEIGHT

23 lbs

INTERPRETED BY

Andrea Nicastro DVM
Diplomate ACVIM
(Sm Animal Internal Med)

IMAGING PERFORMED BY

Andrea Nicastro DVM
Diplomate ACVIM
(Sm Animal Internal Med)

HOSPITAL NAME

Waterway AH

REFERRING VET

Dr Eliza Roland

INVOICE

22476

DATE

1-30-26

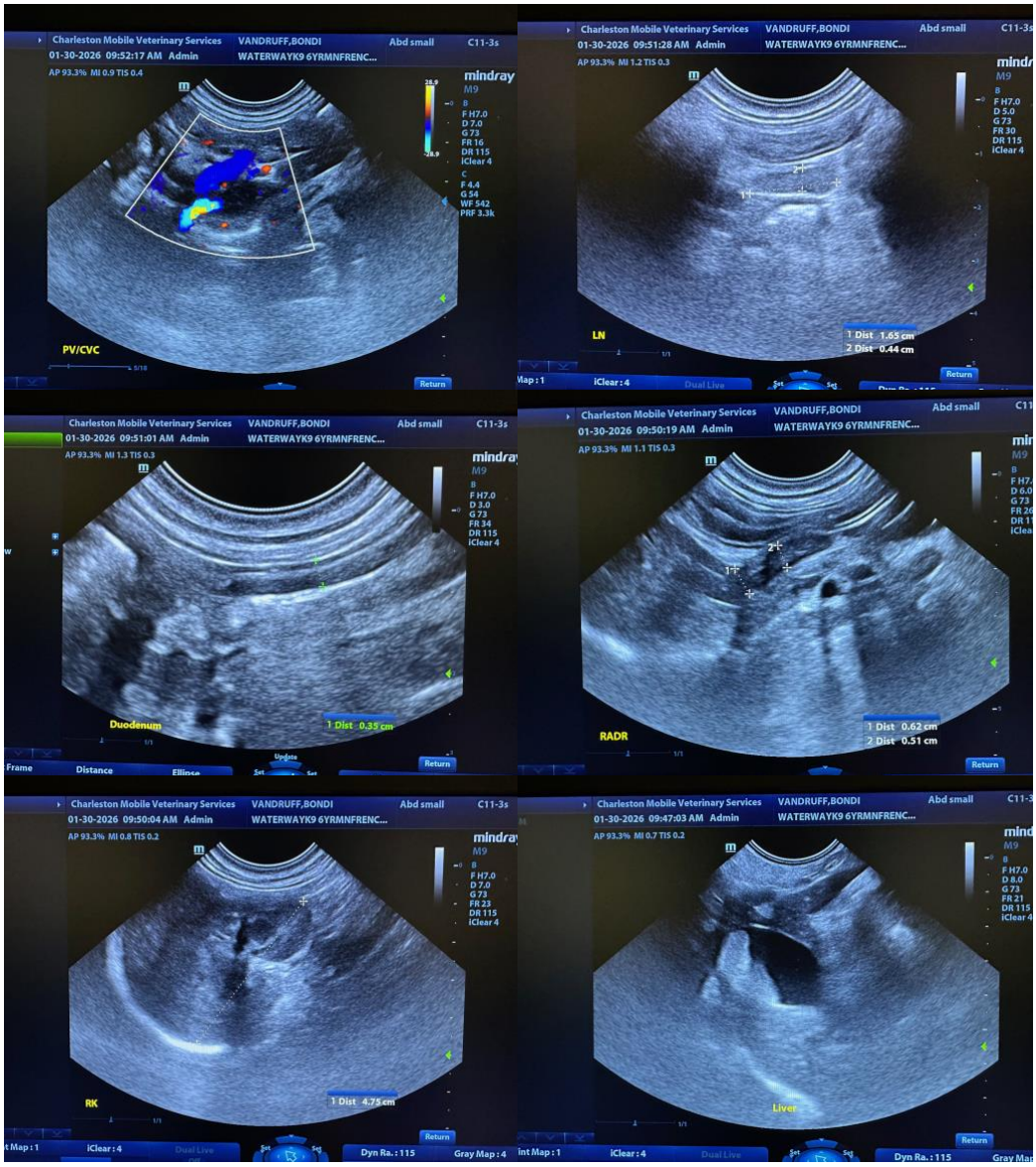

Charleston Mobile Veterinary Services
IN PARTNERSHIP WITH SONOPATH VETERINARY ULTRASOUND

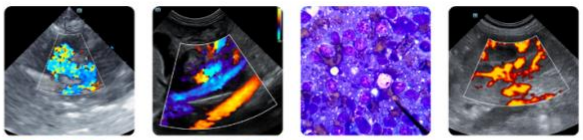

Clinical Sonography & Telecytology
Educational Teleconsultation Services™

SonoPath
FOSTERING THE ART OF VETERINARY MEDICINE™

www.charlestonmobile.net
info@charlestonmobile.net
800.403.5408

PATIENT

Bondi Vandruff

SPECIES

Canine

BREED

French Bulldog

SEX

Male Neutered

AGE

1/6/2020

WEIGHT

23 lbs

INTERPRETED BY

Andrea Nicastro DVM
Diplomate ACVIM
(Sm Animal Internal Med)

IMAGING PERFORMED BY

Andrea Nicastro DVM
Diplomate ACVIM
(Sm Animal Internal Med)

HOSPITAL NAME

Waterway AH

REFERRING VET

Dr Eliza Roland

INVOICE

22476

DATE

1-30-26

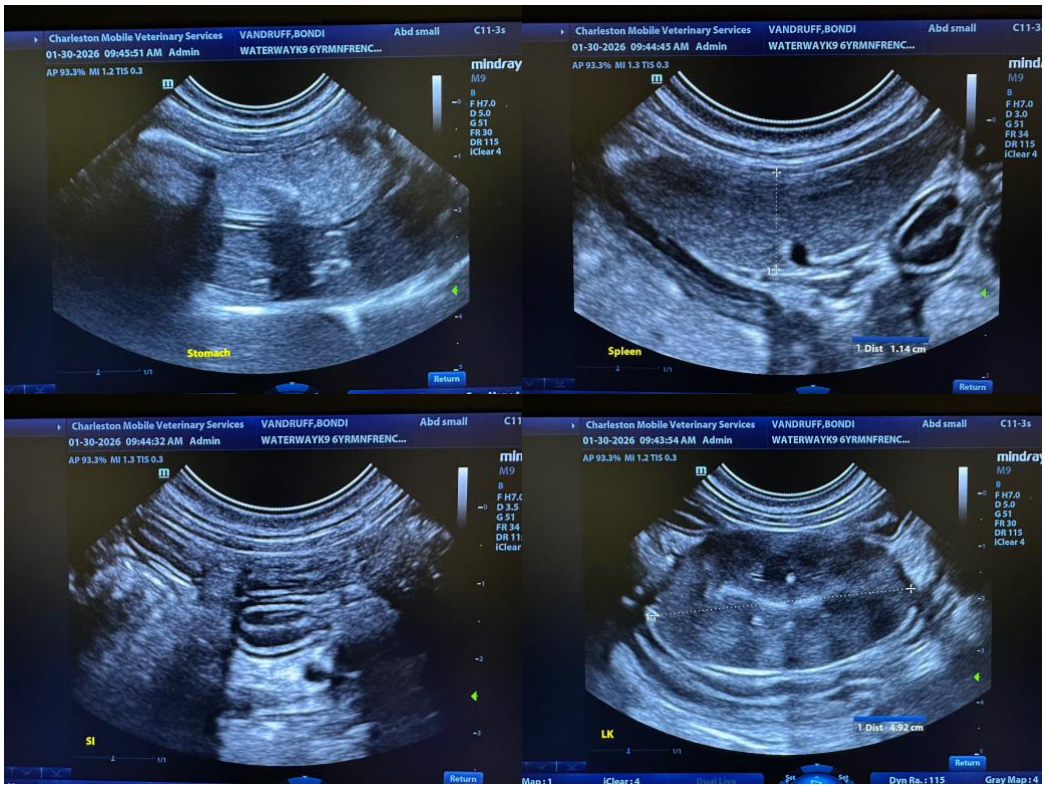

Charleston Mobile Veterinary Services
IN PARTNERSHIP WITH SONOPATH VETERINARY ULTRASOUND

SonoPath
FOSTERING THE ART OF VETERINARY MEDICINE™
www.charlestonmobile.net
info@charlestonmobile.net
800.403.5408

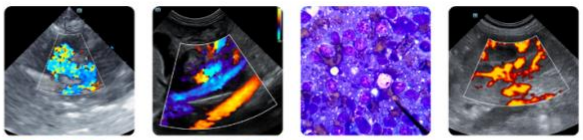

Clinical Sonography & Telecytology
Educational Teleconsultation Services™

PATIENT

Bondi Vandruff

SPECIES

Canine

BREED

French Bulldog

SEX

Male Neutered

AGE

1/6/2020

WEIGHT

23 lbs

INTERPRETED BY

Andrea Nicastro DVM
Diplomate ACVIM
(Sm Animal Internal Med)

IMAGING PERFORMED BY

Andrea Nicastro DVM
Diplomate ACVIM
(Sm Animal Internal Med)

HOSPITAL NAME

Waterway AH

REFERRING VET

Dr Eliza Roland

INVOICE

22476

DATE

1-30-26

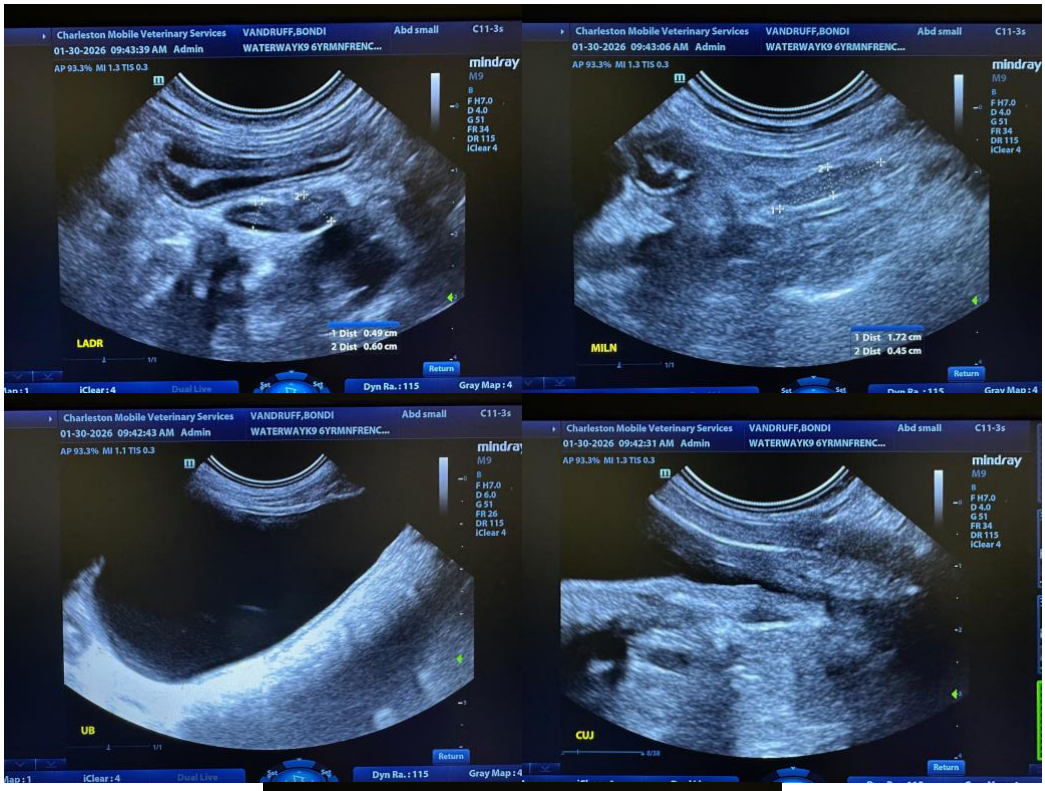

The information and recommendations provided are based on the images presented by the referring veterinarian/sonographer. No evaluation can be communicated regarding pathology that was not visible in the image/video clips provided.

Thank you for this referral. If the clinical or image interpretation does not parallel your findings or if I can be of any further assistance, please contact me.

Andrea Nicastro, MPH, DVM, Diplomate DACVIM (Small Animal Internal Medicine)
info@SonoPath.com