

PATIENT

Bella Fuller

PRESENTING CLINICAL SIGNS

History: Hyporexia and abdominal pain. Elevated liver values thrombocytopenia. Elevated white blood cell count.

SPECIES

Canine

ULTRASONOGRAPHIC EXAMINATION OF THE ABDOMEN

Urinary System

The urinary bladder wall is normal in thickness and the mucosal surface is smooth. The bladder lumen is moderately distended with anechoic urine. No masses, inflammatory changes or calculi are observed. Ureteral papillae and visualized portion of the proximal urethra, visible to a depth of 3-4 cm, are normal.

BREED

Mixed

SEX

Spayed Female

The left kidney is normal in size (6.66 cm in length) with a normal shape, architecture and smooth peripheral margins. There is a normal 1:3 cortex to medulla ratio with minimal to mild loss of corticomedullary distinction. There is no evidence of pyelectasia, nephroliths, infarcts or hydronephrosis. Renal vasculature is normal.

AGE

9 years

The right kidney is normal in size (7.13 cm in length) with a normal shape, architecture and smooth peripheral margins. There is a normal 1:3 cortex to medulla ratio with minimal to mild loss of corticomedullary distinction. There is no evidence of pyelectasia, nephroliths, infarcts or hydronephrosis. Renal vasculature is normal.

WEIGHT

NP

Adrenal Glands

The left adrenal gland is normal in size (0.64 cm at cranial pole) (0.45 cm at caudal pole) with a normal shape and homogenous parenchyma. The glandular echogenicity and detail are unremarkable. Capsule, cortex, and medullary definition are normal. The phrenicoabdominal vein and surrounding vasculature are normal.

INTERPRETED BY

Andrea Nicastro, DVM,
Diplomate ACVIM (*Small
Animal Internal Medicine*)

The right adrenal gland is normal in size (1.15 cm at cranial pole) (0.65 cm at caudal pole) with a normal shape and homogenous parenchyma. The glandular echogenicity and detail are unremarkable. Capsule, cortex, and medullary definition are normal. The phrenicoabdominal vein and surrounding vasculature are normal.

**IMAGING
PERFORMED BY**

Andrea Nicastro, DVM,
Diplomate ACVIM (*Small
Animal Internal Medicine*)

Spleen

The spleen is normal in size (2.29 cm in width at the level of the hilus) with a normal capsular contour. There is appropriate echogenicity and echotexture. No focal lesions are observed. Splenic vasculature is normal.

HOSPITAL NAME

Flowertown AH

Liver

The liver is normal to slightly prominent in size with normal curvilinear peripheral contours. The parenchyma is isoechoic relative to the spleen and diffusely homogeneous in appearance. No distinct focal lesions are observed. Vascular and biliary tracts are of normal volume with no evidence of congestion.

REFERRING VET

Dr. Hawk

The gall bladder lumen is moderately distended. The wall is thin and smooth. A small scant amount of aggregated, echogenic, partially dependent debris/sludge is observed within the lumen. The cystic and common bile ducts are normal/not seen.

Gastrointestinal

INVOICE

12118

The stomach and intestine are free of stasis and exhibit normal peristaltic activity. The gastric lumen is not distended. The gastric wall and pylorus are normal in thickness with a normal layering pattern. The pyloric outflow tract is patent. The small intestinal lumen is not dilated. The small intestinal wall thickness is normal with a normal layering pattern and appropriate mural detail. Discreet masses are not identified. The colonic wall is normal. There is no evidence of an obstructive pattern.

DATE

1.30.23

Pancreas

The region of the pancreas is isoechoic relative to surrounding omental fat. No obvious parenchymal abnormalities are observed. There is no evidence of regional inflammation or effusion.

Free Abdomen

The peritoneal cavity is normal. There is no evidence of inflammation or effusion. The abdominal lymph nodes are normal/not visible.

Other

A brief echocardiogram reveals no evidence of pericardial effusion or obvious right atrial/auricular mass.

ULTRASONOGRAPHIC FINDINGS

Primary Findings

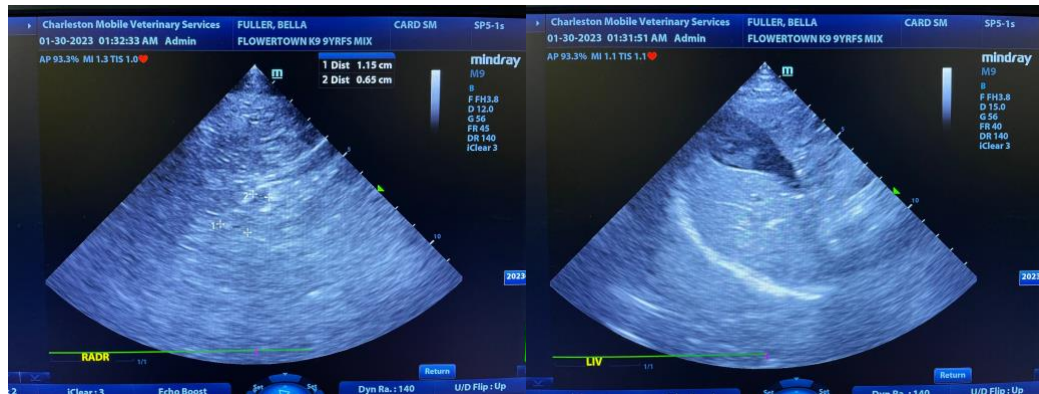- Suspected benign diffuse hepatopathy. Vacuolar hepatopathy (i.e., idiopathic/endocrine) is the top differential.

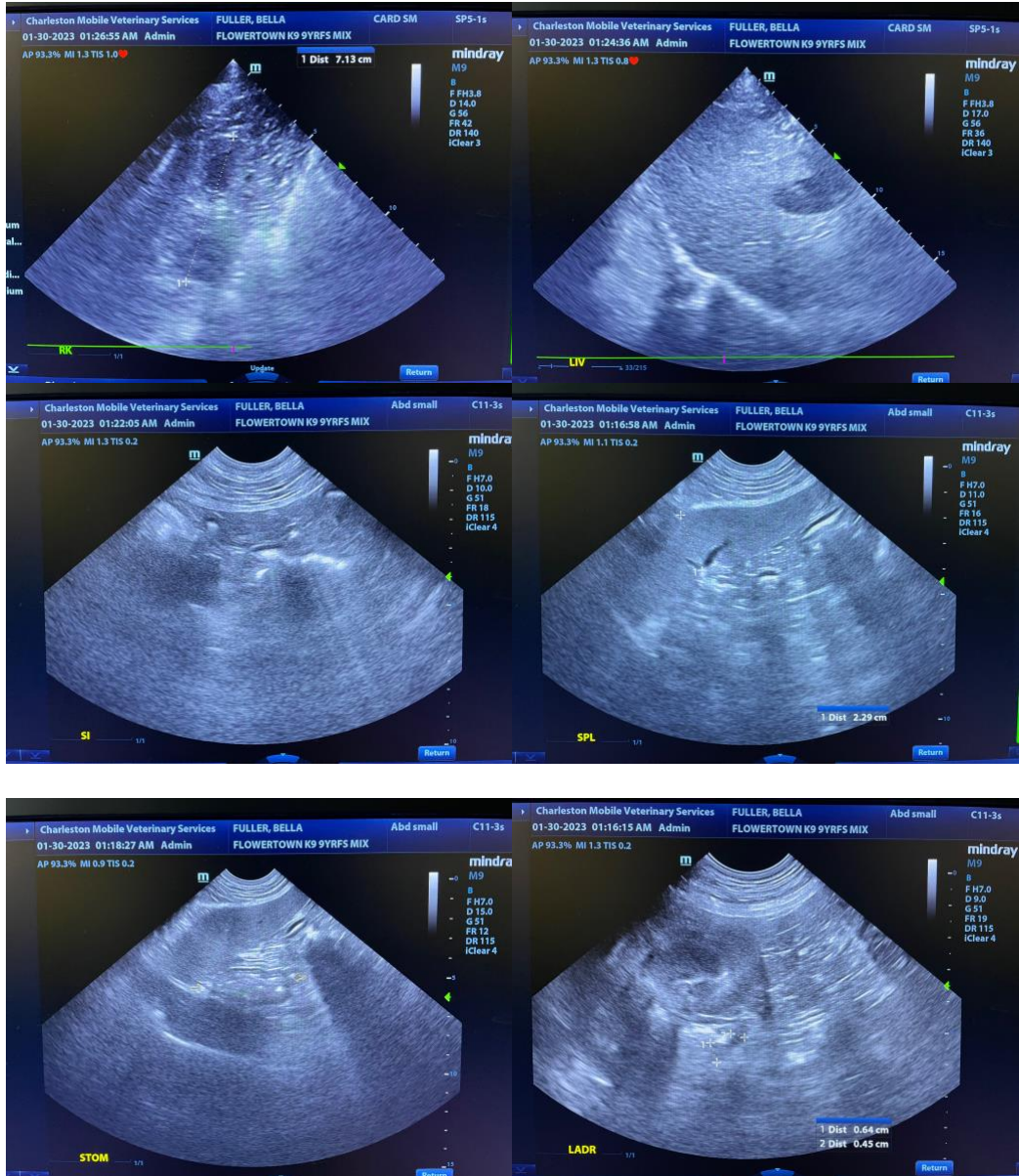
Secondary Findings

- Minor age-related chronic renal changes

INTERPRETATION OF THE FINDINGS & FURTHER RECOMMENDATIONS

- Serial monitoring (i.e, every 3-4 months) of the patient's liver values is recommended. If values continue to increase, a repeat abdomen ultrasound +/- a more advanced hepatic work-up (i.e., tissue sampling) may be warranted.





270

The information and recommendations provided are based on the images presented by the referring veterinarian/sonographer. No evaluation can be communicated regarding pathology that was not visible in the image/video clips provided.

Thank you for this referral. If the clinical or image interpretation does not parallel your findings or if I can be of any further assistance, please contact me.

Andrea Nicastro, MPH, DVM, Diplomate DACVIM (Small Animal Internal Medicine)
info@SonoPath.com

