



PATIENT

Jack Moro

SPECIES

Feline

BREED

DSH

SEX

Male Neutered

AGE

12/26/2015

WEIGHT

7.48

INTERPRETED BY

Andrea Nicastrò DVM
Diplomate ACVIM
(Sm Animal Internal Med)

**IMAGING
PERFORMED BY**

Andrea Nicastrò DVM
Diplomate ACVIM
(Sm Animal Internal Med)

HOSPITAL NAME

BluePearl MP ER

REFERRING VET

Dr Alexis Starr

INVOICE

22368

DATE

1-3-2026

PRESENTING CLINICAL SIGNS

Clinical Exam Findings: 12/26 Jack, a 10-year-old neutered male DSH presented to the ER for vomiting and straining in the litterbox. Jack has historically been vomiting about once a month or so and since the 22nd, he has vomited 4 times. He is bringing up undigested food, mucus and watery bile. His owner also stated that he has been straining in the litterbox over the past 2 weeks or so. She believes he's straining to defecate, but she is seeing normal stools and normal amounts of water. He will sometimes lay in front of the litterbox afterwards and the owner sees some abdominal contractions as if he's uncomfortable. He's not on any medications other than Advantage, but he does get Gabapentin prior to vet visit (has not had any today).

Diet: Weight Control Royal Canin

Indoor only cat. Normal thirst and appetite, no coughing or sneezing. UTD on vaccines.

12/29 Jack 10yr MN DSH returning for not defecating.

P has been E/D, urinating normally and his attitude has been normal. The last BM he had was Saturday morning at 6:10am.

Lactulose 1ml Q8HR - last given at 4:10am this morning

Gabapentin - PRN - None given last night or this morning

1/3 Pt has been lethargic and not defecated since 12/31

Abnormal lab-work values: 12/26: ALP <10, UGH >1.050

Current Medications: Lactulose 10g/15ml 1ml PO Q8H, Gabapentin 100mg/ml 0.75ml PO Q8H

Radiographic Findings- 12/26 Findings:

Orthogonal abdominal radiographs dated December 26, 2025 are available for evaluation (4 images total). No prior studies are available for comparison.

- This patient has a large body habitus.
- Peritoneal and retroperitoneal serosal detail are within normal limits.
- The stomach contains a mild amount of gas.
- The small intestine is diffusely of a uniform diameter and contains mild amounts of fluid and gas.
- The colon contains a large amount of formed, mineral opaque feces.
- The urinary bladder is moderately distended with fluid.
- No overt abnormalities are noted in the visualized portions of the liver or spleen.
- Punctate mineral foci overlie the central portion of the left kidney. The right kidney is poorly seen due to superimposition.
- No abnormalities are noted in the imaged portion of the caudal thorax.
- Mild osteophytosis is seen at the acetabular rims bilaterally.

Assessment:

- The appearance of the colonic contents may be suggestive of constipation if corresponding clinical findings are present.
- Urinary bladder distension may be due to voluntary lack of recent voiding, however a physical obstruction or neurogenic urinary retention cannot be excluded, and this finding should be correlated clinically.
- Left renal diverticular mineralization/nephrolithiasis.
- Bilateral coxofemoral degenerative joint disease.
- Obesity.

Specialist: Dr. Nam Joo Baik, DACVR

Patient sedated with alfaxalone for this study.



PATIENT

Jack Moro

SPECIES

Feline

BREED

DSH

SEX

Male Neutered

AGE

12/26/2015

WEIGHT

7.48

INTERPRETED BY

Andrea Nicastro DVM
Diplomate ACVIM
(Sm Animal Internal Med)

**IMAGING
PERFORMED BY**

Andrea Nicastro DVM
Diplomate ACVIM
(Sm Animal Internal Med)

HOSPITAL NAME

BluePearl MP ER

REFERRING VET

Dr Alexis Starr

INVOICE

22368

DATE

1-3-2026

ULTRASONOGRAPHIC EXAMINATION OF THE ABDOMEN

Urinary System

The urinary bladder wall is normal in thickness. The mucosal surface is smooth. The bladder is moderately distended. A small amount of suspended echogenic debris is observed within the lumen. No cystic calculi are observed. The region of the trigone and the proximal urethra, visible to a depth of 2 cm, are normal.

The left kidney is normal in size (4.34 cm in length) with a normal shape, architecture and smooth peripheral margins. There is a normal 1:3 cortex to medulla ratio with minimal loss of corticomedullary distinction. There is no evidence of pyelectasia, nephroliths, infarcts or hydroureter. Renal vasculature is normal.

The right kidney is normal in size (4.20 cm in length) with a normal shape, architecture and smooth peripheral margins. There is a normal 1:3 cortex to medulla ratio with minimal loss of corticomedullary distinction. There is no evidence of pyelectasia, nephroliths, infarcts or hydroureter. Renal vasculature is normal.

Adrenal Glands

The left adrenal gland is normal- to slightly small-in-size (0.25 cm width) with smooth peripheral contours. Glandular echogenicity and detail are normal. The phrenicoabdominal vein and surrounding vasculature are normal.

The right adrenal gland is normal size (0.33 cm width). Normal shape and glandular echogenicity. The phrenicoabdominal vein and surrounding vasculature are normal.

Spleen

The spleen is prominent-in-size (1.21 cm in width at the level of the hilus) with smooth peripheral contours. There is appropriate echogenicity and echotexture. No focal lesions are observed. Splenic vasculature is normal.

Liver

The liver is subjectively normal in size with normal curvilinear peripheral contours. The parenchyma is isoechoic relative to the spleen and diffusely homogeneous in appearance. No distinct focal lesions are observed. Vascular and biliary tracts are of normal volume with no evidence of congestion. The portal vein to caudal vena cava ratio is approximately 1: 1.

The gallbladder lumen is moderately distended. The wall is thin and smooth. A scant amount of suspended echogenic debris is observed within the lumen. The cystic and common bile ducts are normal.

Gastrointestinal

The stomach and intestine are free of stasis and exhibit normal peristaltic activity. The gastric lumen is not distended. The gastric wall and pylorus are normal in thickness with a normal layering pattern. The pyloric outflow tract is patent. The small intestinal lumen is not dilated. The small intestinal wall is normal to mildly thickened (up to 0.29 cm). There is disruption in the normal 1:3 muscularis: mucosal ratio in most segments. Discreet masses are not identified. The ileocecal colic junction and colonic wall are normal. The colonic lumen contains some shadowing fecal material. There is no obvious evidence of an obstructive pattern.

Pancreas

The region of the pancreas is isoechoic relative to surrounding omental fat. No obvious parenchymal abnormalities are observed. There is no evidence of regional inflammation or effusion.

Lymph Nodes

The abdominal lymph nodes are normal/not visible.



PATIENT

Jack Moro

Free Abdomen

The peritoneal cavity is normal. There is no evidence of inflammation or effusion.

SPECIES

Feline

Other

A brief echocardiogram reveals no obvious evidence of pericardial or pleural effusion in the visible window.

ULTRASONOGRAPHIC FINDINGS

BREED

DSH

Primary Findings

The small intestinal wall changes could be consistent with inflammatory bowel disease or may be a normal variant for this older feline patient. Correlation with the patient's long-term clinical history is recommended.

SEX

Male Neutered

Secondary Findings

The mild splenomegaly is likely secondary to sedation. Other considerations include lymphoid hyperplasia, extramedullary hematopoiesis, splenitis, antigenic stimulation, or less likely, emerging neoplasia.

AGE

12/26/2015

*An obvious cause for the patient's constipation is not definitively identified in this study. Considerations include idiopathic megacolon, underlying metabolic issue, other.

WEIGHT

7.48

INTERPRETATION OF THE FINDINGS & FURTHER RECOMMENDATIONS

INTERPRETED BY

Andrea Nicastro DVM
 Diplomate ACVIM
 (Sm Animal Internal Med)

- Symptomatic treatment for constipation is recommended.
- If the patient has persistent vomiting or other GI signs, consider further gastrointestinal work-up (i.e., fecal evaluation for ova and Giardia, GI panel, limited antigen or hydrolyzed protein diet trial, +/- GI biopsies).
- Given the history of intermittent vomiting, also consider heartworm testing (i.e., antigen and antibody).

IMAGING

PERFORMED BY

Andrea Nicastro DVM
 Diplomate ACVIM
 (Sm Animal Internal Med)

HOSPITAL NAME

BluePearl MP ER

REFERRING VET

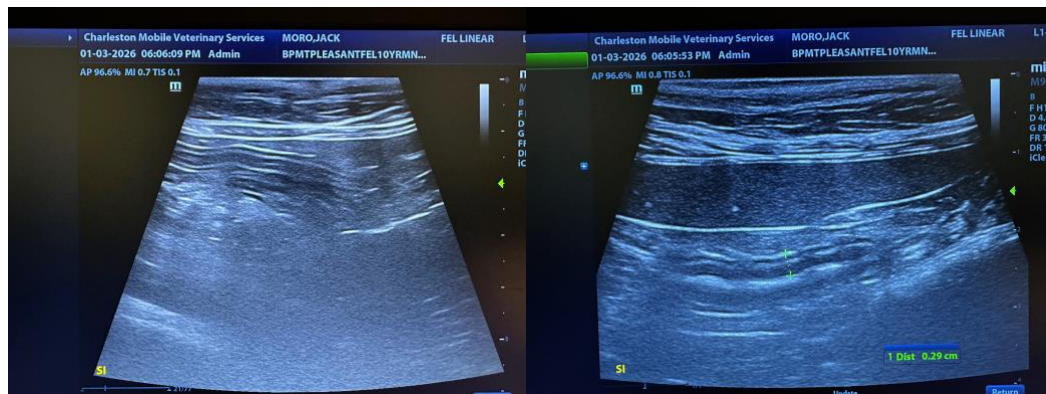
Dr Alexis Starr

INVOICE

22368

DATE

1-3-2026





PATIENT

Jack Moro

SPECIES

Feline

BREED

DSH

SEX

Male Neutered

AGE

12/26/2015

WEIGHT

7.48

INTERPRETED BY

Andrea Nicastro DVM
 Diplomate ACVIM
 (Sm Animal Internal Med)

IMAGING PERFORMED BY

Andrea Nicastro DVM
 Diplomate ACVIM
 (Sm Animal Internal Med)

HOSPITAL NAME

BluePearl MP ER

REFERRING VET

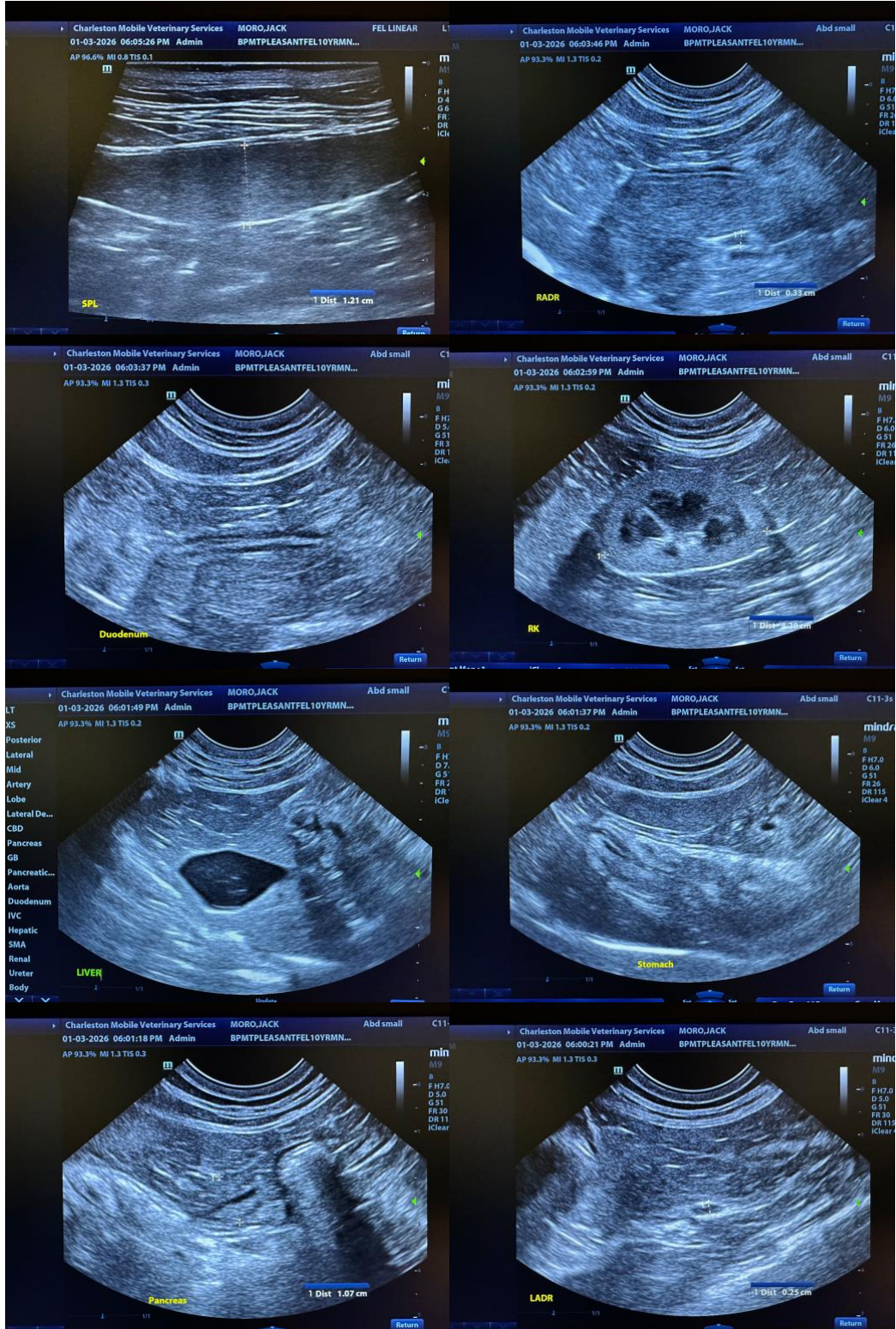
Dr Alexis Starr

INVOICE

22368

DATE

1-3-2026





PATIENT

Jack Moro

SPECIES

Feline

BREED

DSH

SEX

Male Neutered

AGE

12/26/2015

WEIGHT

7.48

INTERPRETED BY

Andrea Nicastro DVM
 Diplomate ACVIM
 (Sm Animal Internal Med)

IMAGING PERFORMED BY

Andrea Nicastro DVM
 Diplomate ACVIM
 (Sm Animal Internal Med)

HOSPITAL NAME

BluePearl MP ER

REFERRING VET

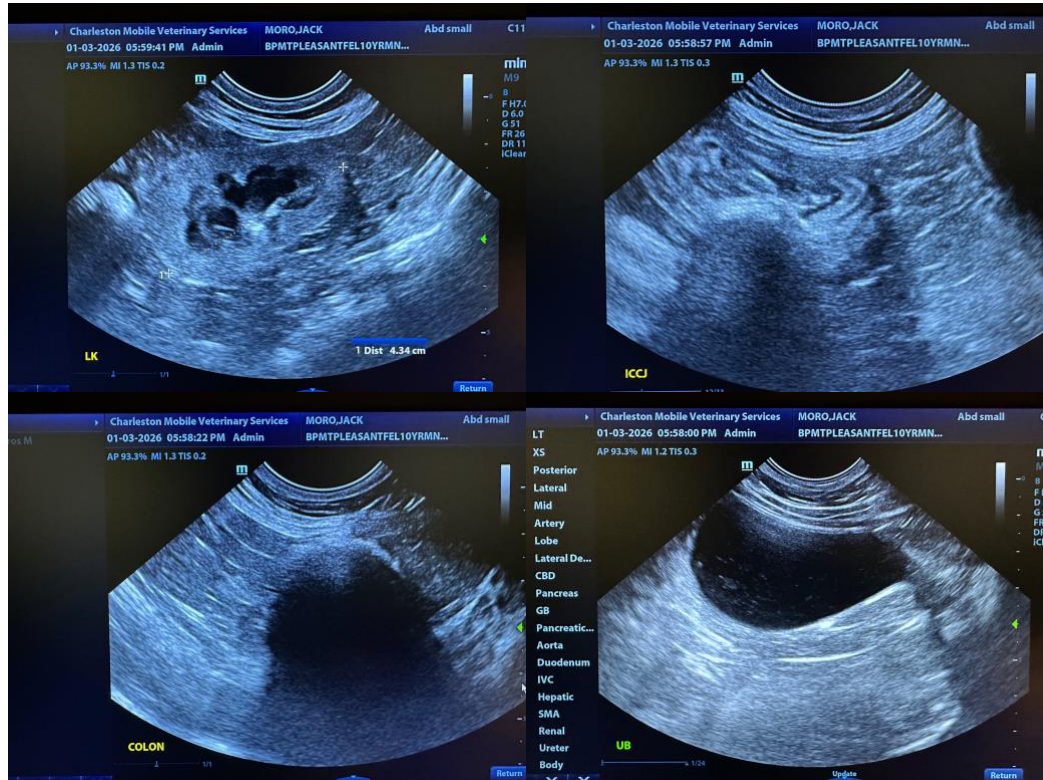
Dr Alexis Starr

INVOICE

22368

DATE

1-3-2026



The information and recommendations provided are based on the images presented by the referring veterinarian/sonographer. No evaluation can be communicated regarding pathology that was not visible in the image/video clips provided.

Thank you for this referral. If the clinical or image interpretation does not parallel your findings or if I can be of any further assistance, please contact me.

Andrea Nicastro, MPH, DVM, Diplomate DACVIM (Small Animal Internal Medicine)
info@SonoPath.com