



PATIENT

Asah Teredesai

SPECIES

Canine

BREED

German Shepherd Mix

SEX

Male Neutered

AGE

08/15/2015

WEIGHT

57.6

INTERPRETED BY

Andrea Nicastrò DVM
Diplomate ACVIM
(Sm Animal Internal Med)

**IMAGING
PERFORMED BY**

Andrea Nicastrò DVM
Diplomate ACVIM
(Sm Animal Internal Med)

HOSPITAL NAME

Salt Marsh AH

REFERRING VET

Dr Samantha Thompson

INVOICE

22467

DATE

1-29-26

PRESENTING CLINICAL SIGNS

Clinical Exam Findings: New finding of heart murmur. Pt currently on chemo for oral osteosarcoma.
Abnormal lab-work values: No labs performed here. I am in the process of tracking down previous records for pt. I will send them along as I receive them.
Current Medications: Carprovet. Trazadone and Gabapentin for veterinary visits.

Note: Images are labeled "Tereddesai", Asah

ULTRASONOGRAPHIC EXAMINATION OF THE ABDOMEN

Urinary System

The urinary bladder wall is normal in thickness. The mucosal surface is smooth. The bladder is mildly distended. Luminal contents are anechoic. No cystic calculi are observed. The region of the trigone and the proximal urethra, visible to a depth of 2 cm, are normal.

The prostate is normal in size (0.63 cm in width) and shape. Parenchyma is homogenous. The prostatic urethra appears normal without evidence of dilation or obstruction.

The left kidney is normal in size (6.75 cm in length) with a normal shape, architecture and smooth peripheral margins. There is a normal 1:3 cortex to medulla ratio with minimal-to-mild corticomedullary distinction. There is no evidence of pyelectasia, nephroliths, infarcts or hydroureter. Renal vasculature is normal.

The right kidney is normal in size (6.80 cm in length) with a normal shape, architecture and smooth peripheral margins. There is a normal 1:3 cortex to medulla ratio with minimal-to-mild corticomedullary distinction. There is no evidence of pyelectasia, nephroliths, infarcts or hydroureter. Renal vasculature is normal.

Adrenal Glands

The left adrenal gland is normal in size (0.67 cm at cranial pole) (0.60 cm at caudal pole) with a normal shape and homogenous parenchyma. The glandular echogenicity and detail are unremarkable. Capsule, cortex, and medullary definition are normal. The phrenicoabdominal vein and surrounding vasculature are normal.

The right adrenal gland is normal in size (0.85 cm at cranial pole) (0.71 cm at caudal pole) with a normal shape and homogenous parenchyma. The glandular echogenicity and detail are unremarkable. Capsule, cortex, and medullary definition are normal. The phrenicoabdominal vein and surrounding vasculature are normal.

Spleen

The spleen is subjectively normal-in-size with a normal capsular contour. There is appropriate echogenicity and echotexture. No focal lesions are observed. Splenic vasculature is normal.

Liver

The liver is subjectively normal in size with normal contours and structure. There is appropriate echogenicity and echotexture. No overt structural evidence of inflammatory, infiltrative, or regenerative pathology is evident. Vascular and biliary tracts are of normal volume with no evidence of congestion. The portal vein to caudal vena cava ratio is approximately 1: 1.

The gallbladder is of normal contours and contains some dependent echogenic debris. The wall is normal in thickness. No choleliths are observed. The cystic and common bile ducts are normal/not seen.

Gastrointestinal

The gastric lumen is mildly distended with ingesta. The gastric wall and pylorus are normal in thickness



PATIENT

Asah Teredesai

SPECIES

Canine

BREED

German Shepherd Mix

SEX

Male Neutered

AGE

08/15/2015

WEIGHT

57.6

INTERPRETED BY

Andrea Nicastrò DVM
 Diplomate ACVIM
 (Sm Animal Internal Med)

IMAGING PERFORMED BY

Andrea Nicastrò DVM
 Diplomate ACVIM
 (Sm Animal Internal Med)

HOSPITAL NAME

Salt Marsh AH

REFERRING VET

Dr Samantha Thompson

INVOICE

22467

DATE

1-29-26

with a normal layering pattern. The pyloric outflow tract is patent. The small intestinal lumen is not dilated. The small intestinal wall is normal in thickness with a normal layering pattern and appropriate mural detail. Discreet masses are not identified. The ileocecolic junction and colonic wall are normal. There is no evidence of an obstructive pattern.

Pancreas

The region of the pancreas is isoechoic relative to surrounding omental fat. No obvious parenchymal abnormalities are observed. There is no evidence of regional inflammation or effusion.

Lymph Nodes

The abdominal lymph nodes are normal/not visible.

Free Abdomen

The peritoneal cavity is normal. There is no evidence of inflammation or effusion.

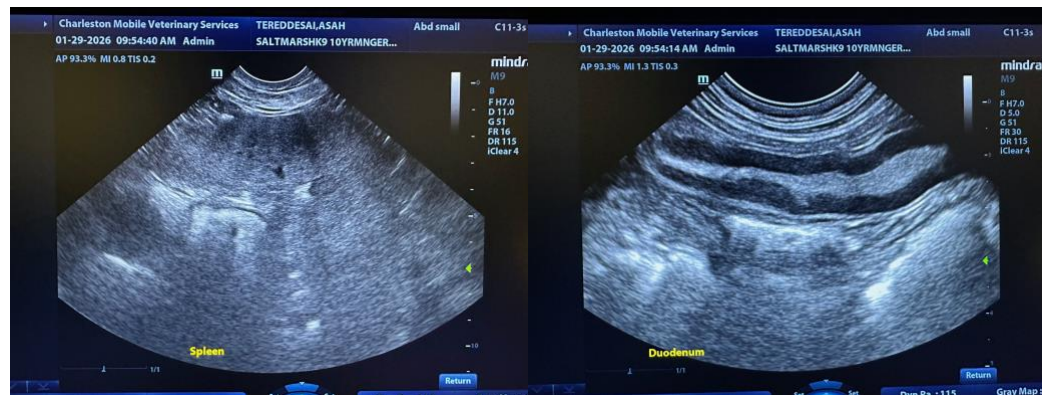
ULTRASONOGRAPHIC FINDINGS

- Minor bilateral age-related renal changes

*The abdomen is otherwise structurally unremarkable. There is no evidence of splenic nodules on today's study.

INTERPRETATION OF THE FINDINGS & FURTHER RECOMMENDATIONS

Further recommendations should be based on the echocardiogram report.





PATIENT

Asah Teredesai

SPECIES

Canine

BREED

German Shepherd Mix

SEX

Male Neutered

AGE

08/15/2015

WEIGHT

57.6

INTERPRETED BY

Andrea Nicastrò DVM
 Diplomate ACVIM
 (Sm Animal Internal Med)

IMAGING PERFORMED BY

Andrea Nicastrò DVM
 Diplomate ACVIM
 (Sm Animal Internal Med)

HOSPITAL NAME

Salt Marsh AH

REFERRING VET

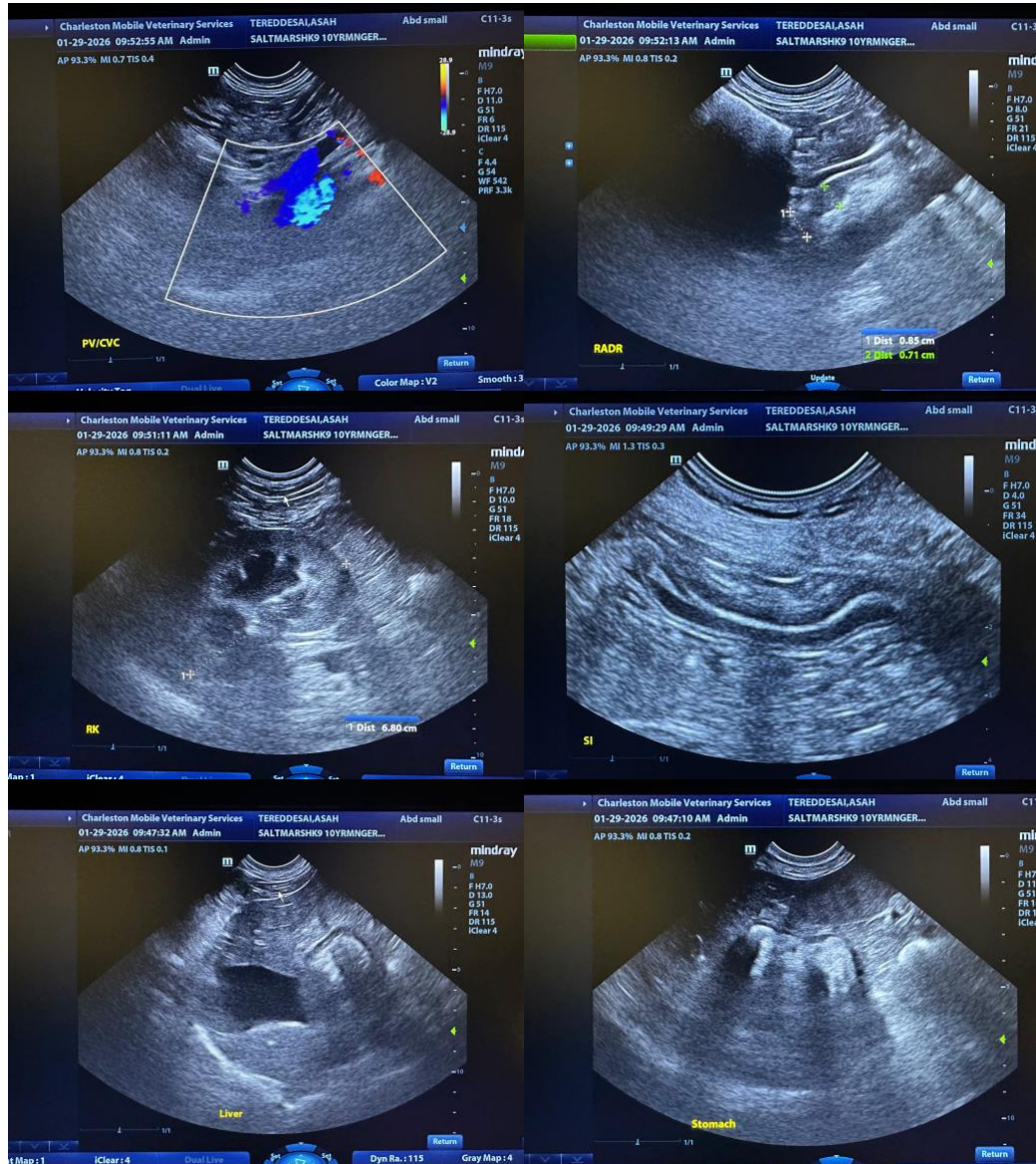
Dr Samantha Thompson

INVOICE

22467

DATE

1-29-26





PATIENT

Asah Teredesai

SPECIES

Canine

BREED

German Shepherd Mix

SEX

Male Neutered

AGE

08/15/2015

WEIGHT

57.6

INTERPRETED BY

Andrea Nicastro DVM
 Diplomate ACVIM
 (Sm Animal Internal Med)

IMAGING PERFORMED BY

Andrea Nicastro DVM
 Diplomate ACVIM
 (Sm Animal Internal Med)

HOSPITAL NAME

Salt Marsh AH

REFERRING VET

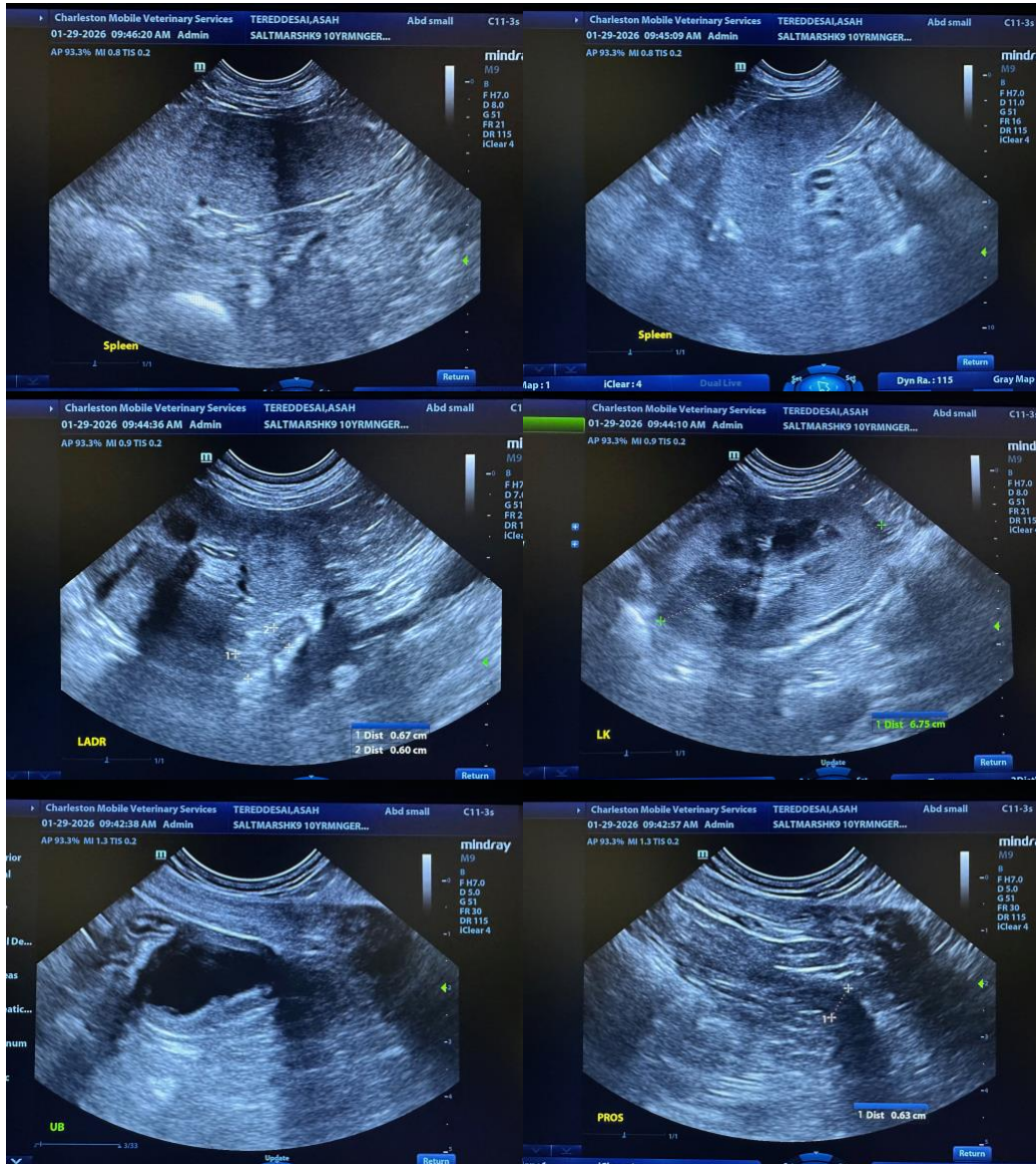
Dr Samantha Thompson

INVOICE

22467

DATE

1-29-26



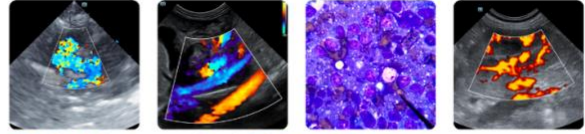
The information and recommendations provided are based on the images presented by the referring veterinarian/sonographer. No evaluation can be communicated regarding pathology that was not visible in the image/video clips provided.

Thank you for this referral. If the clinical or image interpretation does not parallel your findings or if I can be of any further assistance, please contact me.

Andrea Nicastro, MPH, DVM, Diplomate DACVIM (Small Animal Internal Medicine)
info@SonoPath.com



**Charleston Mobile
Veterinary Services**
IN PARTNERSHIP WITH SONOPATH VETERINARY ULTRASOUND



Clinical Sonography & Telecytology
Educational Teleconsultation Services™

SonoPath
FOSTERING THE ART OF VETERINARY MEDICINE™

www.charlestonmobile.net
info@charlestonmobile.net

800.403.5408

PATIENT

Asah Teredesai

SPECIES

Canine

BREED

German Shepherd Mix

SEX

Male Neutered

AGE

08/15/2015

WEIGHT

57.6

INTERPRETED BY

Andrea Nicastro DVM
Diplomate ACVIM
(Sm Animal Internal Med)

**IMAGING
PERFORMED BY**

Andrea Nicastro DVM
Diplomate ACVIM
(Sm Animal Internal Med)

HOSPITAL NAME

Salt Marsh AH

REFERRING VET

Dr Samantha Thompson

INVOICE

22467

DATE

1-29-26