


**DATE PRESENTING CLINICAL SIGNS**

1/27/26

**Patient History:** Presented 1/24/26 for diarrhea, lethargy. With Rover sitter during week and had diarrhea on Wednesday and Thursday. No BMs on Friday, no vomiting. Ate a small amount of food on Friday night but nothing on Saturday morning. On PE, lethargic, hepatomegaly, sunken abd immediately behind ribcage but vent abd distension, VERY painful upon abd palp and trying to bite, ~2inch mass R lat abd previously aspirated and found to be an inflammatory keratinized cyst. HX of Cushing's dz.

**PATIENT**

Remmy Wise

**SPECIES**

Canine

**BREED**

Mixed breed

**SEX**

35.6 lbs.

**AGE**

1/1/2017

**WEIGHT**

35.6 lbs.

**INTERPRETED BY**

Andrea Nicastro, DVM,  
 Diplomate ACVIM  
 (Small Animal Internal  
 Medicine)

**HOSPITAL NAME**

Chadwell AH

**REFERRING VET**

Dr. Mengers

**INVOICE**

13428

**Current Medications:** Cerenia (1mg/kg) - 1.6ml (10mg/ml) SQ (1/24/26) - cerenia (2mg/kg) - two 24mg tab PO q24h x 4 days. Start 1/25 afternoon - metronidazole (15mg/kg) - one 250mg tab PO q12h x 5 days (1/24/26) - proviable -1 cap over food q24h x 15 days (1/24/26) - vetoryl 5mg - 1 tab PO q24h

**Labwork Results:** Diagnostics attached, reported as: 1/10/26 - CBC/CHEM/T4, UA: ALT 171, ALP 1873 - UA, SpG 1.014, 3+ proteinuria, 2+ hematuria. PCV. 1/19/26 - ACTH Stim test: pre cortisol 2.27, post ACTH cortisol 5.03. 1/24/26 - PCV45%/TS 8.4 - \*2V abd rads - empty stomach and small intestines, gas throughout colon, intestines pushed caudally, large and irregular soft tissue opacity at level of liver or spleen, no overt skeletal abnormalities. BW on 1/24 revealed ALP of 1292, albumin 2.4, globulin 4.1

**Date of Previous IntraPet Ultrasound:** No previous.

**Sedation:** Not required to complete full diagnostic ultrasound.

**Stat Report:** STAT requested.

**Imaging Performed by:** Rachel Brillhart, RDMS.

**ULTRASONOGRAPHIC EXAMINATION OF THE ABDOMEN**
**Urinary System**

The urinary bladder wall is normal in thickness and the mucosal surface is smooth. The bladder is moderately distended. Luminal contents are anechoic. No cystic calculi are observed. The region of the trigone and the proximal urethra, visible to a depth of 3-4 cm, are normal.

The prostate is normal in size (0.95 cm in width) and shape. Parenchyma is homogenous. The prostatic urethra appears normal without evidence of dilation or obstruction.

The left kidney is normal size (6.94 cm in length); normal shape and architecture with smooth peripheral margins. The cortex is mildly thickened and there is moderate to severe loss of corticomedullary distinction. Pinpoint mineralized foci are observed throughout the kidney. A few small cortical cysts are seen. There is no evidence of pyelectasia, infarcts or hydronephrosis. Renal vasculature is normal.

The right kidney is normal in length (7.88 cm in length) with an irregular shape. A 6.9 cm septated cyst containing echogenic material is arising from the parenchyma. The cyst causes distortion of the normal renal architecture. In the remainder of the kidney, the cortex appears normal to mildly thickened. There is poor corticomedullary distinction. Mineralized foci are observed throughout the kidney. Renal vasculature appears normal.

**Adrenal Glands**

The left adrenal gland is enlarged (0.99 cm at cranial pole) (1.00 cm at caudal pole) with swollen peripheral contours. At the cranial pole, a 0.86 x 0.44 cm cystic area is visualized. At the caudal pole, a 0.74 x 0.66 cm hypoechoic nodule is seen. Mineralized foci are also visualized. There is loss of glandular detail. The phrenicoabdominal vein and surrounding vasculature appear normal.

The right adrenal gland is mildly enlarged (0.94 cm at cranial pole) (0.77 cm at caudal pole) with a normal shape and homogenous parenchyma. The glandular echogenicity and detail are unremarkable. Capsule, cortex, and medullary definition are normal. The phrenicoabdominal vein and surrounding vasculature are normal.

### ***Spleen***

The spleen is normal in size (1.02 cm in width at the level of the hilus) with a normal capsular contour. The parenchyma is subtly mottled in appearance. There is a questionable thrombus within a splenic vessel just distal to the hilus. Vasculature within the splenic parenchyma appears normal.

### ***Liver***

The liver is enlarged with irregular peripheral contours. A >11 cm heterogeneous, expansile, vascular mass is arising from the left lateral lobe. A 0.98 cm cyst is also seen on the left side. In addition, a 3.5 x 3.5 cm multi-septated, cystic mass is observed on the right side. The remaining parenchyma is isoechoic relative to the spleen and subtly heterogeneous in appearance. Vascular and biliary tracts are of normal volume with no evidence of congestion.

The gall bladder lumen is moderately distended. The wall is thin and smooth. A moderate amount of aggregated, echogenic to mineralized, partially dependent debris/sludge is observed within the lumen. The cystic and common bile ducts are normal/not seen.

### ***Gastrointestinal***

The gastric lumen is not distended. The gastric wall and pylorus are normal in thickness with a normal layering pattern. The pyloric outflow tract is patent. The small intestinal lumen is not dilated. The small intestinal wall is normal in thickness with a normal layering pattern and appropriate mural detail. Discreet masses are not identified. The colonic wall is normal. There is no evidence of an obstructive pattern.

### ***Pancreas***

The base and right limb of the pancreas are visible with normal curvilinear peripheral contours. The parenchyma is largely slightly hypoechoic relative to surrounding omental fat and slightly mottled in appearance. The pancreatic duct is visible but not overtly dilated. There is no evidence of peripancreatic inflammation or effusion.

### ***Lymph nodes***

2-3 prominent sublumbar lymph nodes are visualized, the largest measuring 1.92 x 1.08 cm.

### ***Free Abdomen***

The mesentery in the mid-abdominal region is hyperechoic. There is no obvious evidence of free fluid.

## **ULTRASONOGRAPHIC FINDINGS**

### **Primary Findings:**

- Large left hepatic mass. Neoplasia (i.e., adenoma, adenocarcinoma, sarcoma, round cell tumor) is suspected with a lower possibility of a benign process (i.e., large regenerative nodule, inflammatory focus, other). Smaller cystic hepatic lesions are also seen. The diffuse hepatic parenchymal changes are non-specific and could be secondary to regenerative nodular hyperplasia, vacuolar hepatopathy, age-related parenchymal remodeling or less likely, inflammatory disease, infiltrative neoplasia, hepatotoxicosis or other hepatopathy.
- Possible early splenic thrombus. The splenic parenchymal changes are most consistent with a benign process such as lymphoid hyperplasia, extramedullary hematopoiesis, splenitis or antigenic stimulation with a lower possibility of infiltrative neoplasia (i.e., lymphoma, mast cell neoplasia).
- The sublumbar lymphadenopathy could be consistent with lymphadenitis, lymphoid hyperplasia or emerging neoplasia.

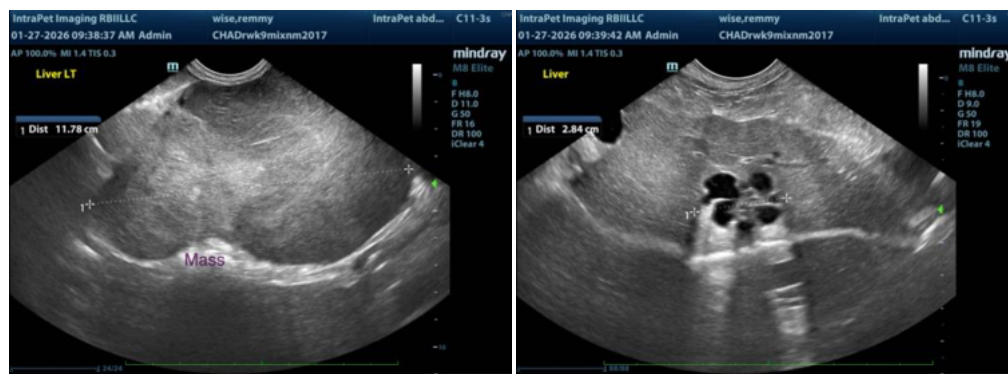- Mild peritonitis mid-abdomen.

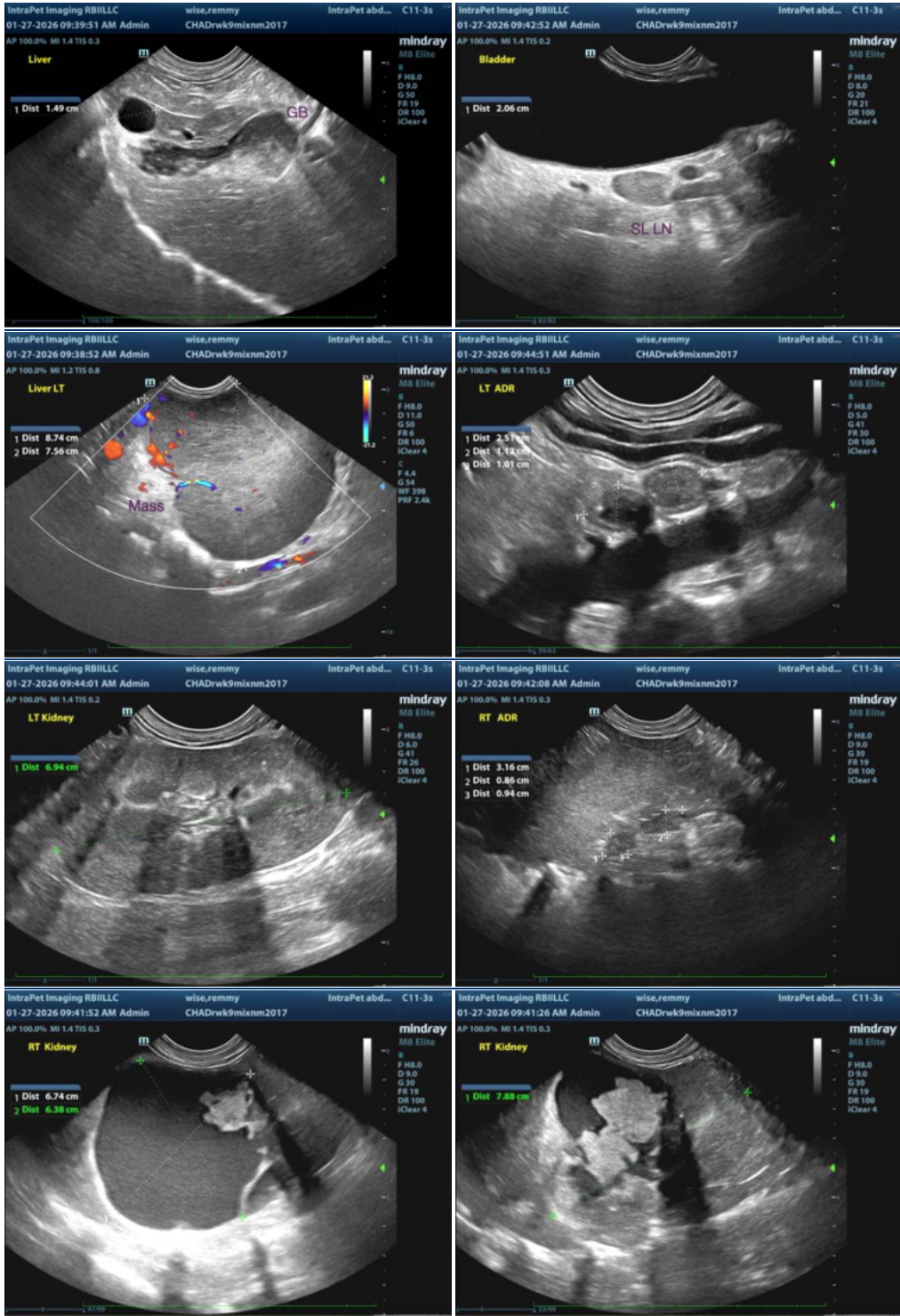
#### Secondary Findings:

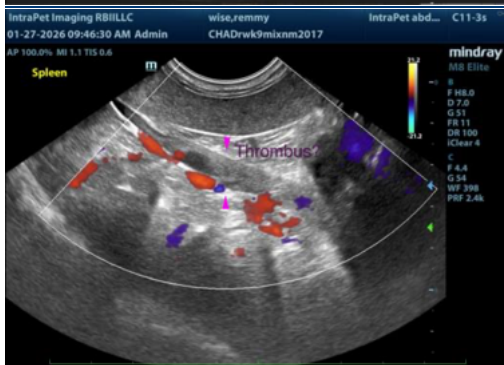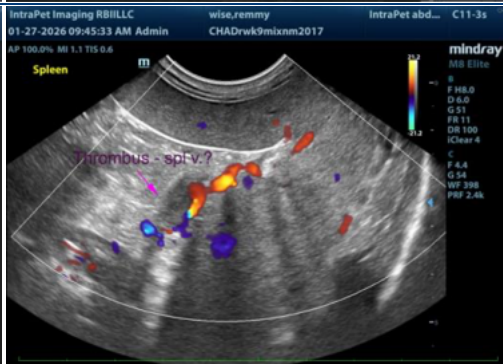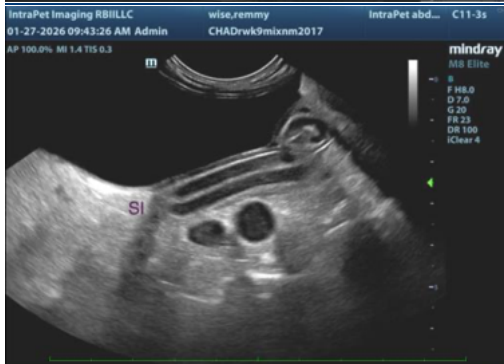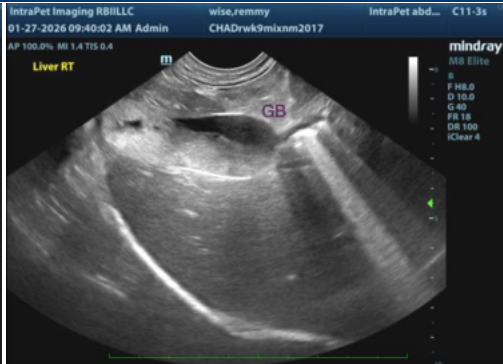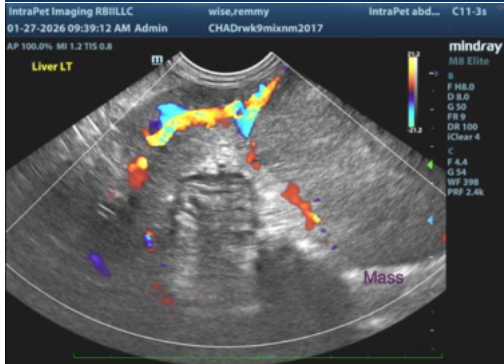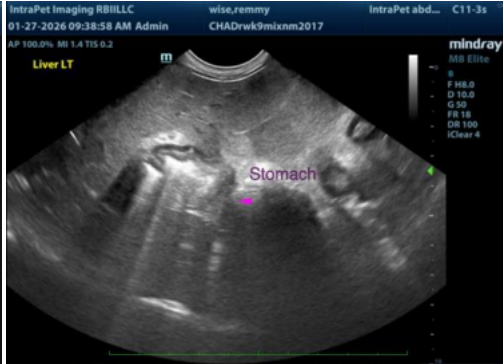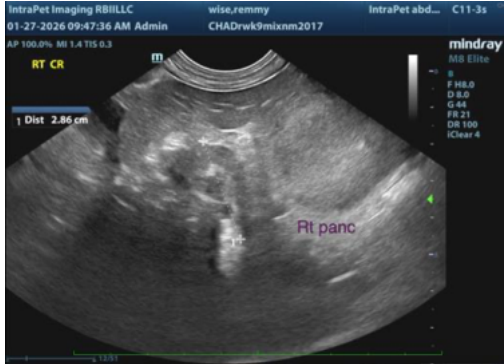- Bilateral nonspecific, age-related renal changes with non-obstructive nephrocalcinosis and a large right cystic structure.
- Bilateral adrenomegaly with a cystic nodule at the cranial pole and a hypochoic nodule at the caudal pole of the left adrenal gland.
- The pancreatic changes are most consistent with age-related parenchymal remodeling, potentially secondary to a prior inflammatory episode, early fibrosis or chronic pancreatitis.
- The gallbladder changes could be consistent with cholestasis, fasting or a developing mucocele.

#### INTERPRETATION OF THE FINDINGS & FURTHER RECOMMENDATIONS

- Regarding the hepatic mass, consider the following:
  1. Three-view thoracic radiographs are recommended to assess for pulmonary metastases.
  2. Fine needle aspiration (assuming normal clotting status). A 25-gauge needle should be used. It should be noted that it can be difficult to differentiate hepatic hyperplasia from adenoma from adenocarcinoma cytologically and histopathology may be necessary to get a definitive diagnosis. Ultimately, consultation with a board-certified surgeon may be warranted to discuss hepatic mass removal or debulking. An abdominal CT scan would be useful in pre-surgical planning.
- Regarding the possible splenic thrombus, a search for underlying causes of hypercoagulability is warranted along with close sonographic monitoring to assess progression.
- Consider testing for hyperadrenocorticism with a low-dose dexamethasone suppression test or ACTH stimulation test if clinical signs (i.e., PU/PD) develop in the future.
- Given the gall bladder changes, Ursodeoxycholic acid (Ursodiol) is recommended. Serial sonographic monitoring (e.g., every 6-8 weeks) of the gall bladder is recommended to assess for progression to a fully formed mucocele. If progression occurs, a cholecystectomy may be warranted.







**The information and recommendations provided are based on the images presented by the referring veterinarian/sonographer. No evaluation can be communicated regarding pathology that was not visible in the image/video clips provided.**

Thank you for this referral. If the clinical or image interpretation does not parallel your findings or if I can be of any further assistance please contact me.

Andrea Nicastro, MPH, DVM, Diplomate DACVIM (Small Animal Internal Medicine) [info@SonoPath.com](mailto:info@SonoPath.com)